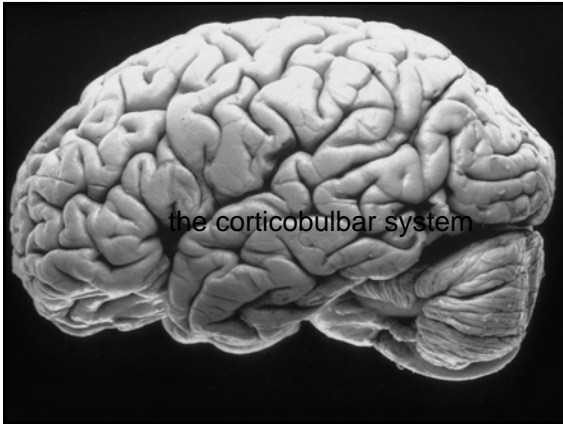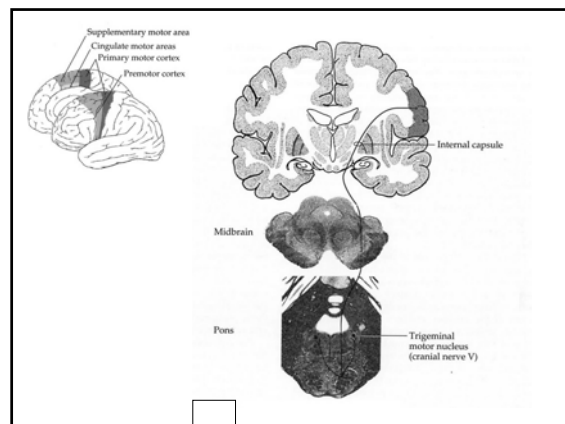
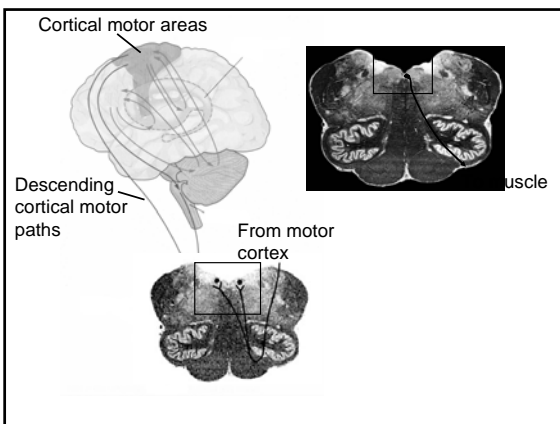
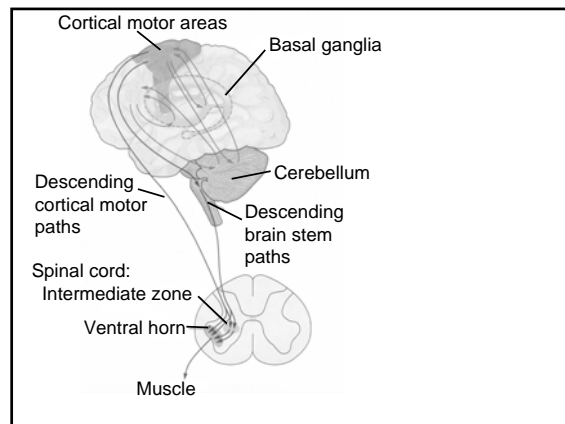





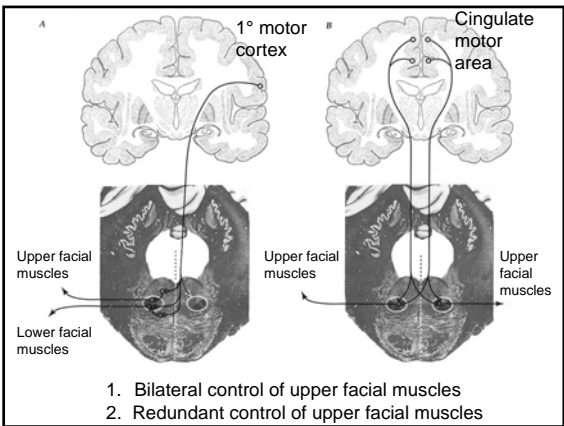
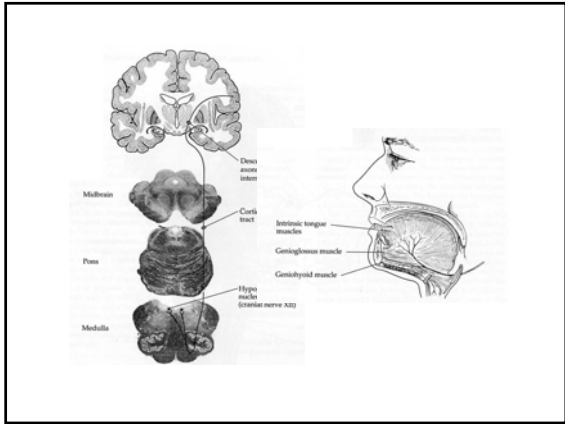
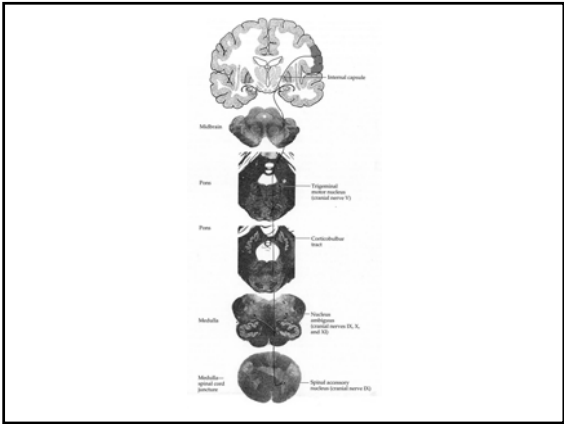
## Resources

- Neuroanatomy: Text and Atlas; Chapter 11 Introduction (Handout)
- [http://www.columbia.edu/itc/hs/medical/histology/course\\_online/](http://www.columbia.edu/itc/hs/medical/histology/course_online/)
  - Year 1: Neuroanatomy Atlas
  - Descending motor pathways--selected images (compare with powerpoint handout)

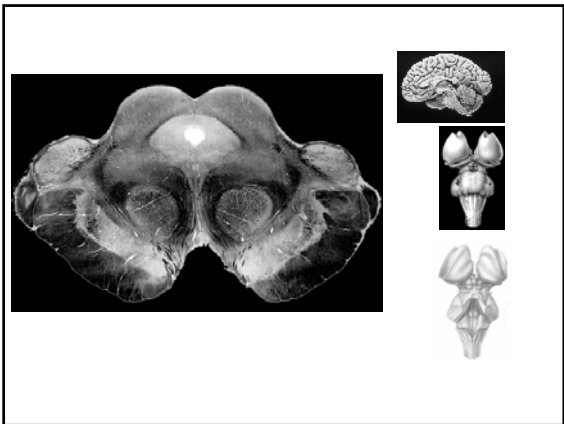
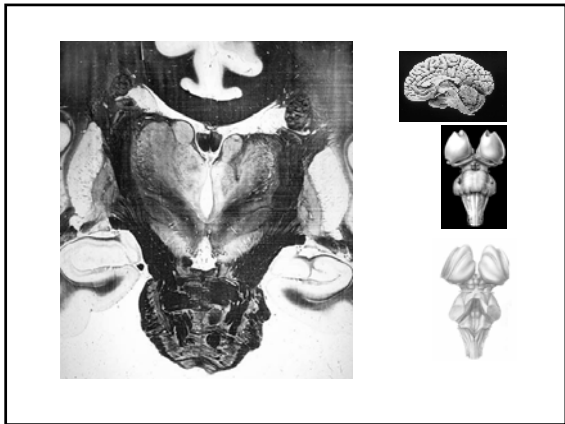
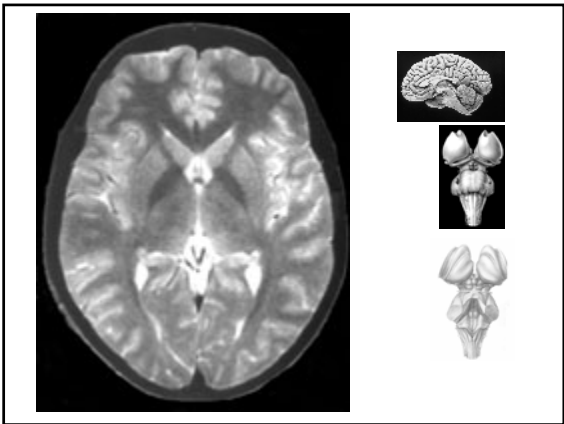
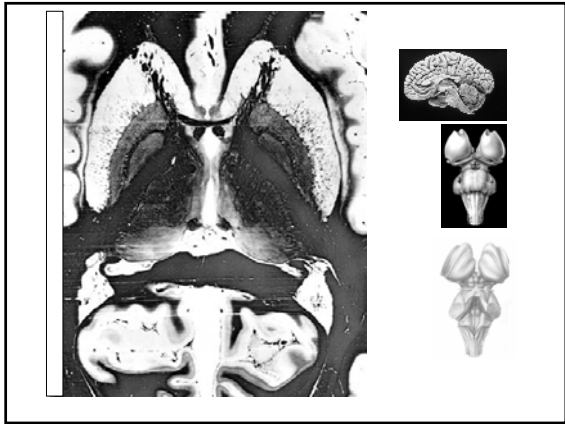
## Corticobulbar system

- Cortical motor systems:
  - Corticospinal
  - Corticobulbar
- Primarily bilateral control:
  - Jaw
  - Larynx, pharynx
  - Tongue
  - Upper facial muscles
- Contralateral control:
  - Lower facial muscles





Animation



Animation

Animation

