

CLINICAL PRACTICE

Acute Pericarditis

Richard A. Lange, M.D., and L. David Hillis, M.D.

This Journal feature begins with a case vignette highlighting a common clinical problem. Evidence supporting various strategies is then presented, followed by a review of formal guidelines, when they exist. The article ends with the authors' clinical recommendations.

A 35-year-old woman who is otherwise healthy has had constant retrosternal chest pain for two days. The pain becomes worse when she lies down and improves when she sits up and leans forward. On physical examination, the patient is afebrile and has a friction rub. The 12-lead electrocardiogram shows widespread ST-segment elevation and concomitant PR-segment depression. How should the patient be evaluated and treated?

THE CLINICAL PROBLEM

The fibrous pericardium surrounding the heart is composed of visceral and parietal layers separated by the pericardial cavity, which normally contains 15 to 50 ml of straw-colored fluid. Acute pericarditis may occur as an isolated entity or as the result of a systemic disease. The incidence of pericarditis in postmortem studies ranges from 1 percent to 6 percent, whereas it is diagnosed ante mortem in only 0.1 percent of hospitalized patients and in 5 percent of patients seen in emergency rooms with chest pain but without myocardial infarction.^{1,2} The possible sequelae of pericarditis include cardiac tamponade,^{3,4} recurrent pericarditis,^{5,6} and pericardial constriction.⁷⁻¹¹

From the Department of Internal Medicine, Cardiology Division, Johns Hopkins Medical Institutions, Baltimore (R.A.L.); and the University of Texas Southwestern Medical Center, Dallas (L.D.H.). Address reprint requests to Dr. Hillis at Rm. G5.232, University of Texas Southwestern Medical Center, 5323 Harry Hines Blvd., Dallas, TX 75390-9030, or at dhilli@parknet.pmh.org.

N Engl J Med 2004;351:2195-202.

Copyright © 2004 Massachusetts Medical Society.

STRATEGIES AND EVIDENCE

CAUSES

In 9 of 10 patients with acute pericarditis, the cause of the disease is either viral or unknown (idiopathic).^{3,4} In the remainder of patients, pericarditis occurs after a transmural myocardial infarction, in association with other infectious agents, in conjunction with a dissecting aortic aneurysm (in which blood leaks into the pericardial space), after blunt or sharp trauma to the chest, as a result of neoplastic invasion of the pericardium, after chest irradiation, in association with uremia, after cardiac or other thoracic surgery, in association with an inflammatory or autoimmune disorder, or as a result of taking certain pharmacologic agents (Table 1).

EVALUATION

A diagnosis of acute pericarditis should be reserved for patients with an audible pericardial friction rub or chest pain with typical electrocardiographic findings, most notably widespread ST-segment elevation. Subsequent testing is performed to assess the cause of the disease, to corroborate the diagnosis, and to direct therapy. Important conditions that may cause chest pain similar to that of pericarditis include myocardial infarction and pulmonary embolism (Table 2).

History

The chest pain of acute pericarditis typically is retrosternal in location, sudden in onset, and pleuritic in nature, in that it is exacerbated by inspiration. It is often worse when the

Table 1. Tests and Treatments for Various Causes of Acute Pericarditis.*

Condition	Estimated Incidence†	Clinical Indications and Tests	Usual Treatment
Idiopathic	85–90%		Aspirin, NSAIDs
Infectious			
Viral	1–2%	Acute and convalescent viral titers, viral cultures, serologic test for HIV	Aspirin, NSAIDs
Bacterial	1–2%	Fever, elevated white-cell count; examination of pericardial fluid	Antibiotics, drainage of pericardial fluid
Tuberculous	4%	Chest radiography, tuberculin skin test, histologic examination, cultures, and measurement of adenosine deaminase level in pericardial fluid and tissue	Multidrug antituberculous therapy and prednisone
Acute myocardial infarction	NA (occurs in 5–10% of patients with myocardial infarction)	Electrocardiography, serum troponin or creatine kinase, echocardiogram	Aspirin (avoid NSAIDs)
Aortic dissection	Rare (<1%)	Magnetic resonance imaging, computed tomography, transesophageal echocardiography	Urgent surgery
Trauma	NA	Clinical history	NSAIDs (avoid aspirin)
Neoplasm	7%	Constitutional symptoms, lymphadenopathy; chest radiography, examination of pericardial fluid	NSAIDs, glucocorticoids (by intrapericardial instillation)
Chest-wall irradiation	Rare (<1%)	Clinical history	NSAIDs
Uremia	NA (occurs in approximately 5% of patients with chronic renal disease before initiation of dialysis and 13% after initiation of dialysis)	Serum blood urea nitrogen and creatinine levels	Initiate or intensify dialysis
Cardiotomy or thoracic surgery	Rare (<1%)	Clinical history, evidence of polyserositis; chest radiography, erythrocyte sedimentation rate	Aspirin, NSAIDs
Autoimmune or inflammatory disease	3–5%	Rheumatoid factor, complement levels, antinuclear antibodies	Aspirin, NSAIDs, glucocorticoids
Adverse drug reaction‡	Rare (<1%)	Clinical history; eosinophil count	Discontinue drug; aspirin, NSAIDs

* NSAID denotes nonsteroidal antiinflammatory drug, HIV human immunodeficiency virus, and NA not applicable.

† Estimated incidence is derived from studies that excluded patients with pericarditis associated with renal failure, known neoplastic disease, trauma, or radiation. Data are adapted from Zayas et al.³ and Permanyer-Miralda et al.⁴

‡ Commonly implicated drugs include dantrolene, doxorubicin, hydralazine, isoniazid, methysergide, pergolide, phenylbutazone, phenytoin, and procainamide.

patient is supine and improves when he or she sits upright and leans forward. As in myocardial infarction, the pain often radiates to the neck, arms, or left shoulder. If the pain radiates to one or both trapezius muscle ridges, it is probably due to pericarditis, since the phrenic nerve (which innervates these muscles) traverses the pericardium.

Physical Examination

About 85 percent of patients with pericarditis have an audible friction rub during the course of their dis-

ease.³ Typically, the rub is a high-pitched scratchy or squeaky sound best heard at the left sternal border at end expiration with the patient leaning forward. Since pericardial friction rubs often vary in intensity from minute to minute, patients who have suspected pericarditis should be examined repeatedly.

The friction rub corresponds temporally to movement of the heart within the pericardial sac. Although it is thought to be caused by the rubbing together of the inflamed, adjacent visceral and pa-

Table 2. Features That Differentiate Pericarditis from Myocardial Ischemia or Infarction and Pulmonary Embolism.

Symptom and Clinical Finding	Myocardial Ischemia or Infarction	Pericarditis	Pulmonary Embolism
Chest pain			
Location	Retrosternal	Retrosternal	Anterior, posterior, or lateral
Onset	Sudden, often waxing and waning	Sudden	Sudden
Character	Pressure-like, heavy, squeezing	Sharp, stabbing, occasionally dull	Sharp, stabbing
Change with respiration	No	Worsened with inspiration	In phase with respiration (absent when the patient is apneic)
Change with position	No	Worse when patient is supine; improved when sitting up or leaning forward	No
Radiation	Jaw, neck, shoulder, one or both arms	Jaw, neck, shoulder, one or both arms, trapezius ridge	Shoulder
Duration	Minutes (ischemia); hours (infarction)	Hours to days	Hours to days
Response to nitroglycerin	Improved	No change	No change
Physical examination			
Friction rub	Absent (unless pericarditis is present)	Present (in 85% of patients)	Rare; a pleural friction rub is present in 3% of patients
S3 sound, pulmonary congestion	May be present	Absent	Absent
Electrocardiogram			
ST-segment elevation	Convex and localized	Concave and widespread	Limited to lead III, aVF, and V ₁
PR-segment depression	Rare	Frequent	None
Q waves	May be present	Absent	May be present in lead III or aVF or both
T waves	Inverted when ST segments are still elevated	Inverted after ST segments have normalized	Inverted in lead II, aVF, or V ₁ to V ₄ while ST segments are elevated
Atrioventricular block, ventricular arrhythmias	Common	Absent	Absent
Atrial fibrillation	May be present	May be present	May be present

rietal pericardial surfaces, it is present even when a large effusion separates these surfaces, and it often disappears when the effusion is evacuated, a finding that casts doubt on this explanation. The friction rub is classically described as having three components, which correspond to atrial systole (in patients with sinus rhythm), ventricular systole, and rapid ventricular filling during early diastole. However, in reality, the rub is reported to be triphasic in about half the patients, biphasic in a third, and monophasic in the remainder.¹² A pericardial friction rub should not be confused with a pleural rub; the former is audible throughout the respiratory cycle, whereas the latter is absent when respirations are suspended.

The presence of systemic arterial hypotension, tachycardia, elevated jugular venous pressure, and pulsus paradoxus (a decrease in systolic arterial pressure of more than 10 mm Hg with inspiration) suggests cardiac tamponade; the presence of pulsus paradoxus is most sensitive, although not specific, for the diagnosis. Tamponade, a potentially lethal complication of pericarditis, is reported in about 15 percent of patients with idiopathic pericarditis but in as many as 60 percent of those with neoplastic, tuberculous, or purulent pericarditis.¹³ With tamponade, the accumulation of pericardial fluid increases the intrapericardial pressure so that it equals or exceeds the pressure in the right heart chambers, leading to impaired filling, with result-

ant collapse of the right atrium and ventricle during diastole and diminished cardiac output. These findings should prompt immediate echocardiographic evaluation, including pulsed-wave Doppler analysis.

A body temperature greater than 38°C is uncommon and may indicate purulent pericarditis. Patients who are febrile should undergo prompt echocardiography, and the physician should consider obtaining pericardial fluid for analysis.

Electrocardiography

The 12-lead electrocardiogram in patients with acute pericarditis classically shows widespread upward concave ST-segment elevation and PR-segment depression (Fig. 1).¹⁴⁻¹⁷ The electrocardiographic abnormalities may evolve through four phases: diffuse ST-segment elevation and PR-segment depression (stage I); normalization of the ST and PR segments (stage II); widespread T-wave inversions (stage III); and normalization of the T waves (stage IV).¹⁵ Although the prompt institution of therapy may prevent the appearance of all four stages,¹⁸ the changes in stage I are observed in more than 80 percent of patients with pericarditis.¹⁹ ST-segment elevation also occurs in patients with myocardial infarction, but several features may help to distinguish these entities. With infarction, the

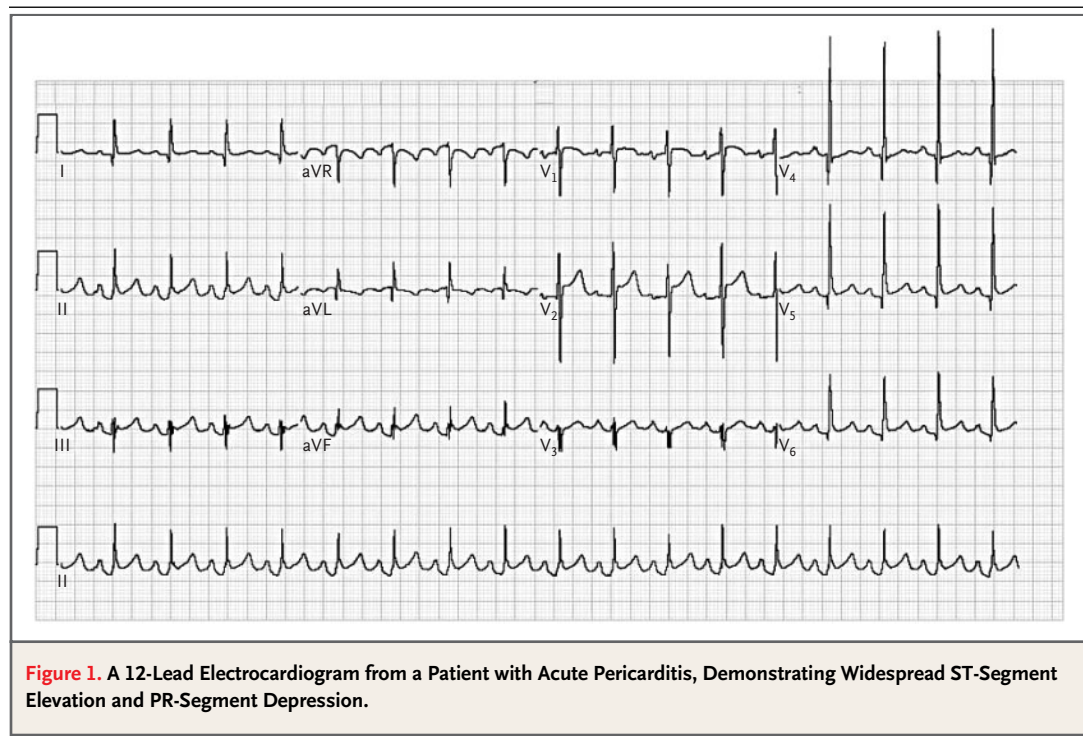
ST-segment elevations are often convex (dome-shaped) rather than concave in configuration, and they are regional rather than widespread; Q-wave formation and loss of R-wave voltage often occur; T-wave inversions appear before the ST segments return to baseline; PR-segment depression is uncommon; and atrioventricular block or ventricular arrhythmias are common (Table 2). The most reliable distinguishing feature may be the ratio of ST-segment elevation (in millimeters) to T-wave amplitude (height in millimeters) in lead V₆. When this ratio exceeds 0.24, acute pericarditis is almost always present.¹⁴

Chest Radiography

Chest radiography is performed primarily to rule out abnormalities in the mediastinum or lung fields that may be responsible for the pericarditis. The appearance of cardiomegaly indicates a substantial pericardial effusion (more than 250 ml).

Serologic and Other Testing

Data assessing the cost-effectiveness of various testing strategies are lacking. Although the white-cell count, erythrocyte sedimentation rate, and serum C-reactive protein concentration usually are elevated in patients with acute pericarditis, these tests



usually provide little, if any, insight into the cause of the disease or indications regarding which therapy is called for. A markedly elevated white-cell count suggests the presence of purulent pericarditis; therefore, it is reasonable to obtain a complete blood count in all patients. The clinical presentation should guide the ordering of additional tests (i.e., serologic testing for antinuclear antibody or infection with the human immunodeficiency virus). Routine serologic testing, including testing for antinuclear antibody and rheumatoid factor, reveals a source for the pericarditis in only 10 to 15 percent of patients, and in these cases other evidence typically suggests the underlying disease. Many patients with idiopathic pericarditis probably have a viral infection, but viral cultures and antibody titers are not useful clinically,^{3,4,13} and the documentation of a recent viral infection does not alter management.

Plasma troponin concentrations are elevated in 35 to 50 percent of patients with pericarditis, a finding that is thought to be caused by epicardial inflammation rather than myocyte necrosis.^{6,20,21} The magnitude of elevation in the serum troponin concentration appears to correlate with the magnitude of the ST-segment elevation, and the concentration usually returns to normal within one to two weeks after diagnosis. An elevated troponin concentration does not predict an adverse outcome,^{5,6} although a prolonged elevation (lasting longer than two weeks) suggests associated myocarditis, which has a worse prognosis. Although the concentrations of serum creatine kinase and its MB fraction may also be elevated with pericarditis, they are abnormal less often than is the troponin concentration.

Echocardiography

Transthoracic echocardiography^{22,23} is often recommended in patients with suspected pericarditis, since the presence of an effusion helps to confirm the diagnosis, and clinical or echocardiographic evidence of tamponade indicates the need for pericardiocentesis. The test is unnecessary in patients with unequivocal evidence of pericarditis and no poor prognostic indicators.

Pericardiocentesis and Biopsy

Pericardiocentesis is indicated in patients with pericardial tamponade and in those with known or suspected purulent or neoplastic pericarditis. In patients with a small or midsize effusion of unknown cause, neither pericardiocentesis nor pericardial biopsy usually yields a diagnosis. In 231 consecutive

patients with acute pericarditis in whom the cause was unknown after routine clinical and laboratory evaluation, pericardiocentesis and pericardial biopsy provided a diagnosis in only 6 percent and 5 percent of cases, respectively. In subjects with tamponade of unknown cause, pericardiocentesis and pericardial biopsy provided a diagnosis in 29 percent and 54 percent of cases, respectively.⁴

When pericardiocentesis is performed, the fluid should be analyzed for red-cell and white-cell counts, cytologic evidence of cancer, and triglycerides (a fluid that is milky in color and consistency suggests a chylous effusion). Although the pH and levels of glucose, lactic dehydrogenase, and protein often are measured, no accepted criteria link such measures to specific causes of pericarditis. The fluid should be examined microscopically for organisms, and it should be cultured. The results of polymerase-chain-reaction assays or high concentrations of adenosine deaminase activity (greater than 30 U per liter) are helpful in identifying *Mycobacterium tuberculosis*.²⁴⁻²⁷ Pericardial biopsy should be considered for patients who have recurrent tamponade despite treatment.¹³

TREATMENT

If a specific cause of pericarditis is identified, treatment should be directed accordingly. A detailed discussion of therapies directed to specific causes is beyond the scope of this review, but the treatments are summarized in Table 1.

For patients with idiopathic pericarditis, therapy is aimed at the relief of chest pain and inflammation. However, such treatment does nothing to prevent tamponade, constriction, or recurrent pericarditis. Nonsteroidal antiinflammatory agents (NSAIDs) are the mainstay of therapy; in observational studies, these drugs are effective in relieving chest pain in 85 to 90 percent of patients,^{3,4,20} and limited observational data suggest that the various agents have similar efficacy.²⁸⁻³⁰ Aspirin (2 to 4 g daily), indomethacin (75 to 225 mg daily), and ibuprofen (1600 to 3200 mg daily) are prescribed most often, with ibuprofen preferred, since it has a lower incidence of adverse effects than the others. Aspirin is preferable for patients who have had a recent myocardial infarction, since other NSAIDs impair scar formation in studies in animals.^{28,31-33} Indomethacin should be avoided in patients with coronary artery disease, since it diminishes coronary blood flow.²⁸

Colchicine (administered at a dose of 0.6 mg

twice daily) appears to be effective alone or in combination with ibuprofen in treating acute pericarditis, although it has not been tested in randomized trials; it is preferred for patients who have recurrent pericarditis.^{34,35} In a multicenter trial of 51 patients who had recurrent pericarditis despite treatment with nonsteroidal antiinflammatory agents, glucocorticoids, pericardiocentesis, or some combination thereof, only 7 of the patients who were treated with colchicine (14 percent) had a recurrence during 1004 patient-months of follow-up.³⁴

Typically, patients' symptoms improve within days of the initiation of antiinflammatory therapy. If chest pain persists after two weeks of treatment with an NSAID, a different NSAID should be given or colchicine should be added to provide combination therapy. If the patient continues to have chest pain despite combination therapy, glucocorticoids should be considered. A lack of response to glucocorticoids often reflects the use of an inadequate dose or too-rapid tapering. Patients with a relapse of pericarditis after a short-term course of low-dose glucocorticoid therapy often obtain symptomatic relief when higher-dose prednisone therapy (1 to 1.5 mg per kilogram of body weight daily) is administered for four weeks.³⁶

Concern has been raised that treating acute pericarditis with prednisone may increase the risk of recurrence.³⁷⁻³⁹ In observational studies, patients who received glucocorticoids early in the course of the disease appeared to be more likely to develop recurrent pericarditis than patients who did not receive glucocorticoids. Data from animal studies have shown that glucocorticoids exacerbated pericardial injury that was virally induced.⁴⁰ These data argue against the routine administration of glucocorticoids during a first episode of pericarditis.^{35,39,41,42}

In general, systemic glucocorticoid treatment (prednisone, 1 to 1.5 mg per kilogram daily) should be restricted to patients with connective-tissue diseases or severely symptomatic recurrent pericarditis that is unresponsive to NSAIDs and colchicine. Alternatively, the intrapericardial instillation of a non-absorbable steroid has appeared highly effective in a case series of patients with refractory or recurrent pericarditis and has averted the adverse effects of these agents.⁴³

HOSPITALIZATION

In most patients, acute pericarditis has a brief and benign course, with symptoms lasting less than two weeks, and the condition responds well to the ad-

ministration of NSAIDs. If a small or midsize effusion is present, it usually resolves within weeks. As a result, hospitalization for evaluation or treatment is unnecessary in most cases, and follow-up evaluation is not required unless symptoms recur or new symptoms appear. Several indicators of a poor prognosis are recognized, however. These include a temperature above 38°C, a subacute onset (symptoms developing during a period of several weeks), an immunosuppressed state, pericarditis associated with trauma, a history of oral anticoagulant therapy, myopericarditis (pericarditis with clinical or serologic evidence of myocardial involvement), a large pericardial effusion (an echo-free space of more than 20 mm in width) (Fig. 2), or cardiac tamponade. Although serologic criteria for associated myocarditis are not well defined, historically concern has focused on elevated levels of creatine kinase, particularly if the elevation is sustained for more than a week. Patients with one or more of these symptoms are at increased risk for serious complications, including death from tamponade and purulent pericarditis. In a report describing 253 patients who had none of these poor prognostic indicators and were treated without admission to the hospital,²⁰ none of the patients had serious complications during an average follow-up of 39 months.

GUIDELINES

There are no specific guidelines for evaluating or treating pericarditis. A joint task force of the American College of Cardiology, the American Heart Association, and the American Society of Echocardiography recommends that echocardiography be performed in all patients with known or suspected pericardial disease. (Guidelines are available online at www.acc.org, www.americanheart.org, and www.asecho.org.) Subsequent echocardiography is not recommended in patients who are stable and whose pericardial effusions are small, but this procedure may be performed if a recurrence of effusion or early constriction is suspected.^{22,23}

AREAS OF UNCERTAINTY

Randomized trials are lacking to guide the evaluation and management of acute pericarditis. Strategies to prevent recurrent pericarditis, which occurs in 15 to 30 percent of patients with idiopathic pericarditis, require further study. It remains uncertain, but of concern, whether the early use of glucocorti-

coids increases the risk of recurrent pericarditis. When there is a recurrence, pericardiectomy can be performed, but the procedure is rarely successful in resolving symptoms, perhaps because of an auto-immunologic reaction to persistent antigens in the epicardium. Observational data suggest that physical invasion of the pericardium (with pericardiotomy or the creation of a window) promotes recurrences, a finding similar to that regarding glucocorticoid therapy. In most patients, then, treatment of recurrent pericarditis is largely supportive. Observational data suggest that colchicine offers the best prophylaxis against recurrent episodes. Although recurrences are often accompanied by a pericardial effusion, tamponade and constriction rarely occur; thus, these effusions do not require drainage.

CONCLUSIONS AND RECOMMENDATIONS

In patients with acute pericarditis, such as the woman described in the vignette, the cause is most often either idiopathic or viral. The diagnosis is based on clinical criteria (i.e., a pericardial friction rub or chest pain with typical electrocardiographic findings), and laboratory testing is not routinely required. Since simple pericardiocentesis with subsequent analysis of the pericardial fluid is unlikely to provide valuable diagnostic information in the absence of cardiac tamponade or suspected purulent or neoplastic pericarditis, the procedure should generally be reserved for patients in whom such conditions are suspected.

The evaluation and treatment of patients with acute pericarditis can be performed in the ambulatory setting unless the patient has a temperature

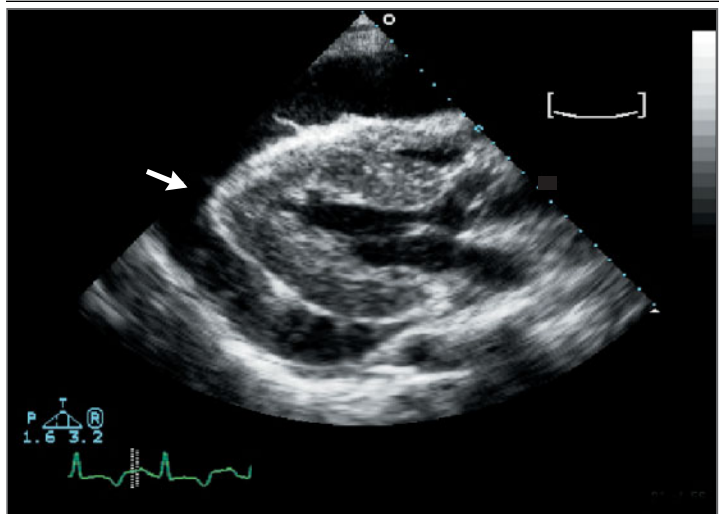


Figure 2. Large Pericardial Effusion.

A parasternal long-axis view from a transthoracic echocardiogram shows the heart surrounded by a large pericardial effusion, seen as an echo-free space more than 20 mm in width (arrow).

above 38°C, a subacute onset, an immunosuppressed state, a history of trauma, a history of oral anticoagulant therapy, myopericarditis, a large pericardial effusion, or evidence of tamponade. In most patients, acute pericarditis has a brief and benign course and an excellent response to NSAIDs, alone or in combination with colchicine. Therapy with glucocorticoids should be reserved for the patient with pericarditis that is unresponsive to combination therapy, since some studies suggest that the early use of these drugs may increase the risk of recurrence.

REFERENCES

1. Lorell BH. Pericardial diseases. In: Braunwald E, ed. Heart disease: a textbook of cardiovascular medicine. 5th ed. Philadelphia: W.B. Saunders, 1997:1478-534.
2. Launbjerg J, Fruergaard P, Hesse B, Jorgensen F, Elsborg L, Petri A. Long-term risk of death, cardiac events and recurrent chest pain in patients with acute chest pain of different origin. *Cardiology* 1996;87:60-6.
3. Zayas R, Anguita M, Torres F, et al. Incidence of specific etiology and role of methods for specific etiologic diagnosis of primary acute pericarditis. *Am J Cardiol* 1995; 75:378-82.
4. Permyner-Miralda G, Sagrista-Sauleda J, Soler-Soler J. Primary acute pericardial disease: a prospective series of 231 consecutive patients. *Am J Cardiol* 1985;56:623-30.
5. Imazio M, Demichelis B, Cecchi E, et al. Cardiac troponin I in acute pericarditis. *J Am Coll Cardiol* 2003;42:2144-8.
6. Bonnefoy E, Godon P, Kirkorian G, Fatemi M, Chevalier P, Touboul P. Serum cardiac troponin I and ST-segment elevation in patients with acute pericarditis. *Eur Heart J* 2000;21:832-6.
7. Allaria A, Michelli D, Capelli H, Berri G, Gutierrez D. Transient cardiac constriction following purulent pericarditis. *Eur J Pediatr* 1992;151:250-1.
8. Oh JK, Hatle LK, Mulvagh SL, Tajik AJ. Transient constrictive pericarditis: diagnosis by two-dimensional Doppler echocardiography. *Mayo Clin Proc* 1993;68:1158-64.
9. Woods T, Vidarsson B, Mosher D, Stein JH. Transient effusive-constrictive pericarditis due to chemotherapy. *Clin Cardiol* 1999;22:316-8.
10. Haley JH, Tajik AJ, Danielson GK, Schaff HV, Mulvagh SL, Oh JK. Transient constrictive pericarditis: causes and natural history. *J Am Coll Cardiol* 2004;43:271-5.
11. Sagrista-Sauleda J, Permyner-Miralda G, Candell-Riera J, Angel J, Soler-Soler J. Transient cardiac constriction: an unrecognized pattern of evolution in effusive acute idiopathic pericarditis. *Am J Cardiol* 1987; 59:961-6.
12. Spodick DH. Pericardial rub: prospective, multiple observer investigation of pericardial friction in 100 patients. *Am J Cardiol* 1975;35:357-62.
13. Permyner-Miralda G. Acute pericardial

- disease: approach to the etiologic diagnosis. *Heart* 2004;90:252-4.
14. Ginzton LE, Laks MM. The differential diagnosis of acute pericarditis from the normal variant: new electrocardiographic criteria. *Circulation* 1982;65:1004-9.
 15. Spodick DH. Diagnostic electrocardiographic sequences in acute pericarditis: significance of PR segment and PR vector changes. *Circulation* 1973;48:575-80.
 16. Surawicz B, Lasseter KC. Electrocardiogram in pericarditis. *Am J Cardiol* 1970;26:471-4.
 17. Wang K, Asinger RW, Marriott HJL. ST-segment elevation in conditions other than acute myocardial infarction. *N Engl J Med* 2003;349:2128-35.
 18. Spodick DH. Acute pericarditis: current concepts and practice. *JAMA* 2003;289:1150-3.
 19. Bruce MA, Spodick DH. Atypical electrocardiogram in acute pericarditis: characteristics and prevalence. *J Electrocardiol* 1980;13:61-6.
 20. Imazio M, Demichelis B, Parrini I, et al. Day-hospital treatment of acute pericarditis: a management program for outpatient therapy. *J Am Coll Cardiol* 2004;43:1042-6.
 21. Newby LK, Ohman EM. Troponins in pericarditis: implications for diagnosis and management of chest pains patients. *Eur Heart J* 2000;21:798-800.
 22. Cheitlin MD, Alpert JS, Armstrong WF, et al. ACC/AHA guidelines for the clinical application of echocardiography: a report of the American College of Cardiology/American Heart Association Task Force on Practice Guidelines (Committee on Clinical Application of Echocardiography): developed in collaboration with the American Society of Echocardiography. *Circulation* 1997;95:1686-744.
 23. Cheitlin MD, Armstrong WF, Aurigemma GP, et al. ACC/AHA/ASE 2003 guideline update for the clinical application of echocardiography: summary article: a report of the American College of Cardiology/American Heart Association Task Force on Practice Guidelines (ACC/AHA/ASE Committee to Update the 1997 Guidelines for the Clinical Application of Echocardiography). *Circulation* 2003;108:1146-62.
 24. Aggeli C, Pitsavos C, Brili S, et al. Relevance of adenosine deaminase and lysozyme measurements in the diagnosis of tuberculous pericarditis. *Cardiology* 2000;94:81-5.
 25. Burgess LJ, Reuter H, Carstens ME, Taljaard JJ, Doubell AF. The use of adenosine deaminase and interferon-gamma as diagnostic tools for tuberculous pericarditis. *Chest* 2002;122:900-5.
 26. Cegielski JP, Devlin BH, Morris AJ, et al. Comparison of PCR, culture, and histopathology for diagnosis of tuberculous pericarditis. *J Clin Microbiol* 1997;35:3254-7.
 27. Dogan R, Demircin M, Sarigul A, Ciliv G, Bozer AY. Diagnostic value of adenosine deaminase activity in pericardial fluids. *J Cardiovasc Surg (Torino)* 1999;40:501-4.
 28. Schifferdecker B, Spodick DH. Nonsteroidal anti-inflammatory drugs in the treatment of pericarditis. *Cardiol Rev* 2003;11:211-7.
 29. Arunasalam S, Siegel RJ. Rapid resolution of symptomatic acute pericarditis with ketorolac tromethamine: a parenteral nonsteroidal antiinflammatory agent. *Am Heart J* 1993;125:1455-8.
 30. Berman J, Haffajee CI, Alpert JS. Therapy of symptomatic pericarditis after myocardial infarction: retrospective and prospective studies of aspirin, indomethacin, prednisone, and spontaneous resolution. *Am Heart J* 1981;101:750-3.
 31. Brown EJ Jr, Kloner RA, Schoen FJ, Hammerman H, Hale S, Braunwald E. Scar thinning due to ibuprofen administration after experimental myocardial infarction. *Am J Cardiol* 1983;51:877-83.
 32. Jugdutt BI, Basualdo CA. Myocardial infarct expansion during indomethacin or ibuprofen therapy for symptomatic post infarction pericarditis: influence of other pharmacologic agents during early remodeling. *Can J Cardiol* 1989;5:211-21.
 33. Hammerman H, Kloner RA, Schoen FJ, Brown EJ Jr, Hale S, Braunwald E. Indomethacin-induced scar thinning after experimental myocardial infarction. *Circulation* 1983;67:1290-5.
 34. Adler Y, Finkelstein Y, Guindo J, et al. Colchicine treatment for recurrent pericarditis: a decade of experience. *Circulation* 1998;97:2183-5.
 35. Millaire A, de Groot P, Decoulx E, Goullard L, Ducloux G. Treatment of recurrent pericarditis with colchicine. *Eur Heart J* 1994;15:120-4.
 36. Marcolongo R, Russo R, Laveder F, Noventa F, Agostini C. Immunosuppressive therapy prevents recurrent pericarditis. *J Am Coll Cardiol* 1995;26:1276-9.
 37. Stubbs DF. Post-acute myocardial infarction symptomatic pericarditis (PAMISP): report on a large series and the effect of methylprednisolone therapy. *J Int Med Res* 1986;14:Suppl 1:25-9.
 38. Spodick DH. Intrapericardial treatment of persistent autoreactive pericarditis/myopericarditis and pericardial effusion. *Eur Heart J* 2002;23:1481-2.
 39. Godeau P, Derrida JP, Blety O, Herremann G. Recurrent acute pericarditis and corticoid dependence: apropos of 10 cases. *Sem Hop* 1975;51:2393-400. (In French.)
 40. Kilbourne ED, Wilson CB, Perrier D. The induction of gross myocardial lesions by a Coxsackie (pleurodynia) virus and cortisone. *J Clin Invest* 1956;35:362-70.
 41. Clementy J, Jambert H, Dallochio M. Recurrent acute pericarditis: 20 cases. *Arch Mal Coeur Vaiss* 1979;72:857-61. (In French.)
 42. Raatikka M, Pelkonen PM, Karjalainen J, Jokinen EV. Recurrent pericarditis in children and adolescents: report of 15 cases. *J Am Coll Cardiol* 2003;42:759-64.
 43. Maisch B, Ristic AD, Pankuweit S. Intrapericardial treatment of autoreactive pericardial effusion with triamcinolone: the way to avoid side effects of systemic corticosteroid therapy. *Eur Heart J* 2002;23:1503-8.

Copyright © 2004 Massachusetts Medical Society.

CORRECTION

Acute Pericarditis

Acute Pericarditis . On page 2198, in the right-hand column, lines 8 through 13 should have read, "ST-segment elevation also may be seen in patients with an early repolarizing pattern. The most reliable feature in distinguishing pericarditis from early repolarization may be the ratio of ST-segment elevation to T-wave height in lead V₆; when this ratio exceeds 0.24, acute pericarditis is almost always present," rather than, "The most reliable distinguishing feature may be the ratio of ST-segment elevation (in millimeters) to T-wave amplitude (height in millimeters) in lead V₆. When this ratio exceeds 0.24, acute pericarditis is almost always present," as printed.