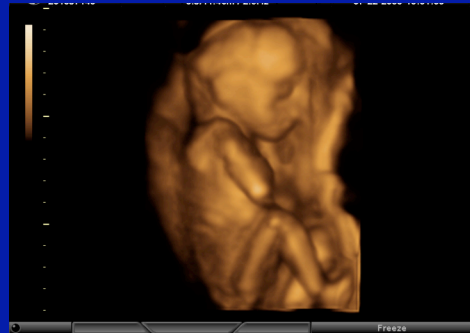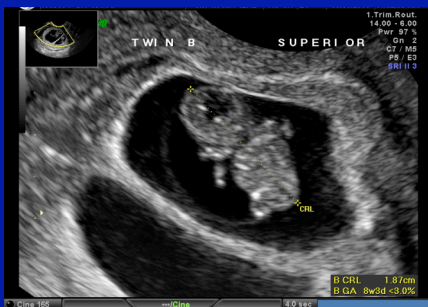
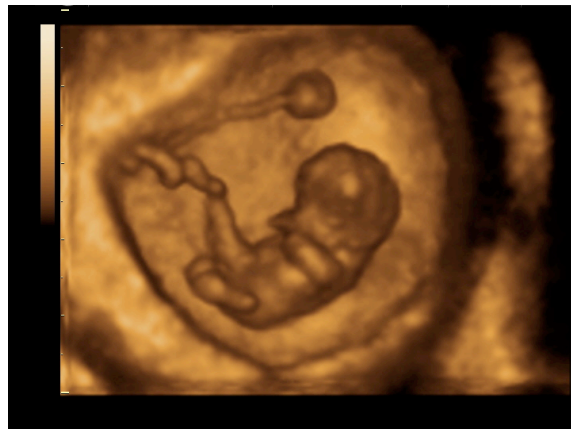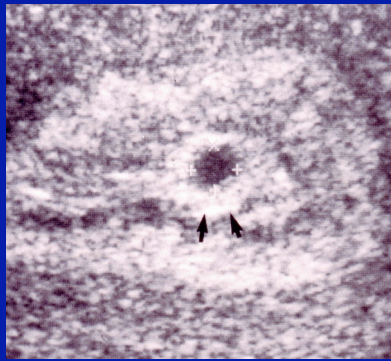


## The Fetus As A Patient

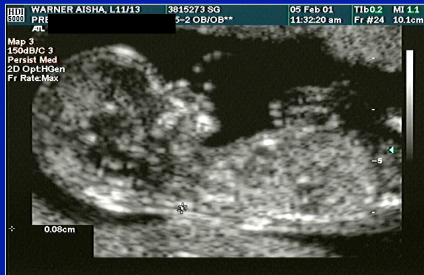


Richard L. Berkowitz, MD  
Professor of Obstetrics and Gynecology  
Columbia University College of Physicians & Surgeons

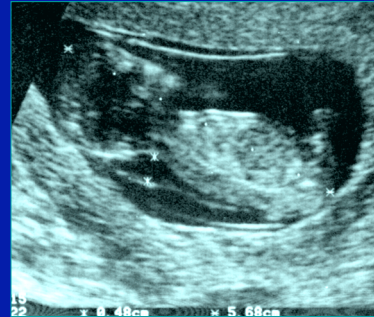
## First Trimester



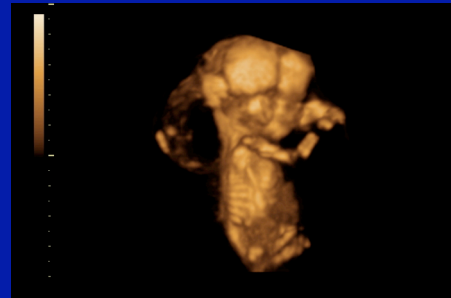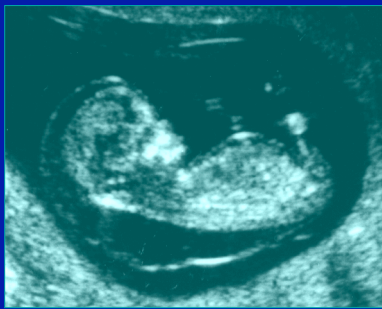## Normal Nuchal Translucency



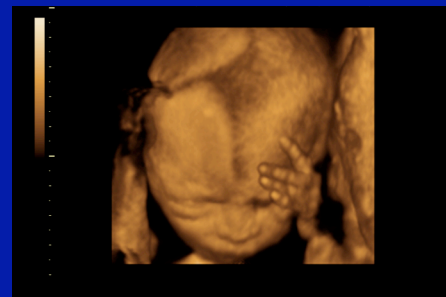## Increased Nuchal Translucency

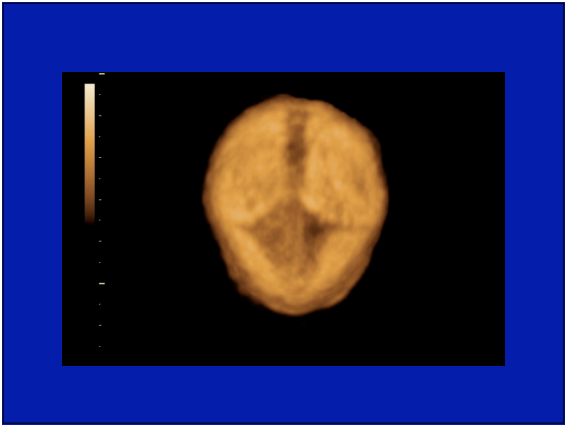


## Cystic Hygroma - Sagittal

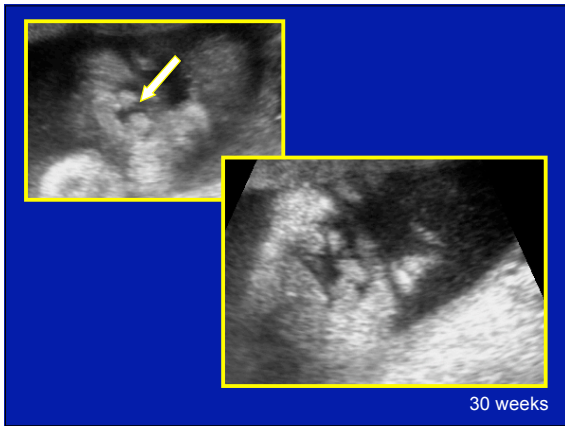
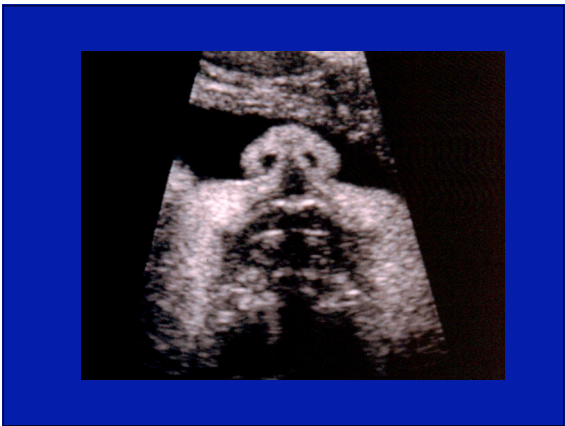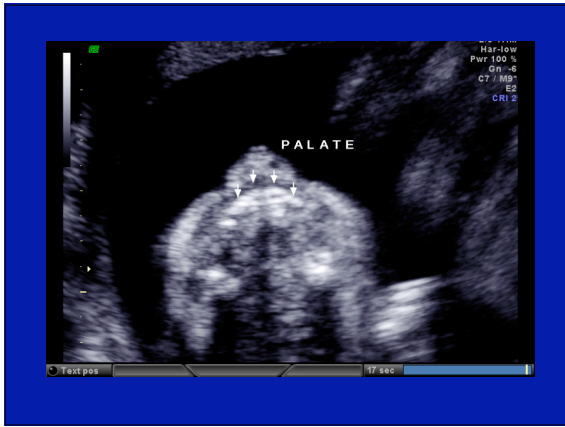
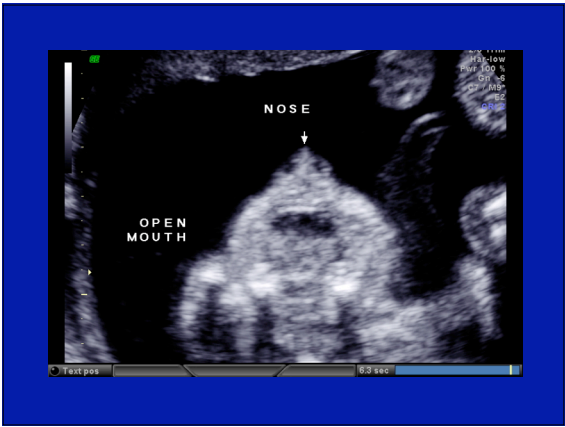


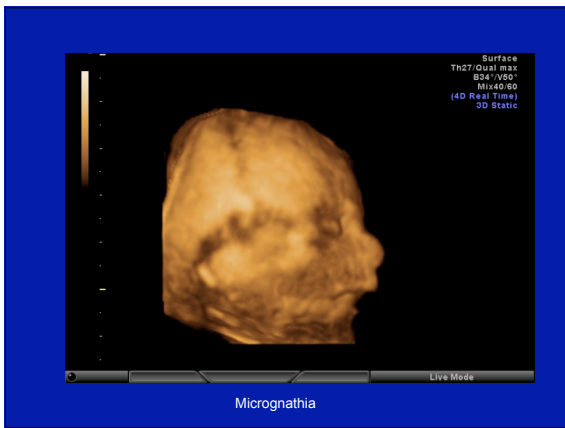
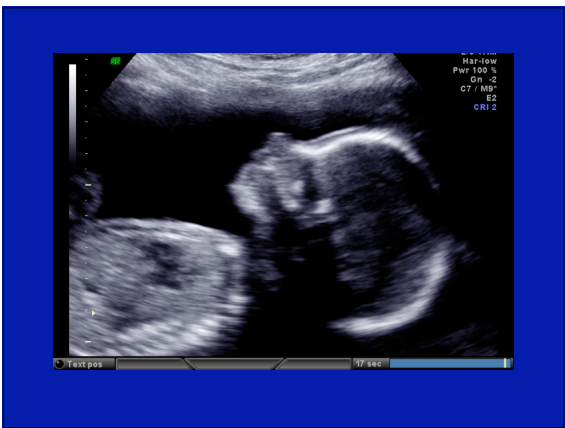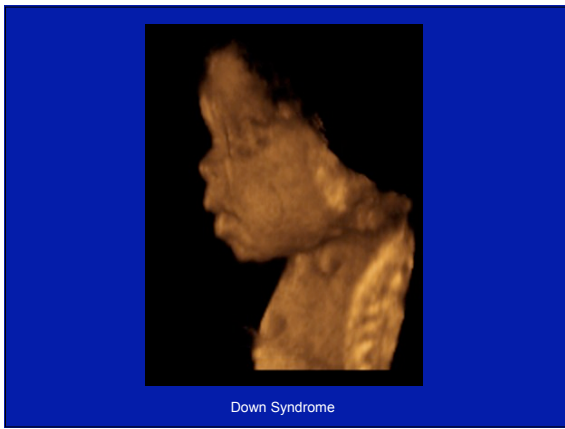
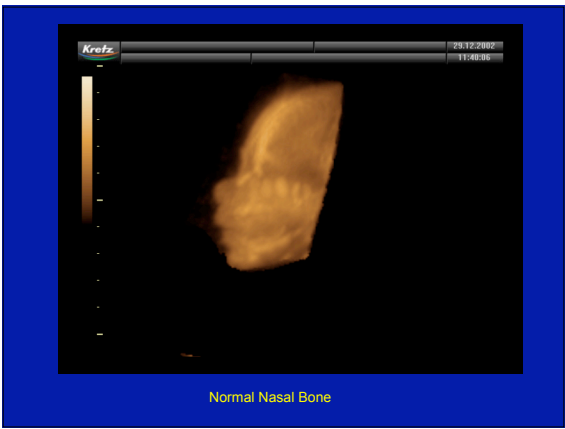
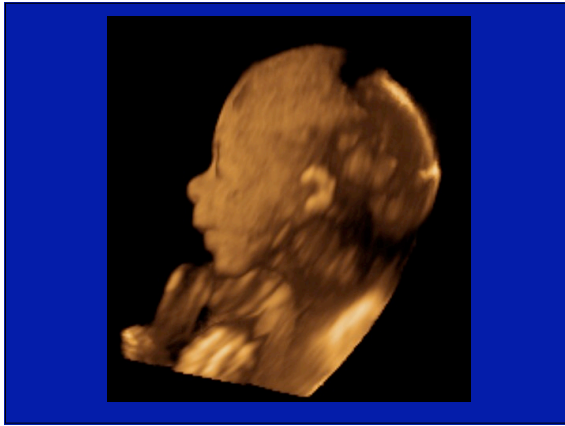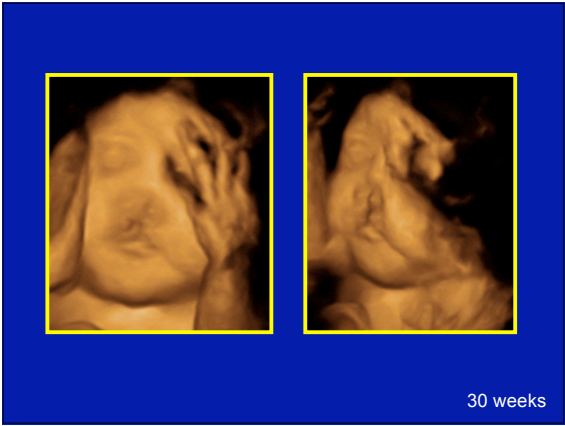
## Second Trimester



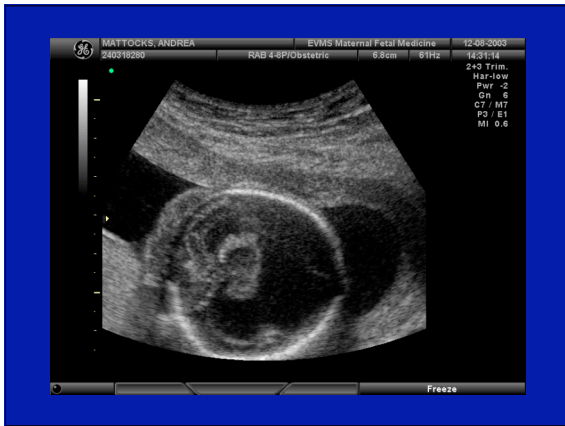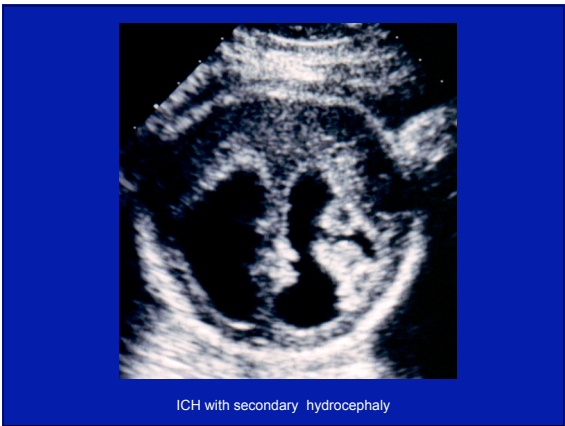
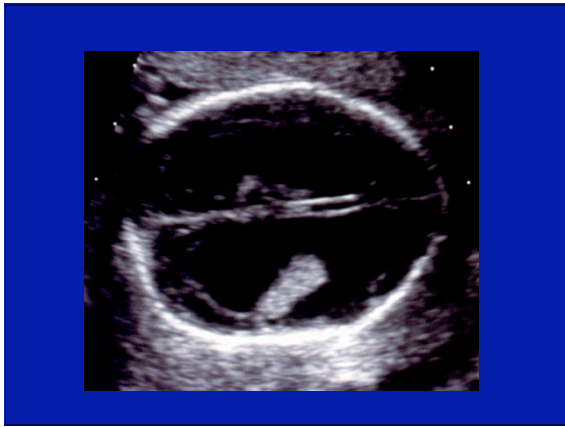
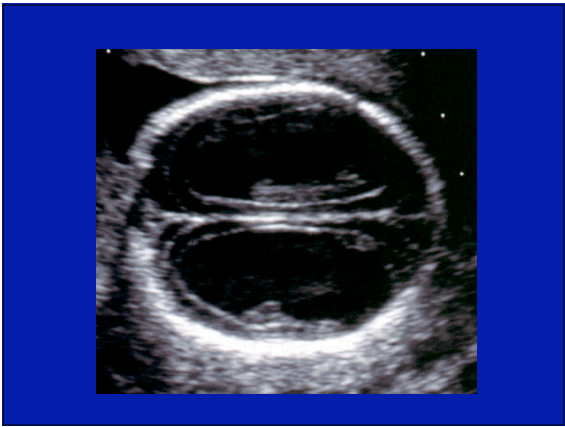
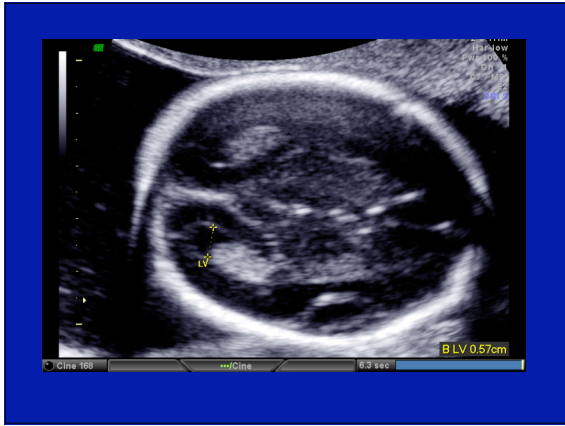

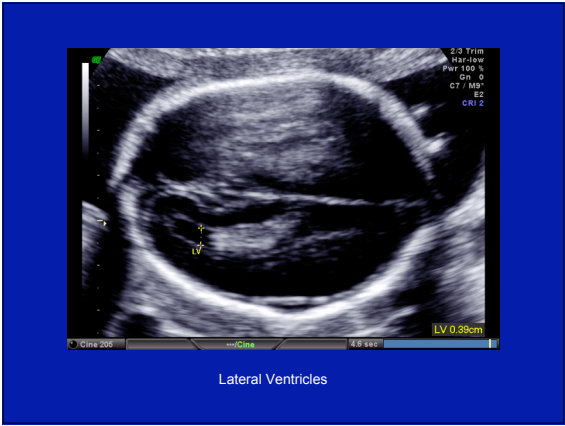
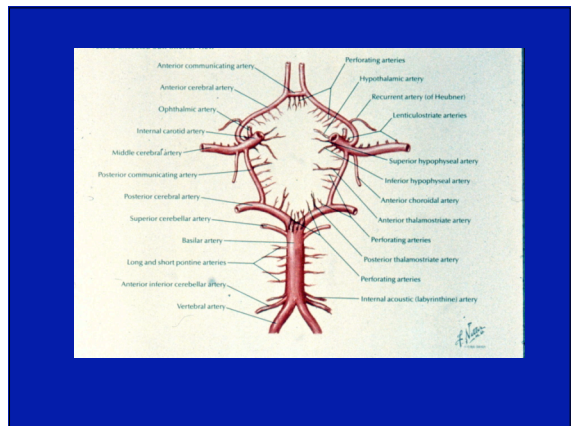
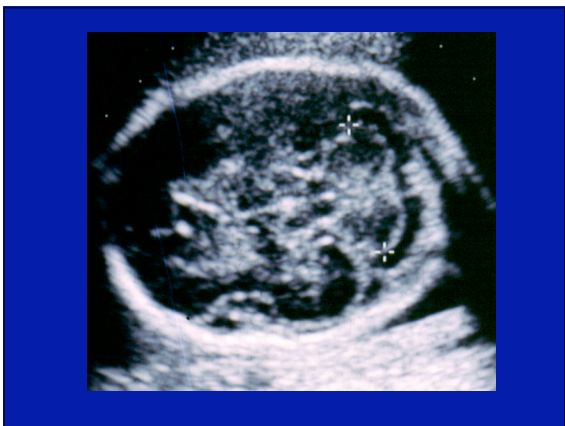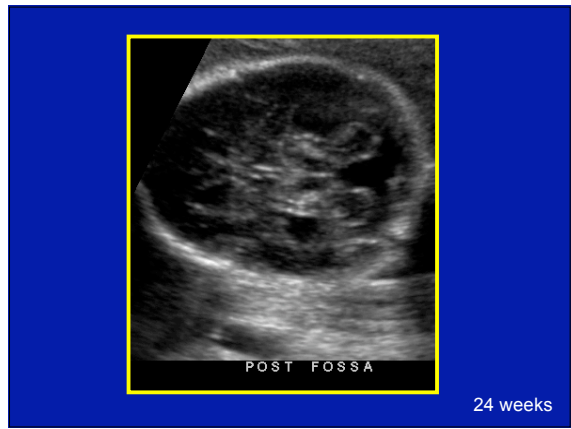
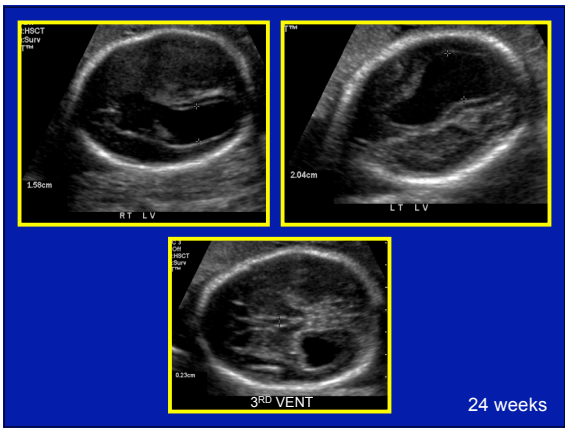
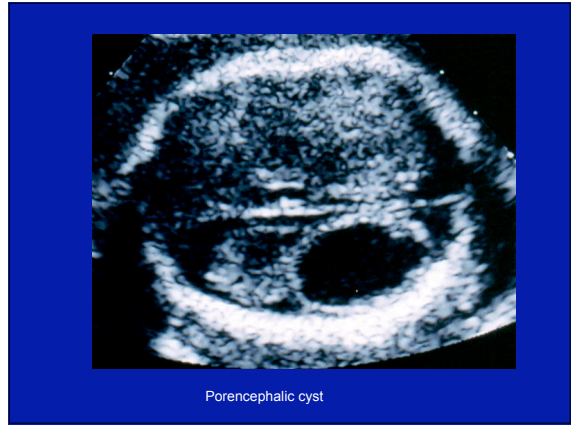
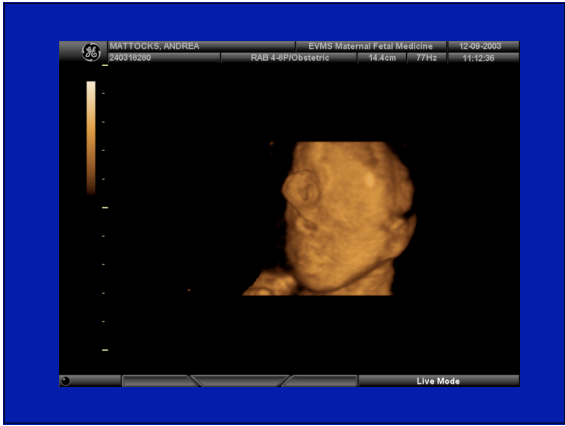
# The Face

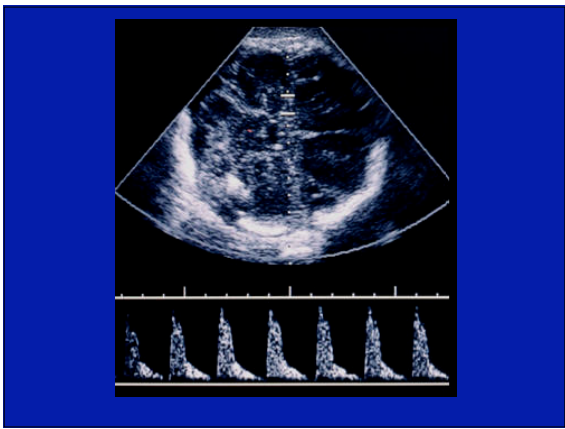
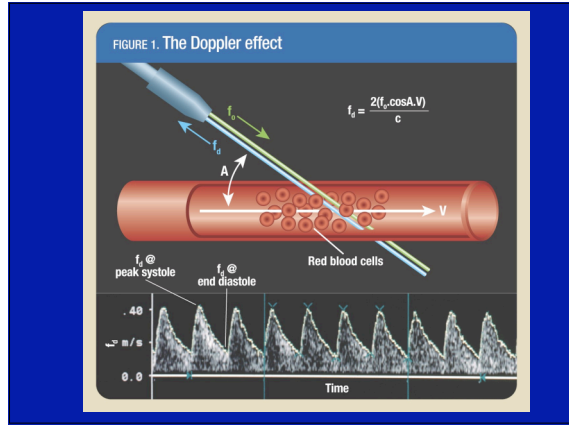
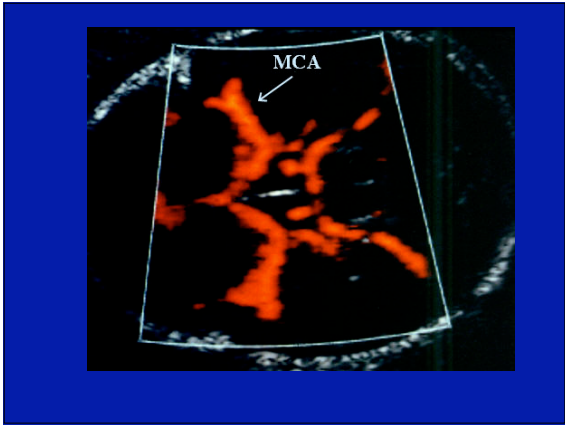




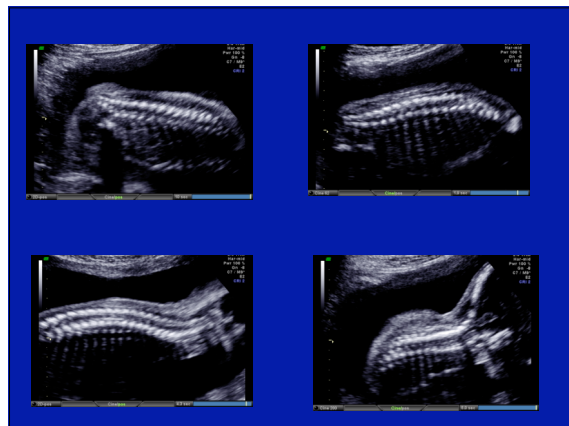
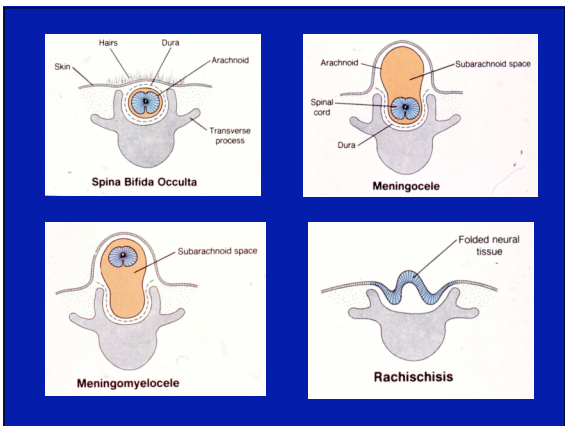


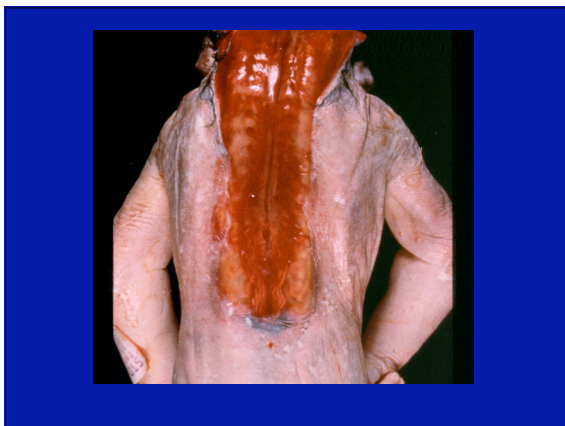
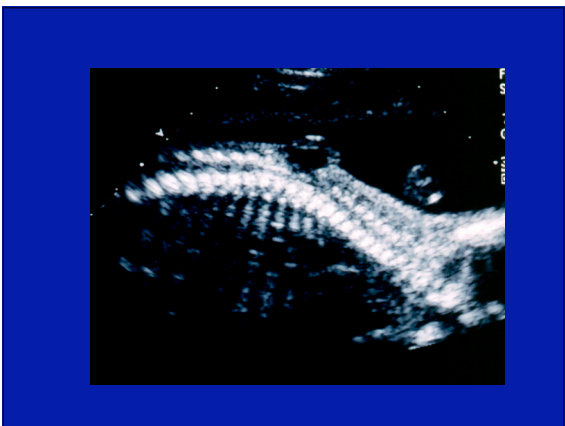
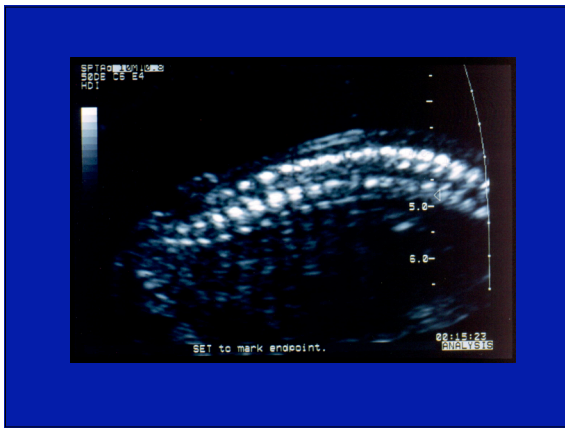
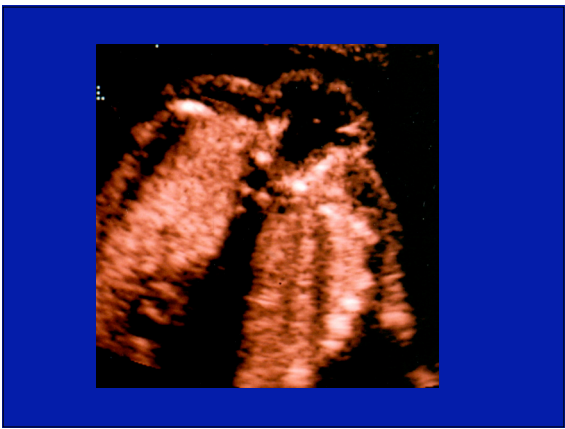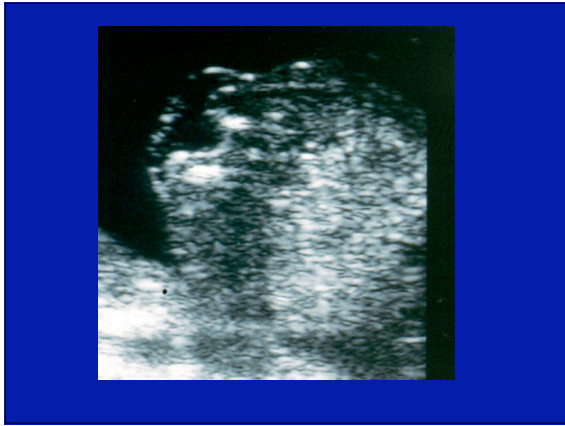

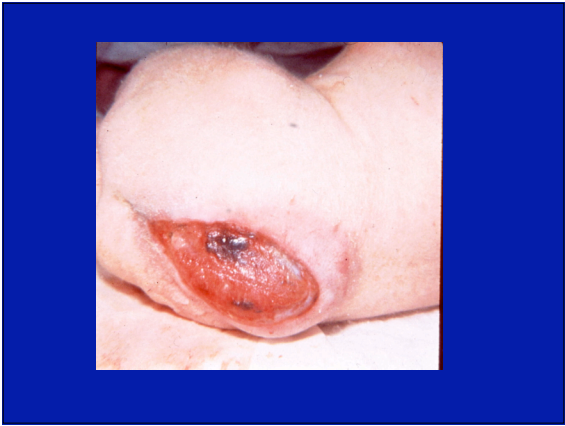


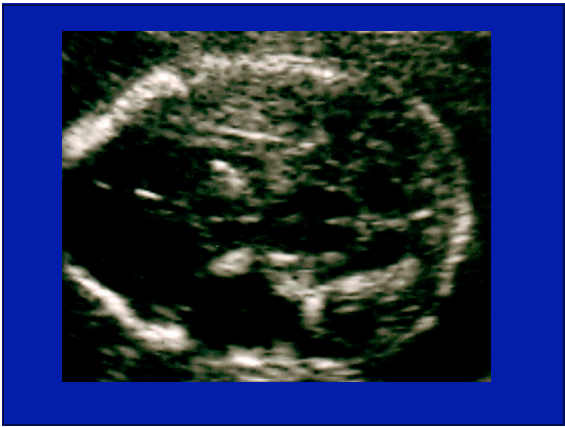
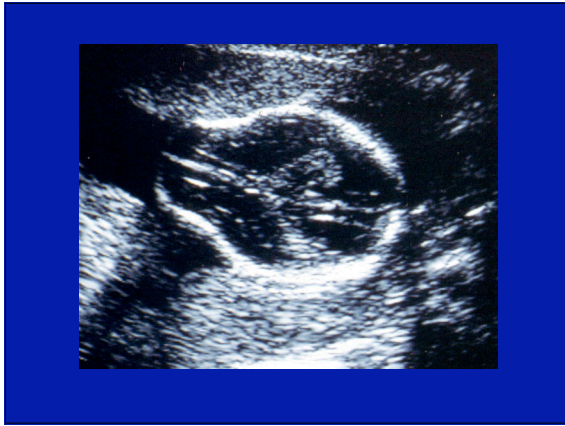

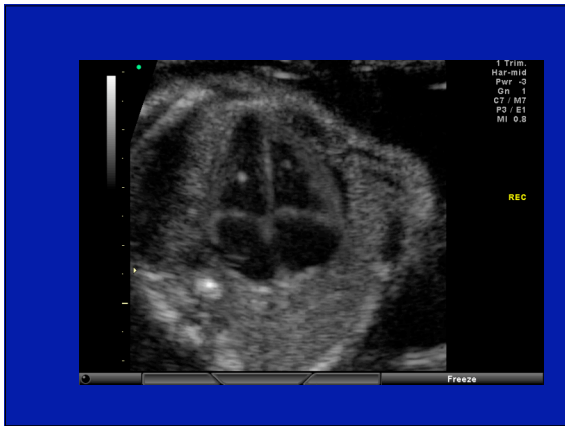
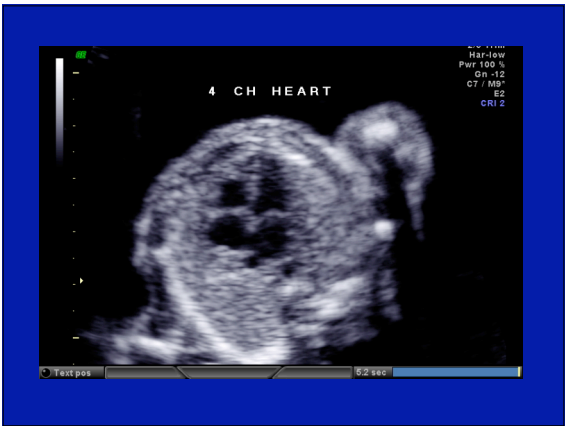# Neural Tube Defects

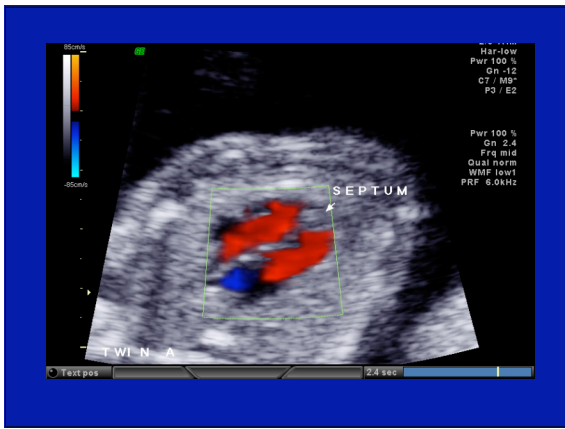
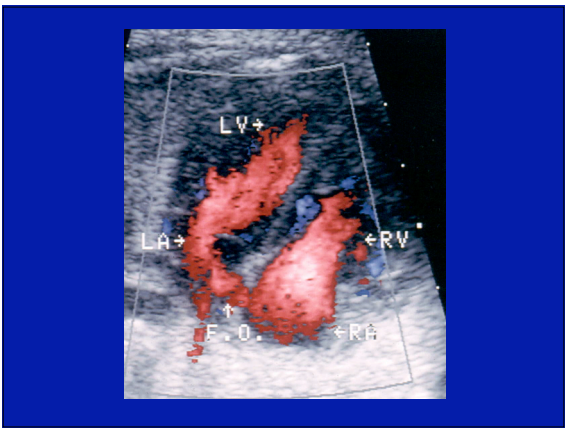
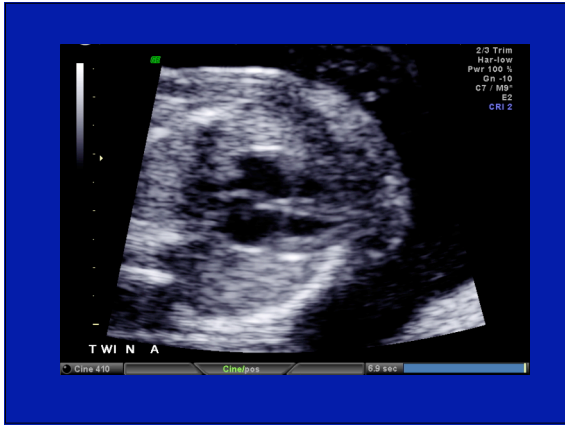
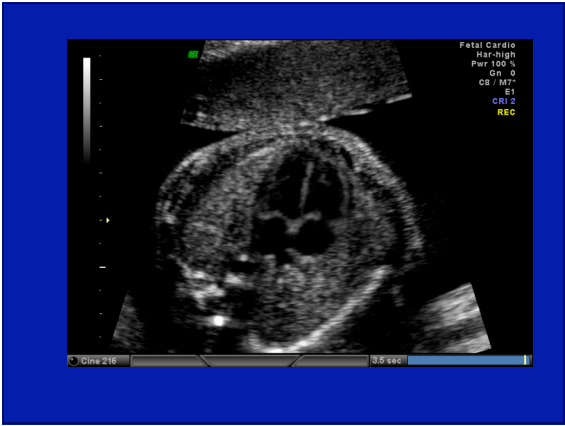




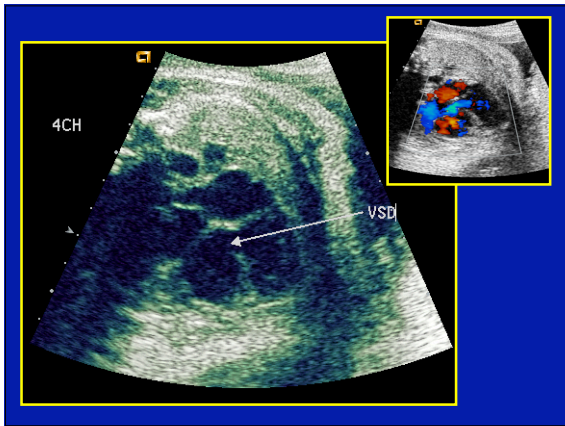


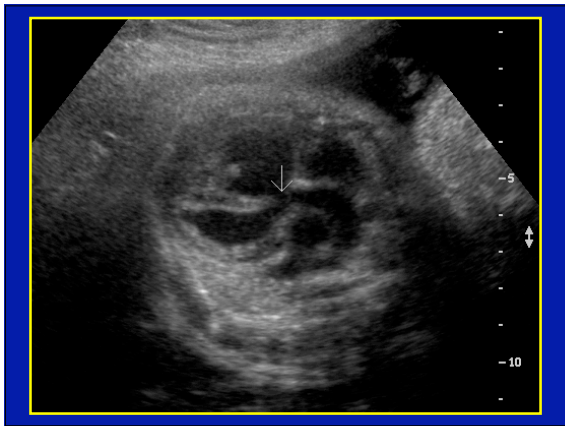
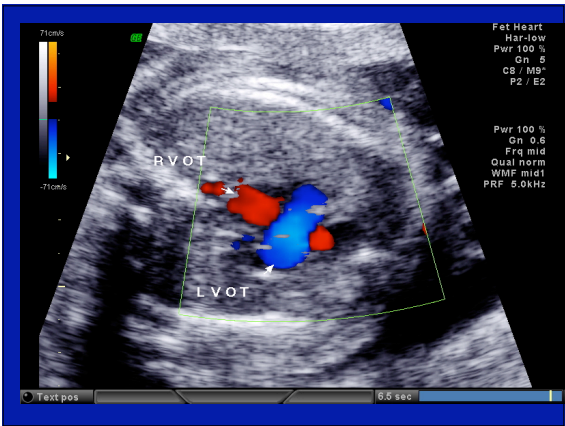
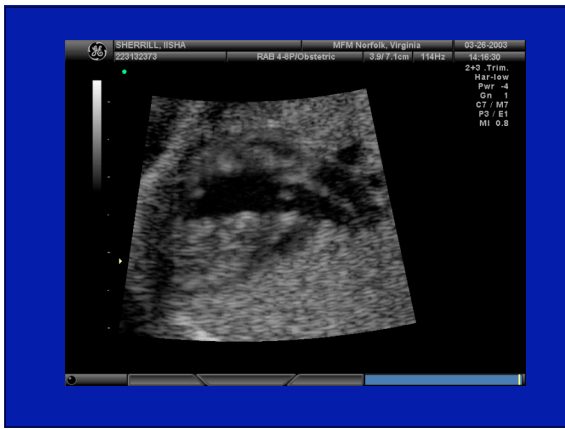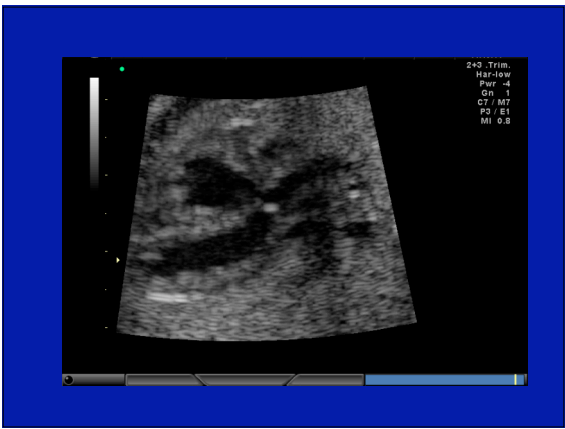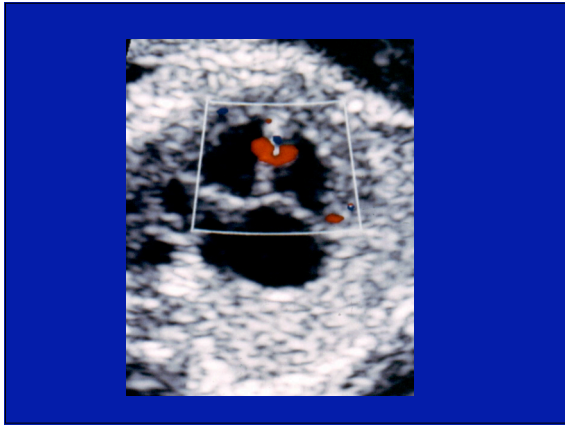
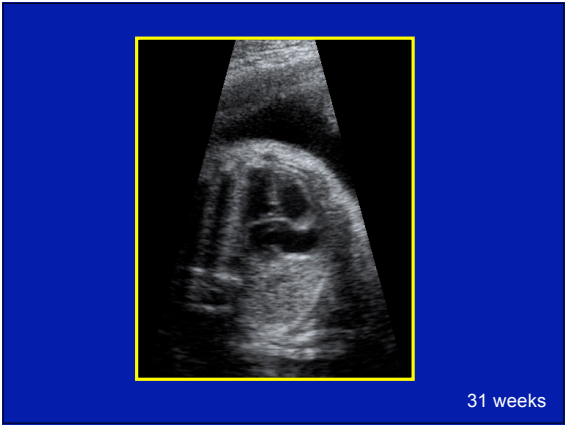
Normal Cardiac Anatomy

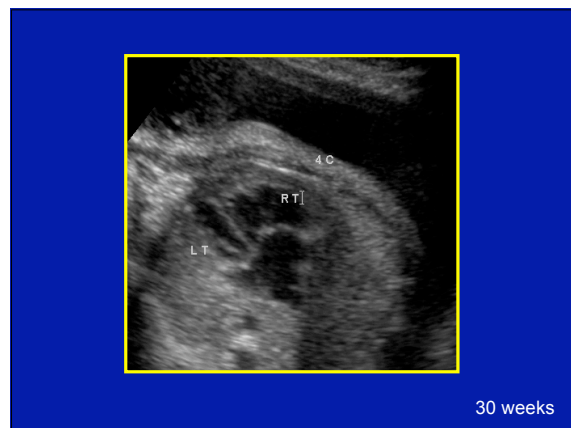
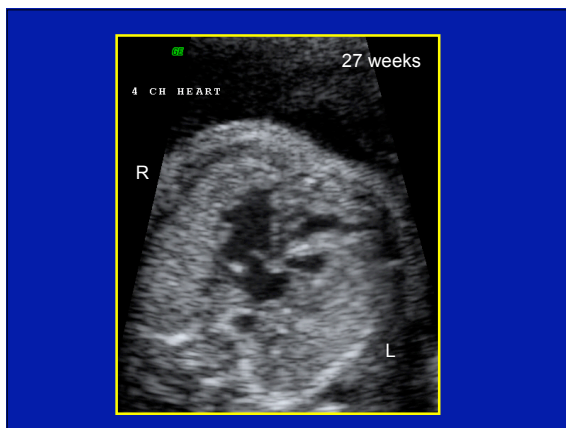
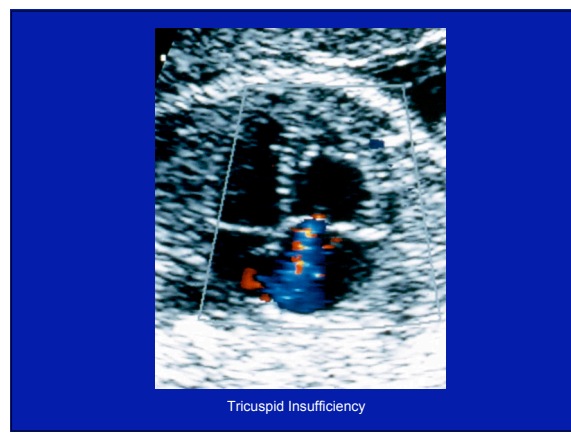
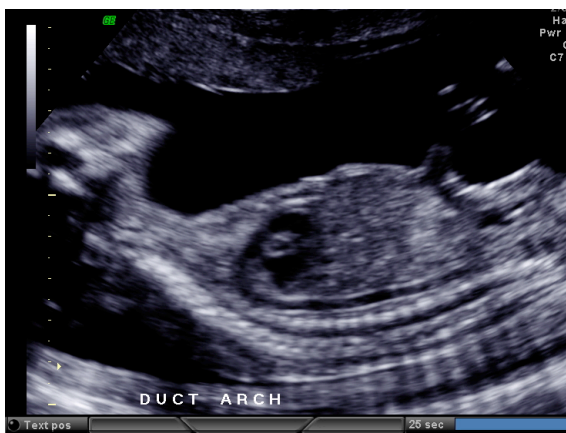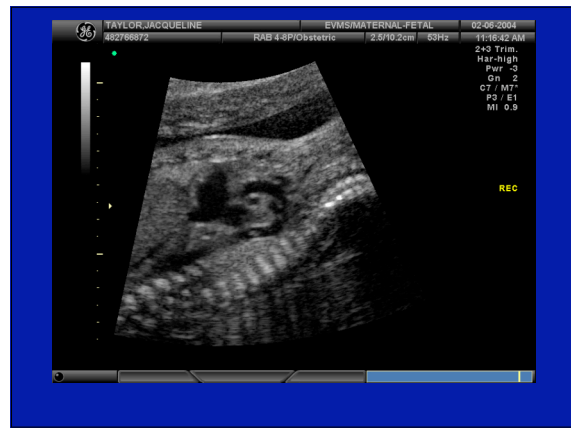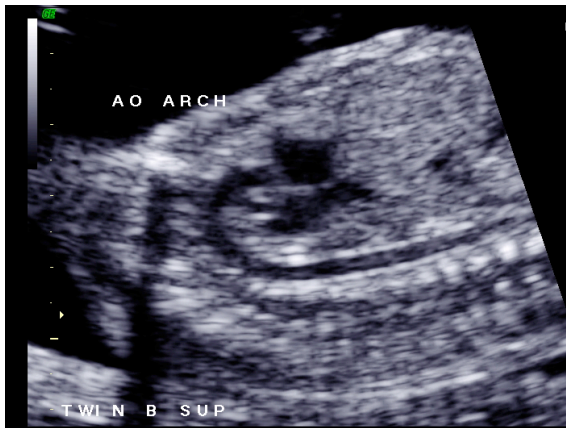




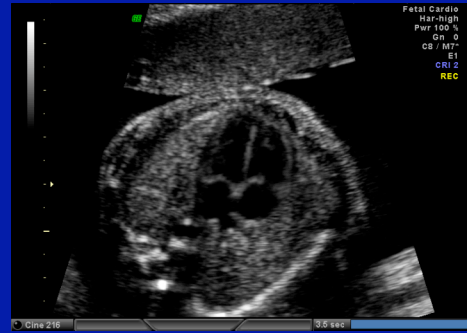
# Septal Defects



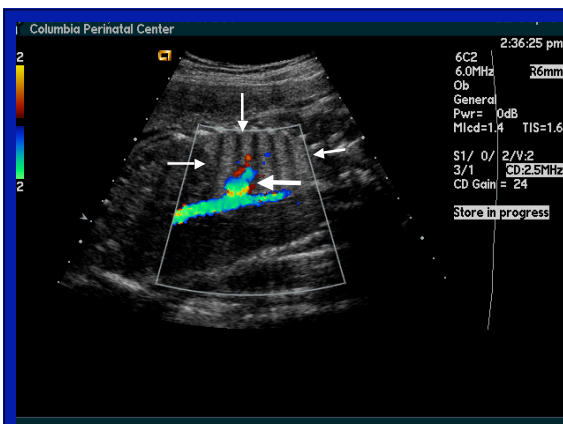
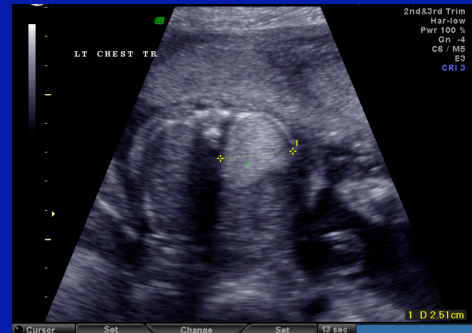




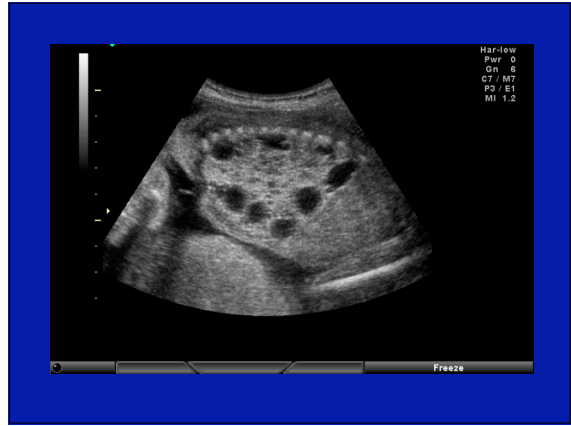
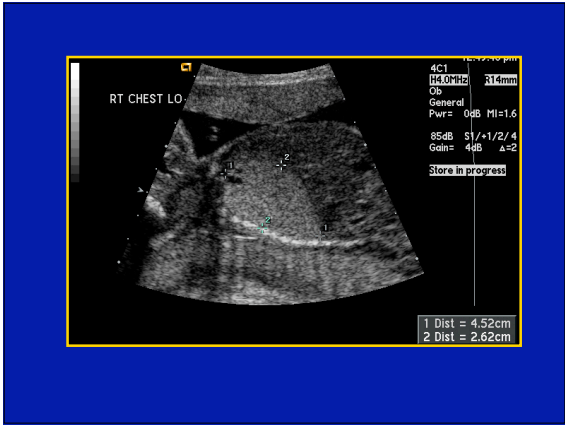# The Lungs



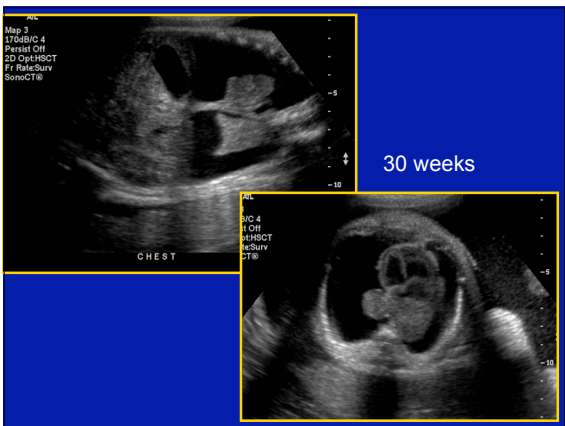
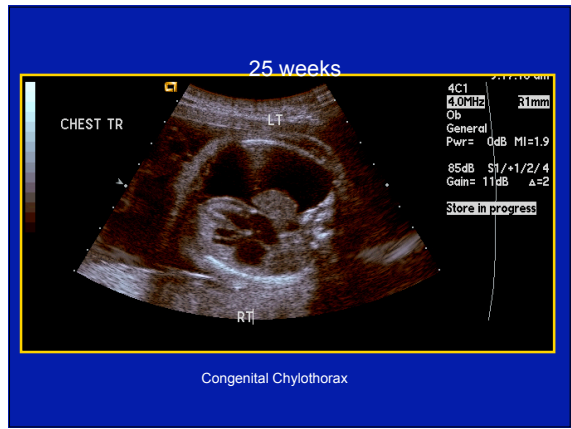# Bronchopulmonary Sequestration



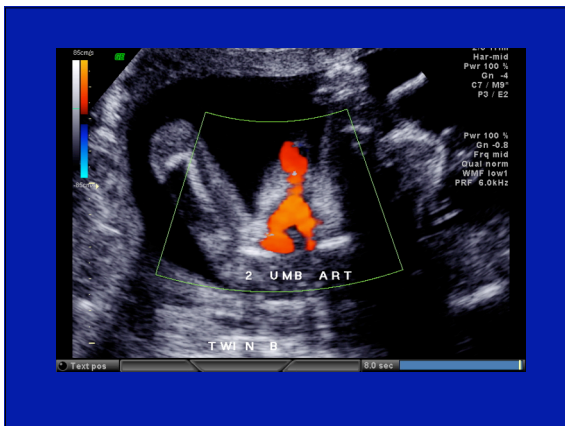
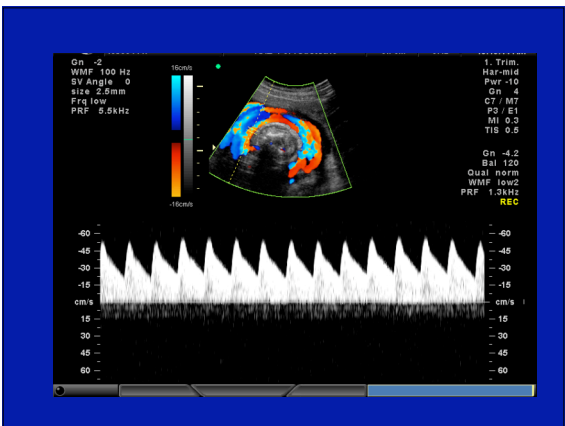
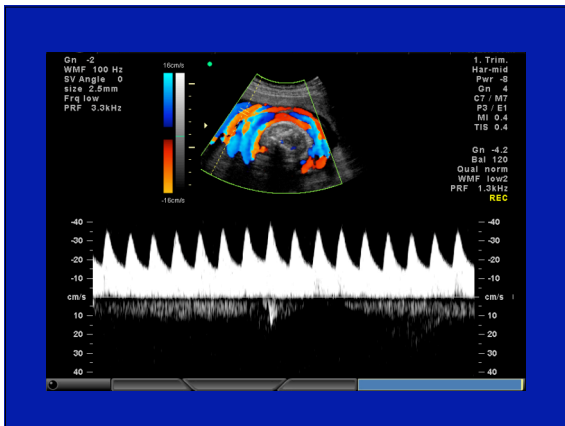
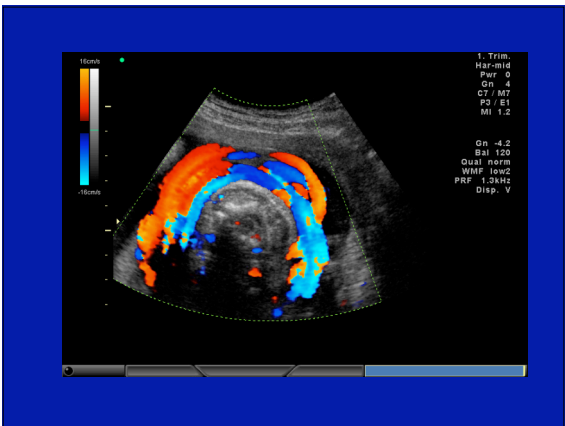
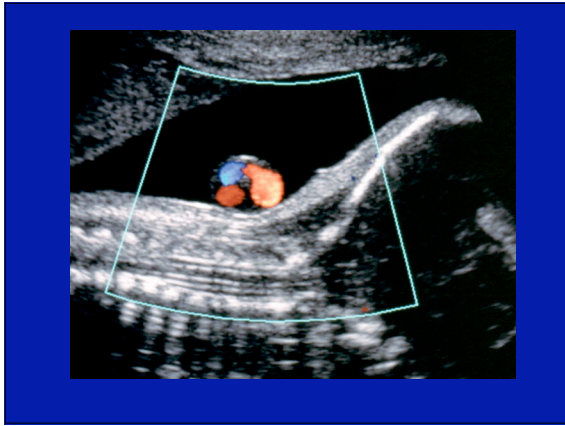
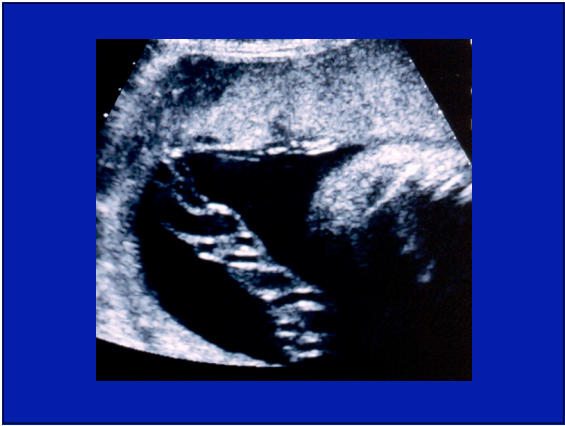# CCAM

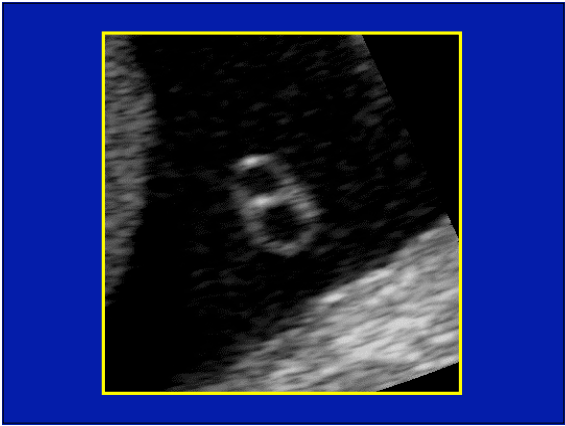


# Fetal Hydrothorax

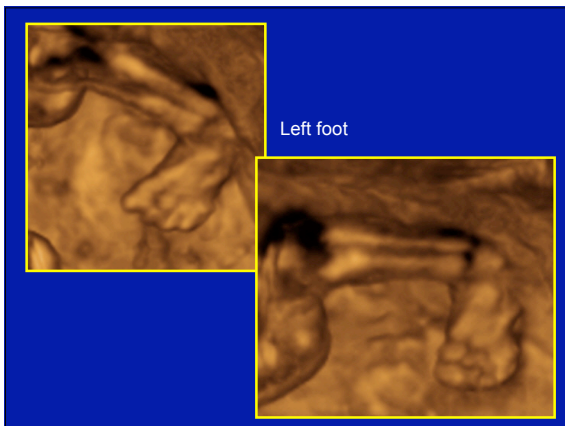
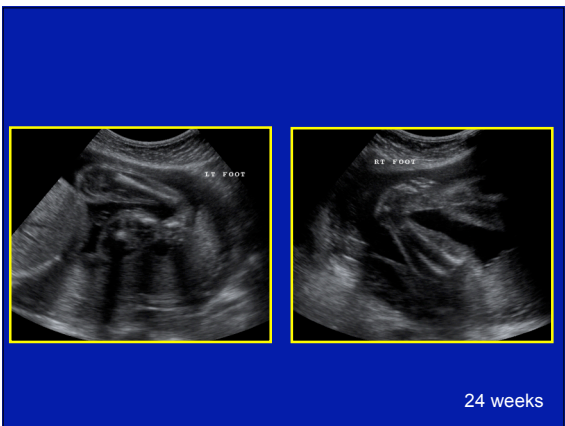
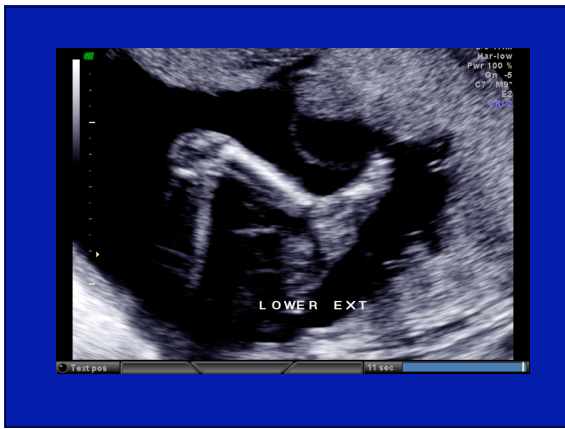
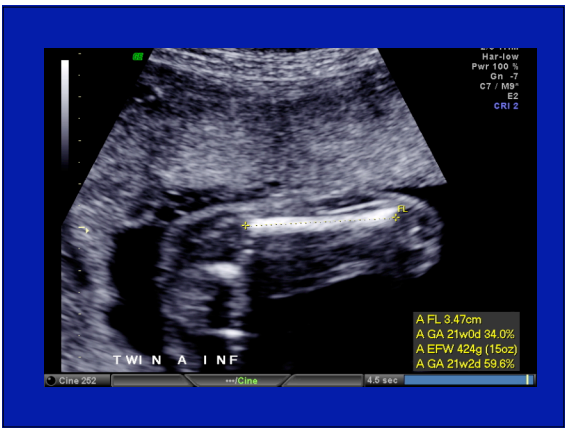
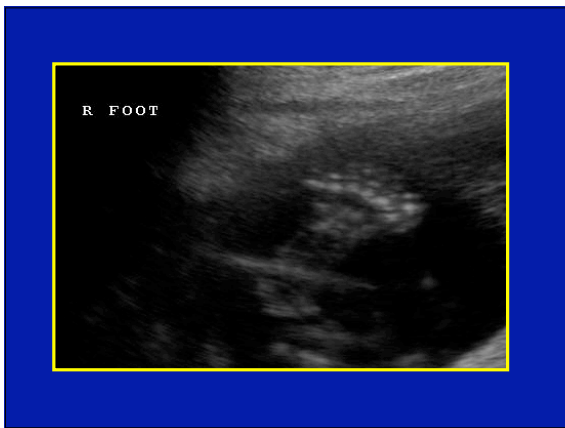
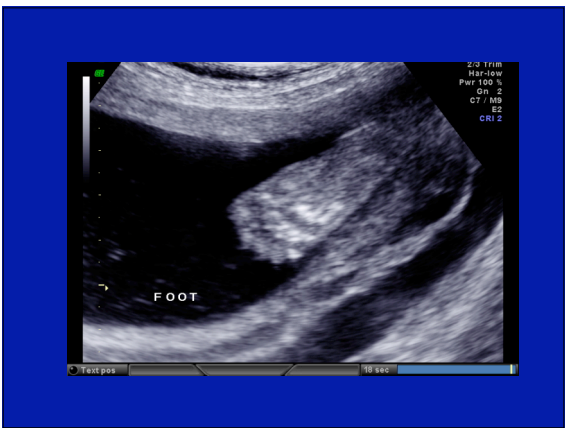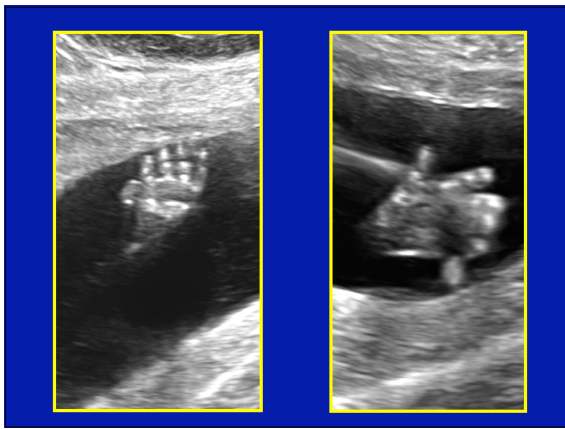
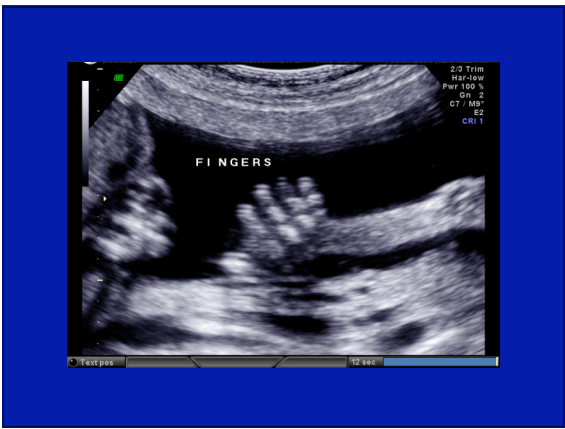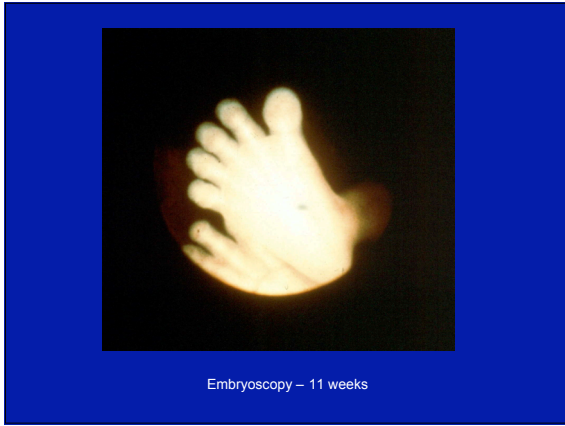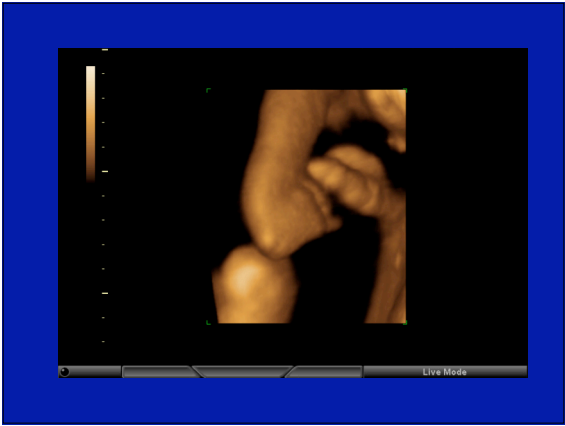
# Cord Problems

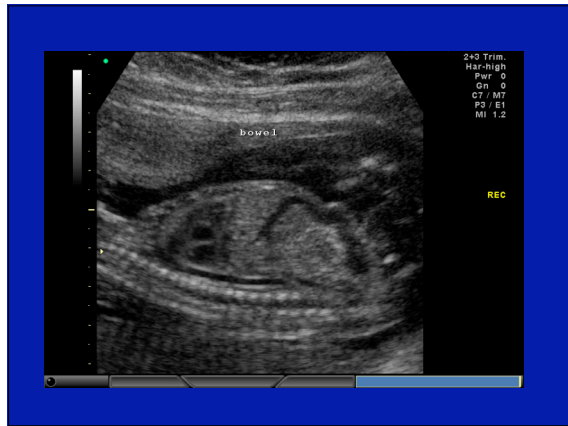
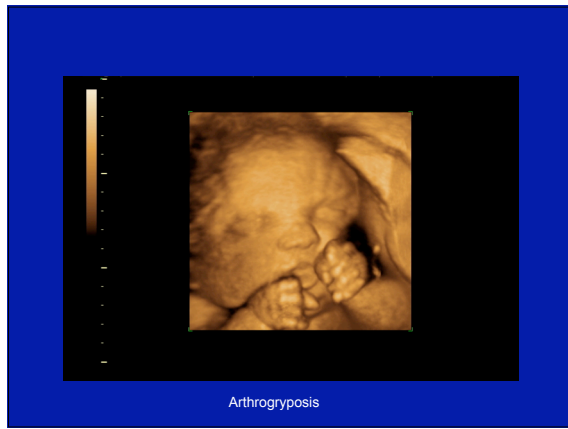
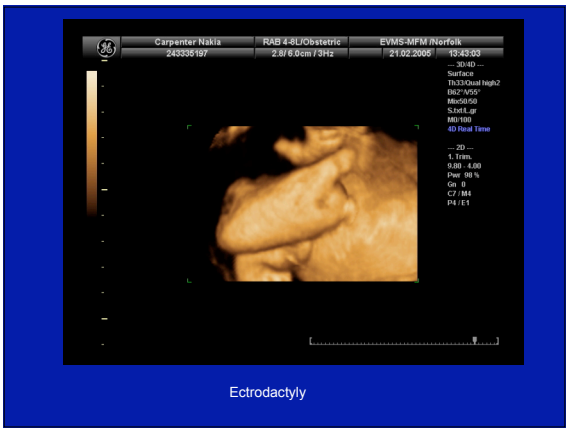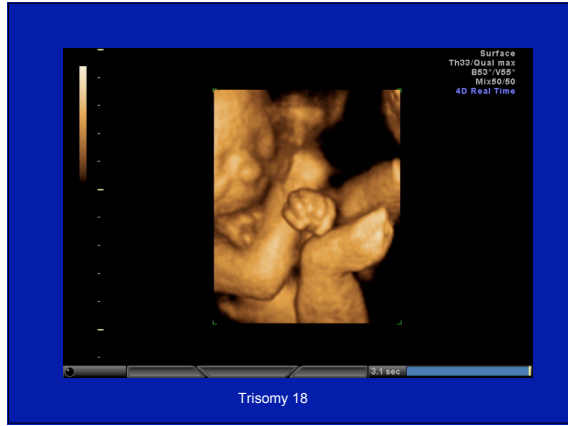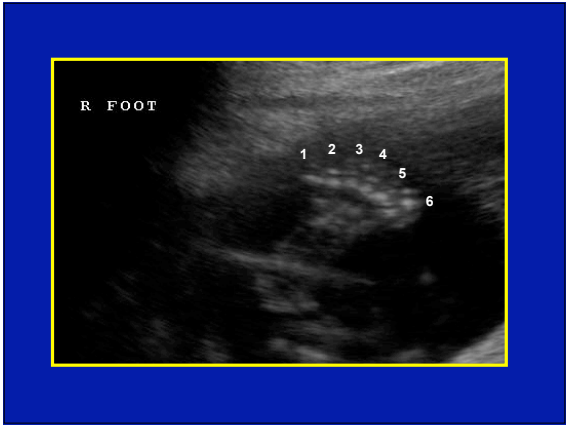


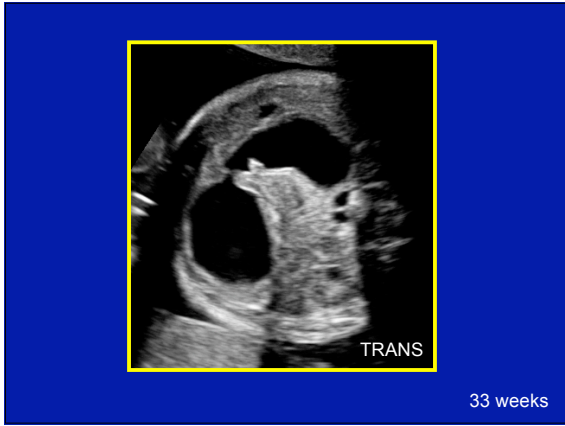


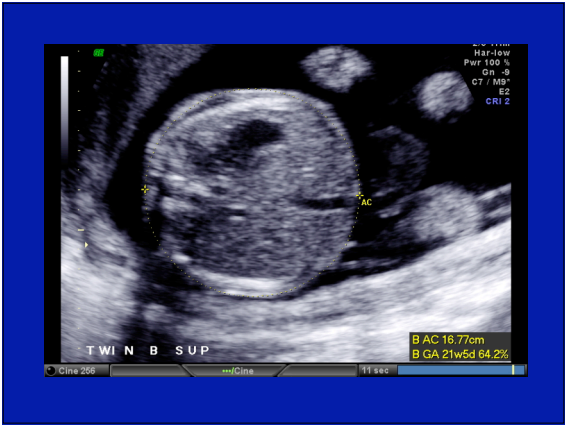# Limbs

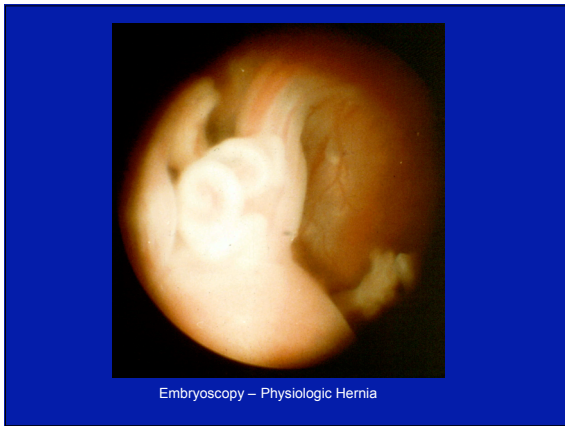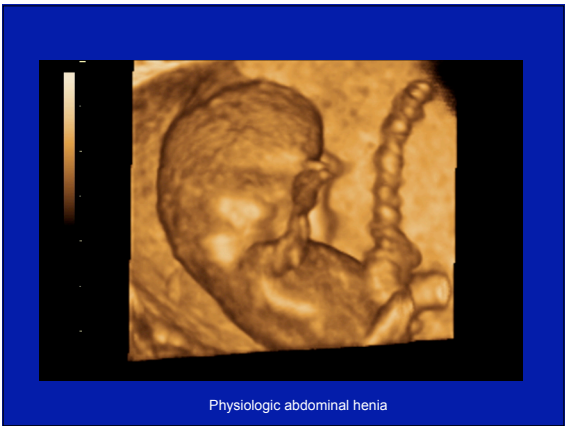
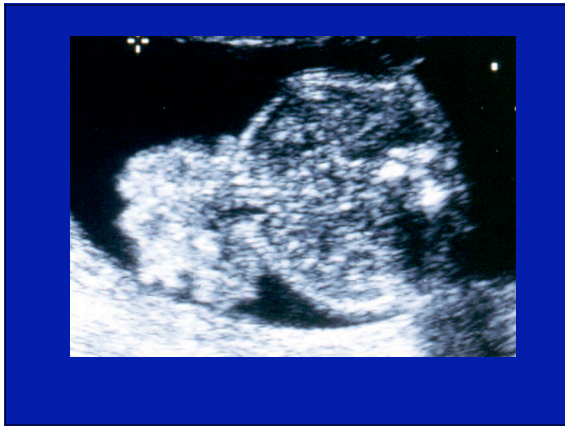

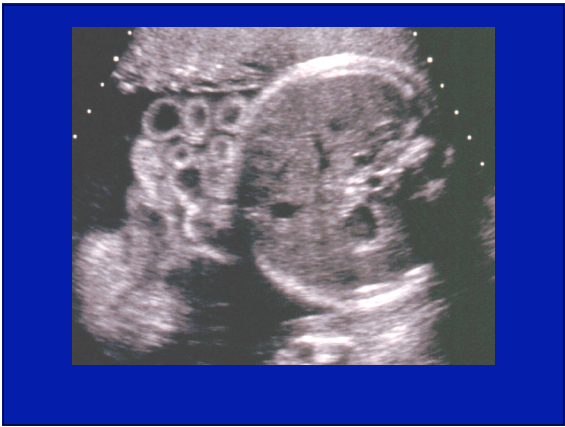
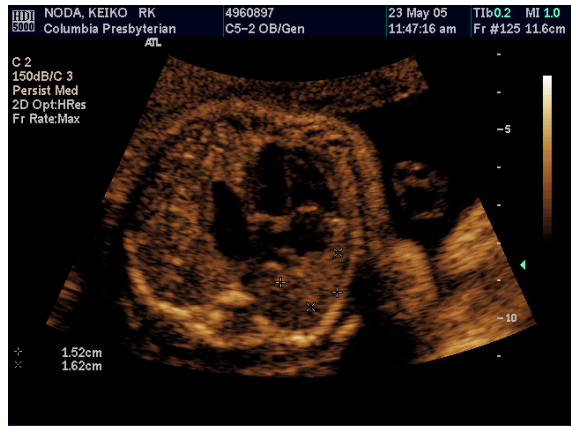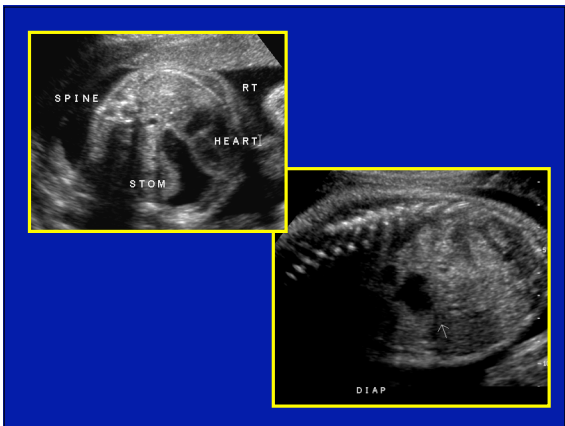
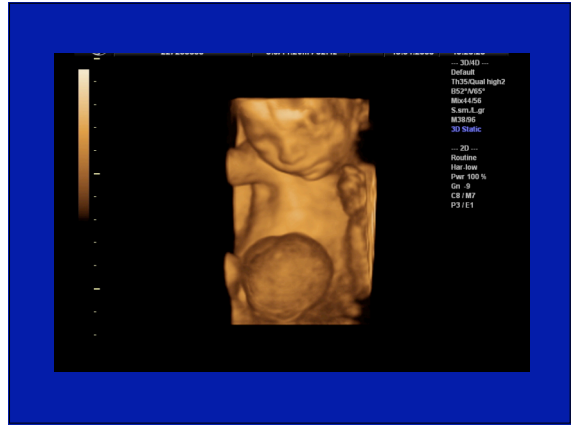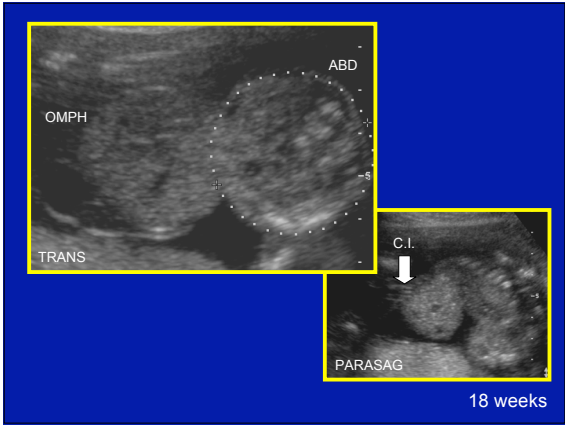




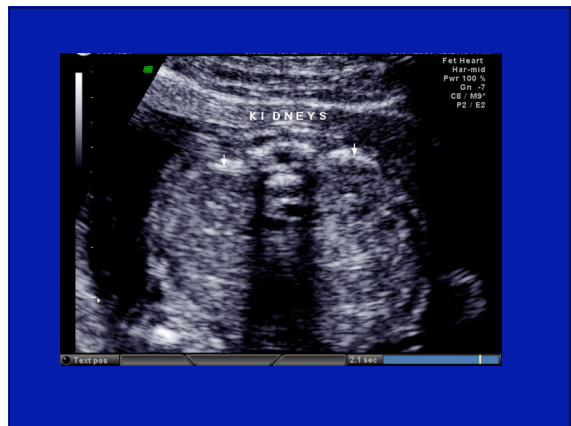


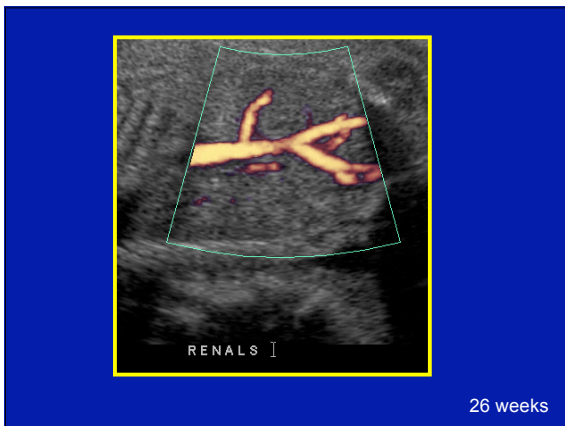
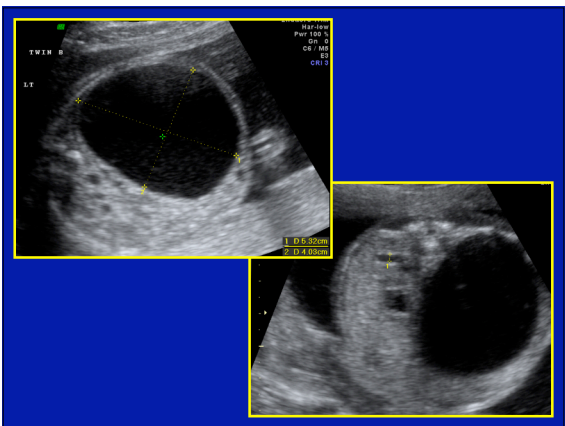
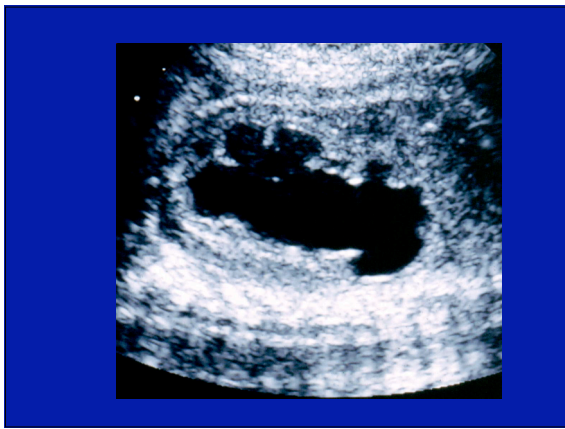
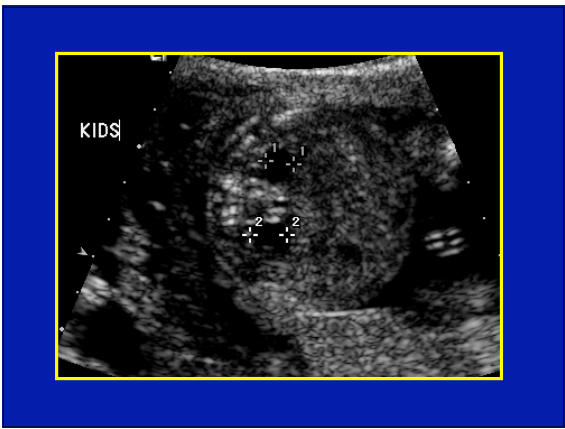
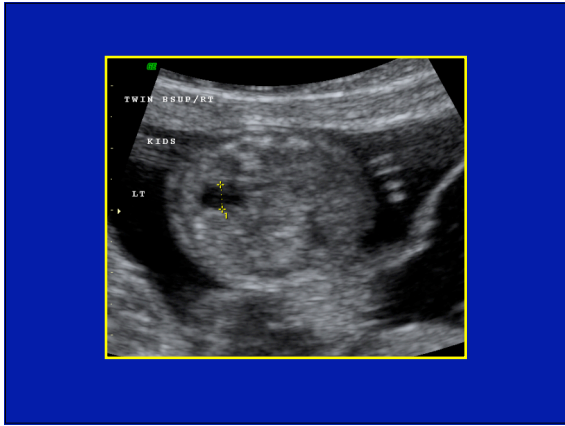
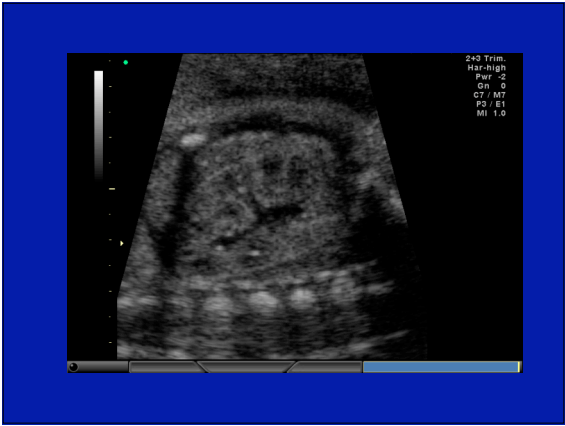
33 weeks

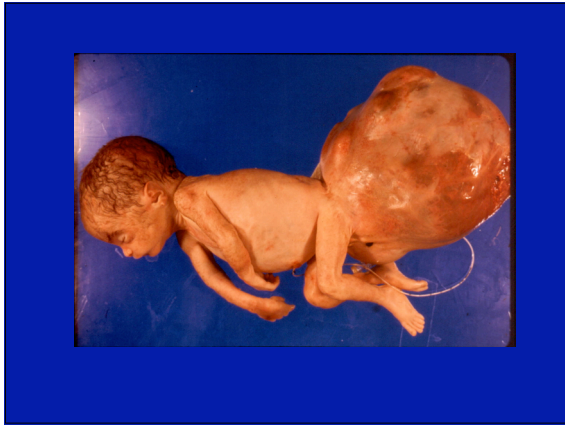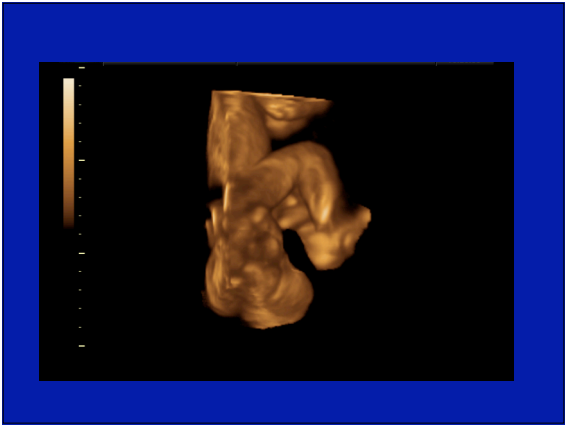




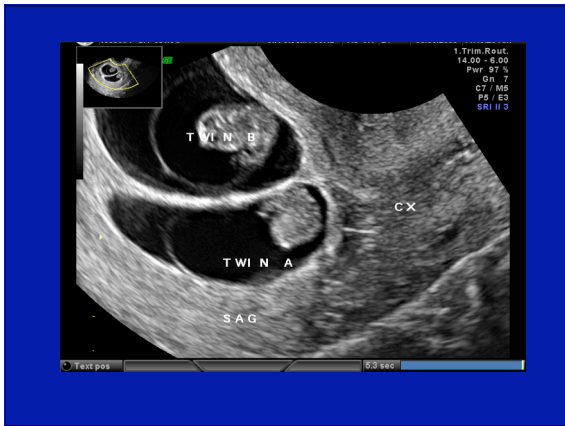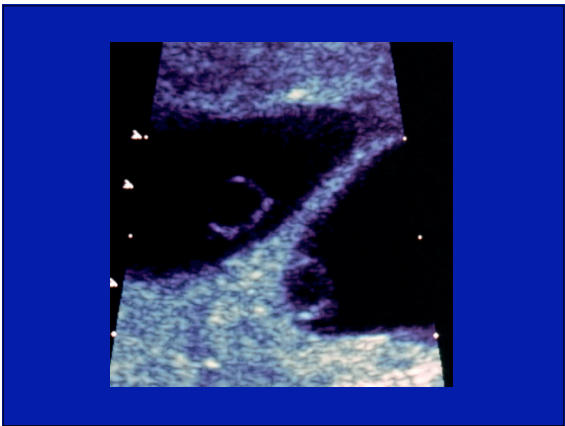
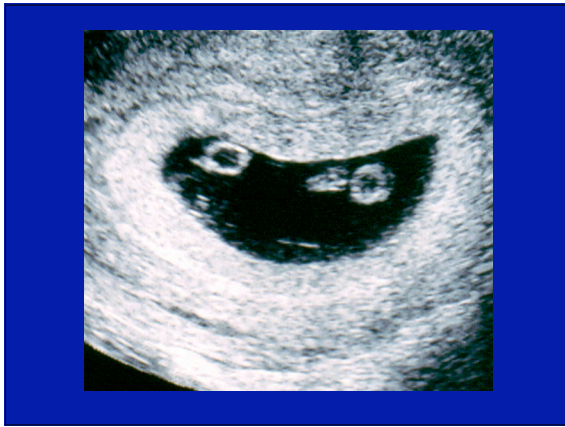GU

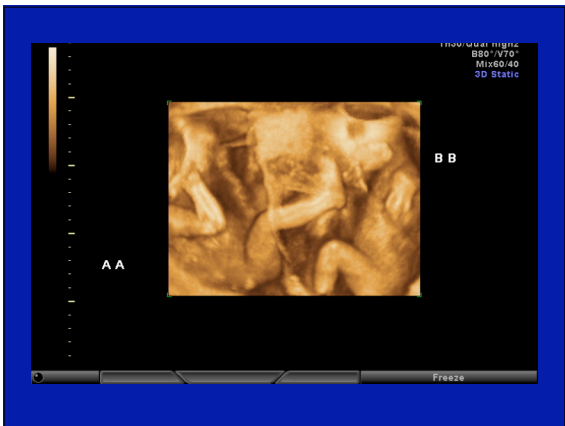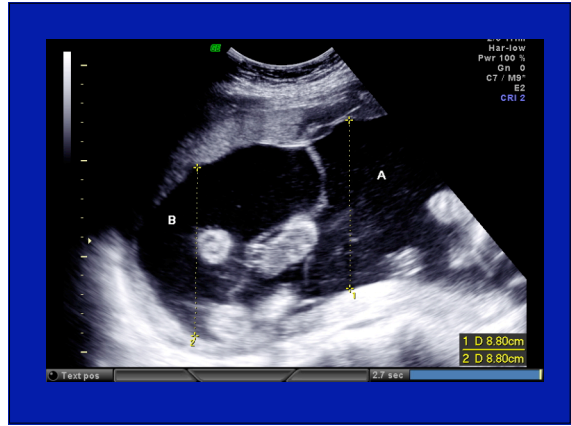

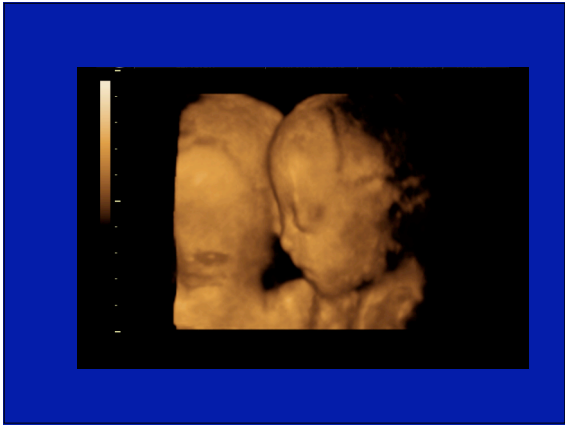




# Multiple Gestation





## Zygosity and Chorionicity

The a priori risk of Down syndrome in a twin pregnancy is based on zygosity.


However, zygosity can only be determined by genetic analysis of both fetuses.

Chorionicity, determined non-invasively by ultrasound, can be used to determine the likelihood of zygosity.

## Dizygotic Pregnancy

Twins resulting from 2 ova fertilized by 2 sperm.

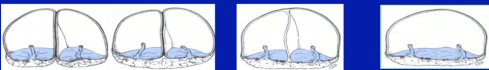
These are ALWAYS dichorionic


 A diagram showing two separate placentas and chorions, representing a dichorionic pregnancy. The placentas are shown as two distinct structures, each with its own chorion.

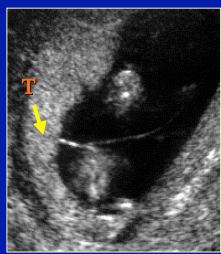
## Monozygotic Pregnancy

One ovum fertilized by one sperm that subsequently splits

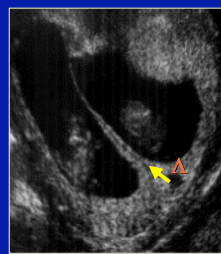
<4 days	4-7 days	7-15 days
DC/DA	MC/DA	MC/MA
20-30%	70%	2-4%


 Three diagrams illustrating the stages of monozygotic twinning: 1. Two embryos sharing a single chorion and placenta. 2. Two embryos sharing a single chorion but having separate placentas. 3. Two embryos with separate chorions and placentas.

**Diagnosis of Chorionicity**



**Monochorionic**  
Always monozygotic  
70-80% MZ twins



**Dichorionic**  
All DZ twins  
20-30% MZ twins

**TTTS**

