

Teratology

Wendy Chung, MD PhD

Mrs. B

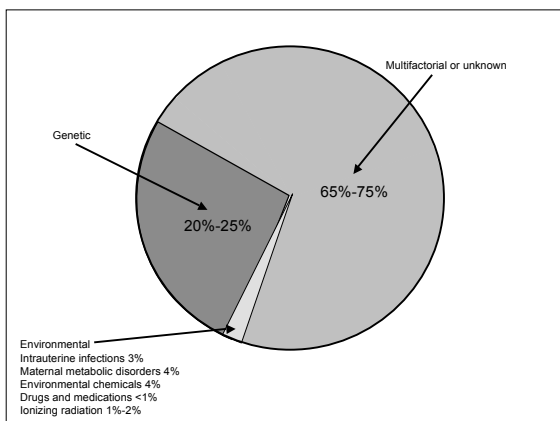
- 30 year old woman comes to you because her 20 week prenatal ultrasound showed a hole in the heart
- Patient and her husband have many questions:
 - What caused this birth defect?
 - Was it caused by the glass of wine she had before she found out she was pregnant?
 - Will there be other problems for this child?
 - If they have other children, what is the risk of recurrence?

Teratology

- The study of abnormal development in embryos and the causes of congenital malformations or birth defects

Birth Defects

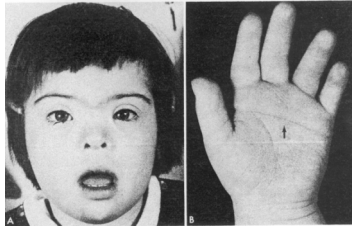
- Observed in 3% of newborns
- Observed in another 3% of children later
- May or may not be outwardly visible
- Etiology: genetic and environmental



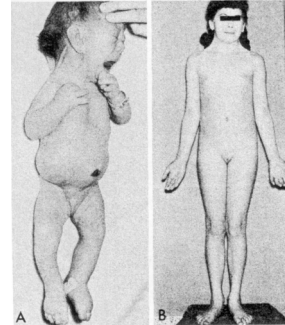
Major and Minor Anomalies

- Major anomalies: life/health threatening
- Minor anomalies: cosmetic
- The greater the number of minor anomalies, the greater the likelihood of a major anomaly
- Certain minor anomalies suggest specific major anomalies

Down Syndrome



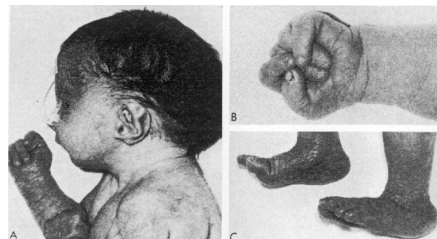
Turner Syndrome



Trisomy 13

- Midline defects (cleft lip and cleft palate)
- Central nervous system malformations
- Micro-ophthalmia
- Congenital heart disease
- Poor growth

Trisomy 18



Mrs. B

- Extensive ultrasound examination does not identify other major anomalies
- Can minor anomalies be excluded?
- An amniocentesis is performed and is normal
- Are genetic etiologies excluded?

Inborn Errors of Metabolism Causing Birth Defects

- Smith Lemli Opitz
- Congenital disorders of glycosylation
- Fatty acid oxidation disorders

Effect of Exposure Depends on Timing

- All or none effect early
- Effect of organogenesis during embryonic development
- Effect on size and function during fetal development

| Teratogens | Congenital Malformations |
|--|---|
| Androgenic Agents | Varying degrees of masculinization of female fetuses; ambiguous external genitalia caused by fetal testosterone. |
| Ethionone | |
| Neochlorogenic | |
| Tenoxicam | |
| Drugs and Chemicals | |
| Alcohol | Fetal alcohol syndrome: intrauterine growth retardation (IUGR); mental retardation; microcephaly; ocular anomalies; joint abnormalities; short palpebral fissures. |
| Amisoprin | Wide range of skeletal defects, IUGR, malformations of the central nervous system, notably microencephaly (a large part of the brain is absent). |
| Busulfan | Stunted growth, skeletal abnormalities, corneal opacities, cleft palate, hypoplasia of various organs. |
| Phenytoin (Dilantin) | Fetal hydantoin syndrome: IUGR, microcephaly, mental retardation, ridged maxillary suture, inner epicanthic folds, eyelid ptosis, broad depressed nasal bridge, pharyngeal hypoplasia. |
| Lithium carbonate | Various malformations, usually involving the heart and great vessels. |
| Methotrexate | Multiple malformations, especially skeletal, involving the face, skull, limbs, and vertebral column. |
| Large doses of retinoic acid (vitamin A) | Facial abnormalities; neural tube defects, such as spina bifida cystica (see Fig. 18-14). |
| Tetracycline | Stained teeth, hypoplasia of enamel. |
| Trimethadione | Developmental delay, V-shaped eyebrows, low-set ears; cleft lip and/or palate. |
| Infectious Agents | |
| Cytomegalovirus | Microcephaly, hydrocephaly, microphthalmia, micrognathia, mental retardation, cerebral calcifications. |
| Herpes simplex virus | Microcephaly, microphthalmia, retinal dysplasia. |
| Rubella virus | Cataracts, glaucoma, choroideritis, deafness, microphthalmia, congenital heart defects. |
| Varicella | Skin scarring; muscle atrophy; mental retardation. |
| Venezuelan equine encephalitis | Cataracts, brain destruction. |
| Cryptosporidium parvum | Microcephaly; mental retardation; microphthalmia; hydrocephaly; choroideritis; cerebral calcifications. |
| Toxoplasma pallidum | Hydrocephalus; congenital deafness, mental retardation; abnormal teeth and bones. |
| High levels of ionizing radiation | Microcephaly; mental retardation; skeletal malformations. |

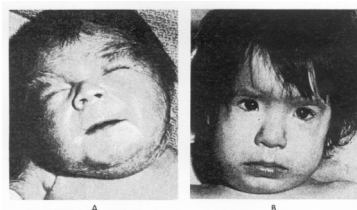
Nicotine

- IUGR
- Premature delivery
- Neurocognitive development

Fetal Alcohol Syndrome

- Characteristic facial features
- Congenital heart disease
- Growth deficiency
- Behavioral/neurocognitive deficits

Fetal Alcohol Syndrome



Mrs. B

- Do you believe her fetus' congenital heart disease was caused by the glass of wine she drank two weeks after conception?

Tetracycline

- Yellow/brown teeth
- Decreased bone growth

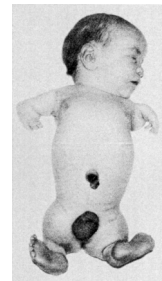Fetal Hydantoin Syndrome

- Intrauterine growth retardation
- Microcephaly, mental retardation
- Distal phalangeal hypoplasia
- Specific facial features

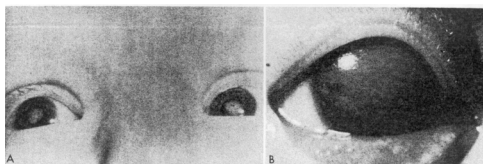
Retinoic acid

- Craniofacial dysmorphism
- Cleft palate
- Thymic aplasia
- Neural tube defects

Thalidomide Syndrome



Congenital Rubella



Congenital CMV

- Intrauterine growth retardation
- Micromelia
- Chorioretinitis, blindness
- Microcephaly
- Cerebral calcifications, mental retardation
- Hepatosplenomegaly

Ionizing Radiation

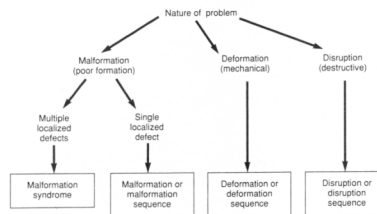
- Affects brain development at 10-18 weeks of gestation a HIGH dose
- No evidence of effect of exposure associated with typical diagnostic studies

Maternal Hyperglycemia

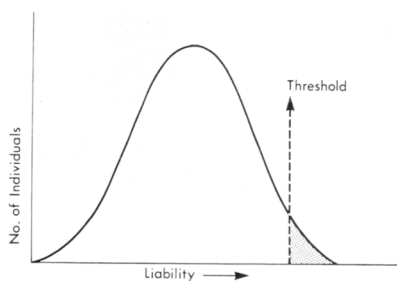
- Congenital heart disease
- Renal, gastrointestinal, and central nervous system malformations such as neural tube defects

Babies of Mother's with PKU

- Mental retardation
- Low birth weight
- Congenital heart diseases



Threshold Effect-Multifactorial



Mrs. B

- After birth, the newborn examination is unremarkable
- The baby's congenital heart disease is repaired
- At age three, the child is growing well and has met all his milestones

- What caused his congenital heart disease?
- What is the risk of recurrence for a future sibling?