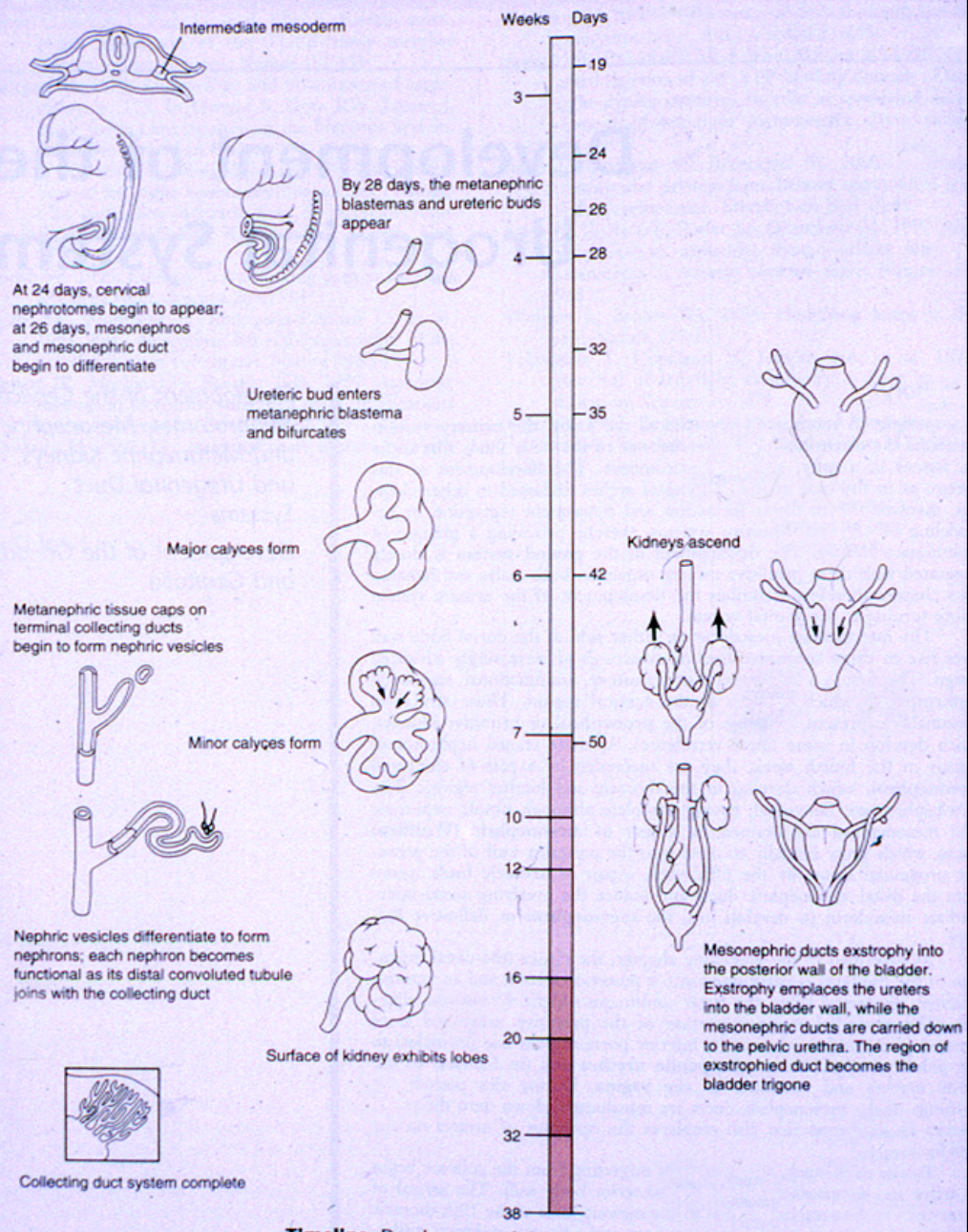
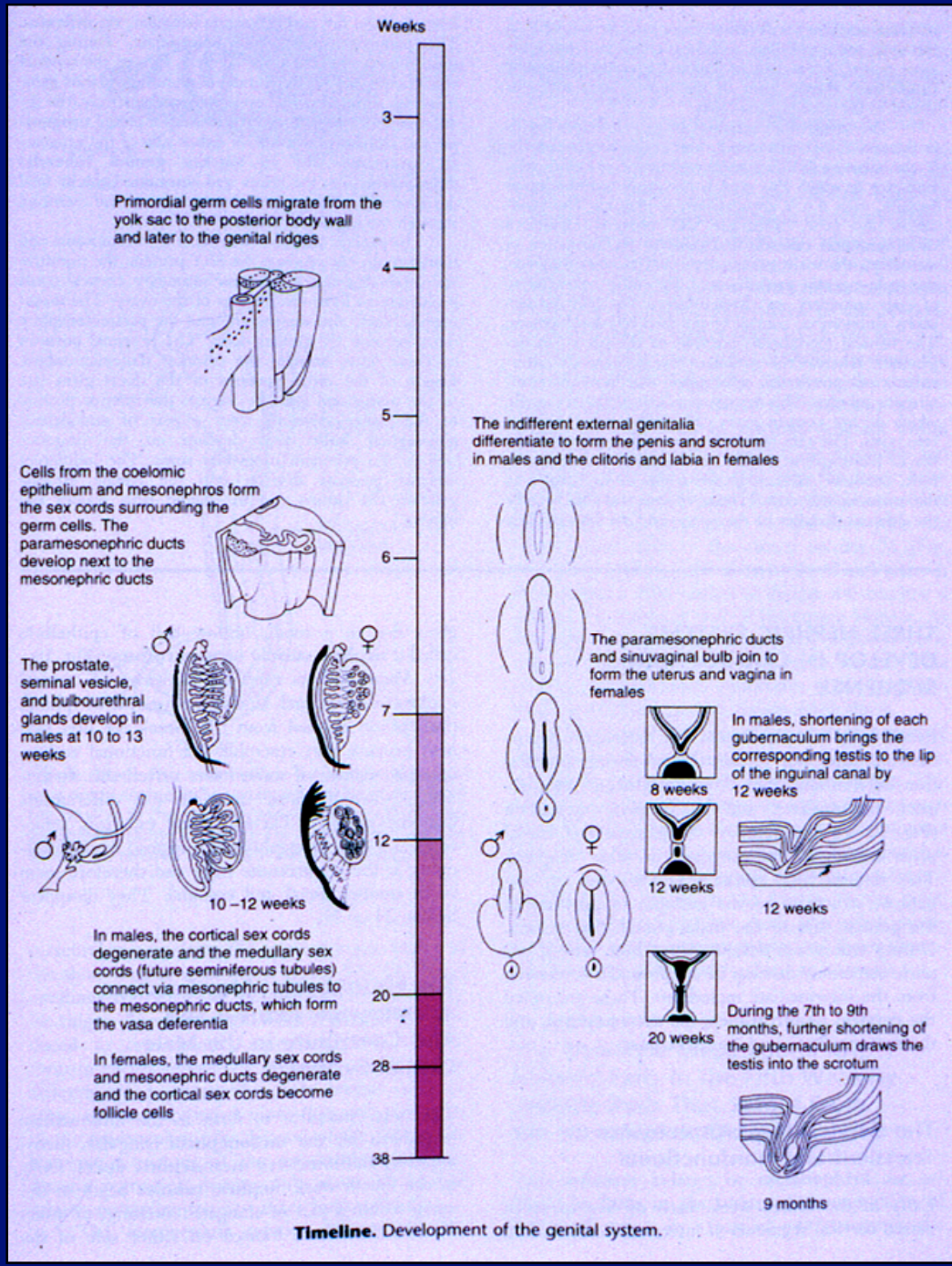


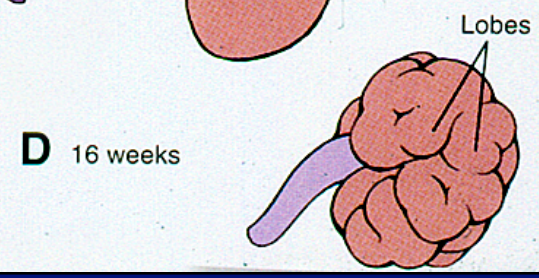
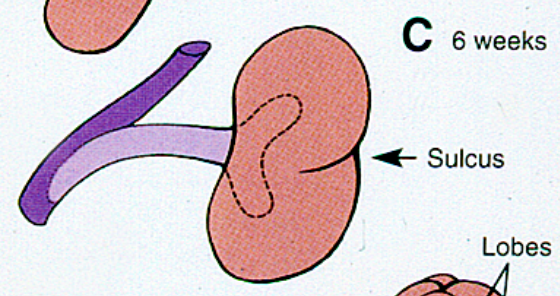
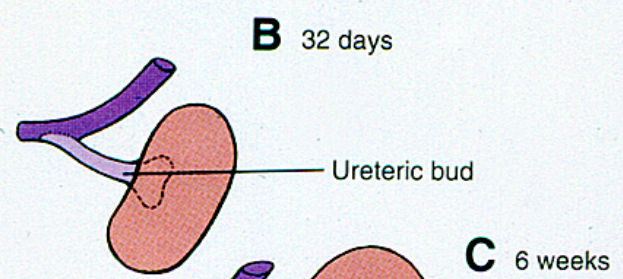
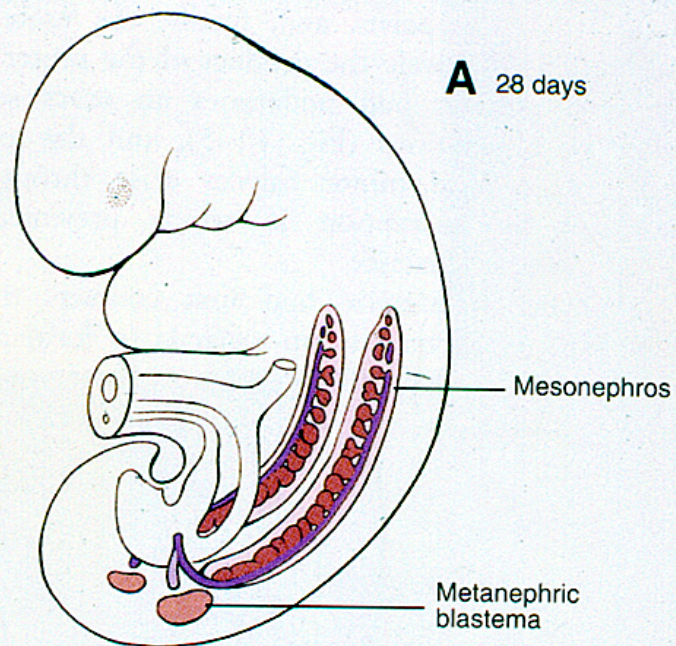


***Normal Development***



**Timeline.** Development of the urinary system.





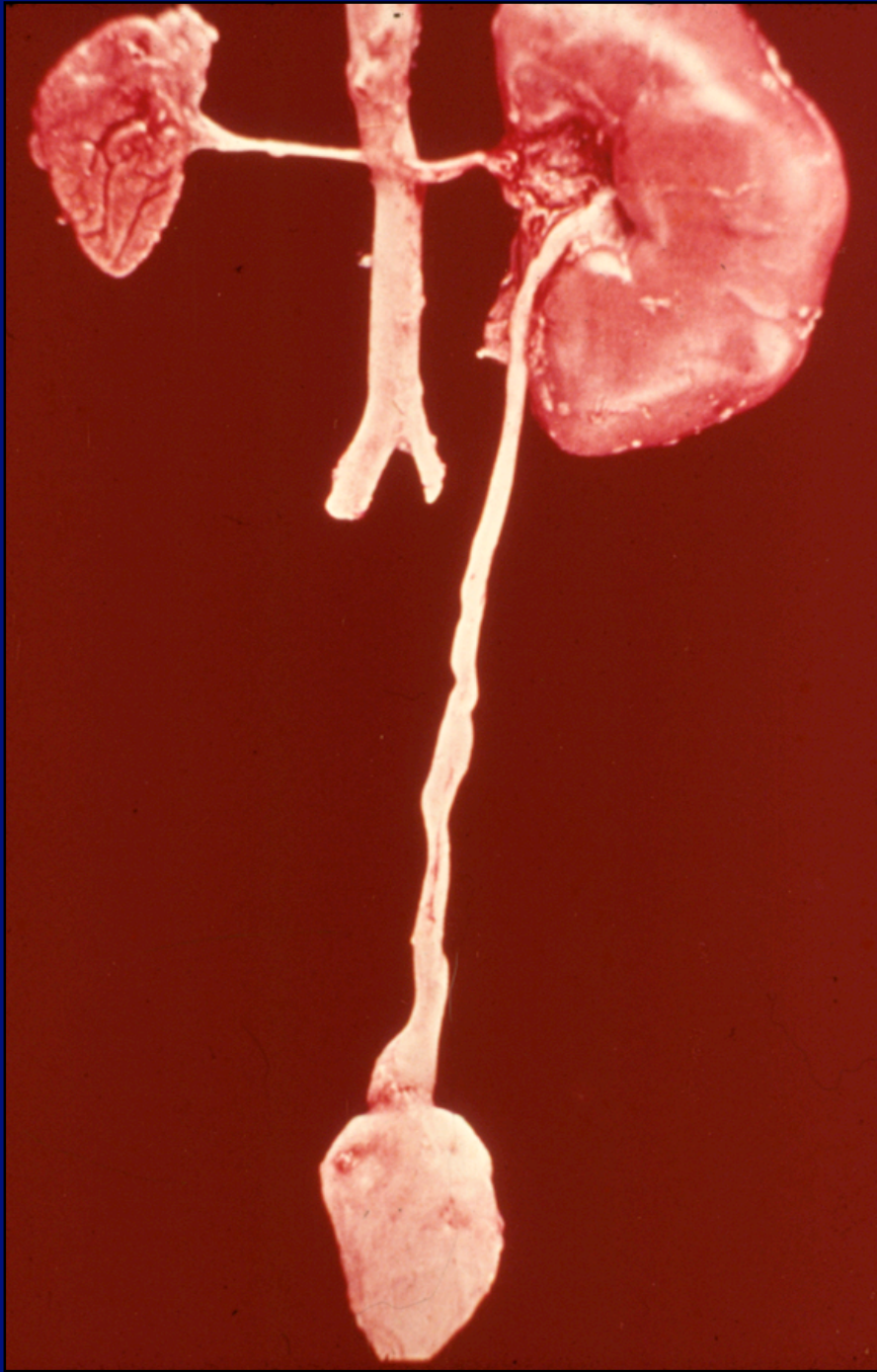
# RENAL DEVELOPMENT

- WT-1 Gene located at 11p13 the “master switch” for gonadal development and renal morphogenesis
- GDNF Glial derived neurotropic factor implicated prominently in renal morphogenesis
- RET receptor tyrosine kinase is the receptor for GDNF and WT-1 at ureteral bud

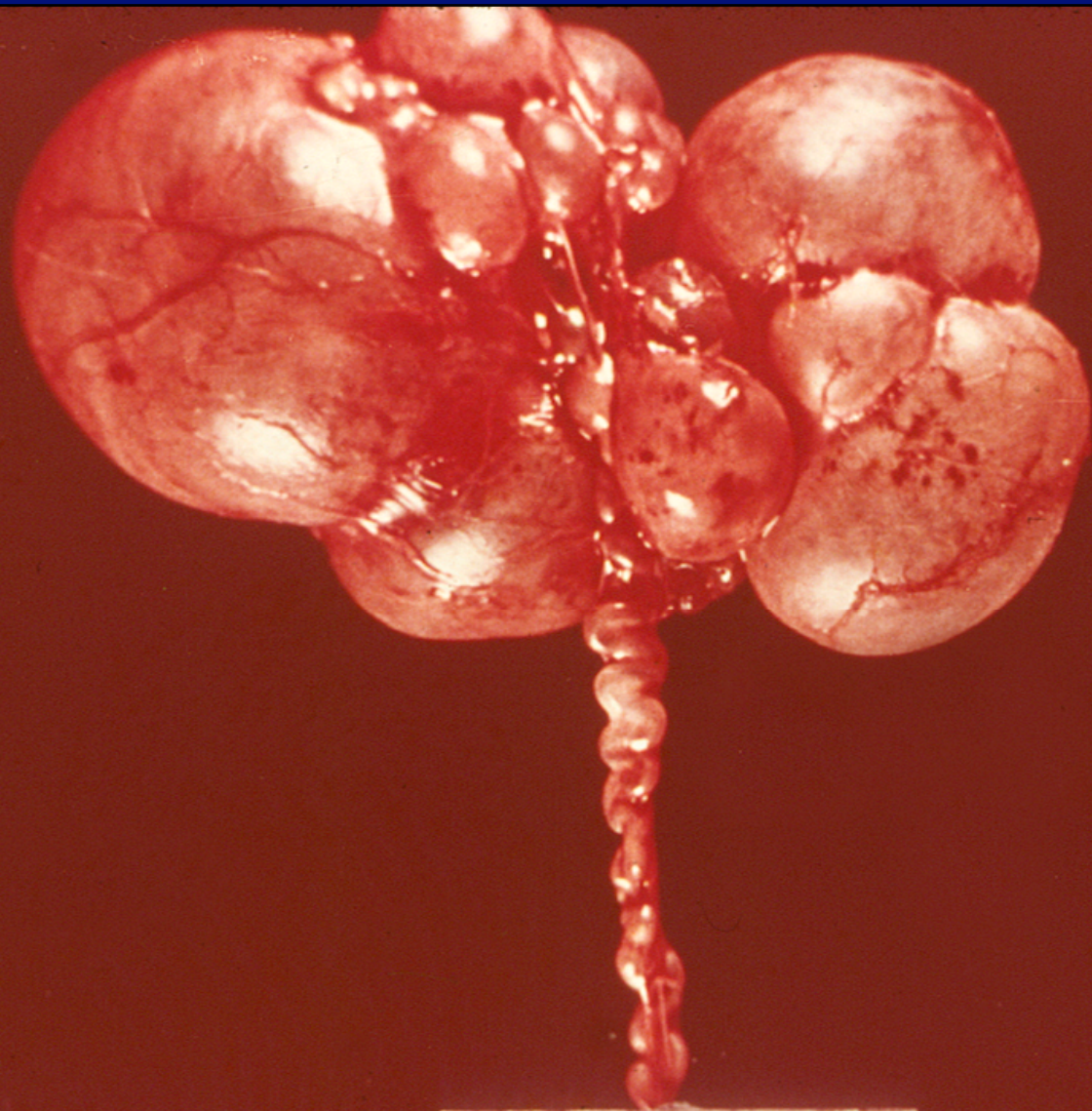
# RENAL DEVELOPMENT

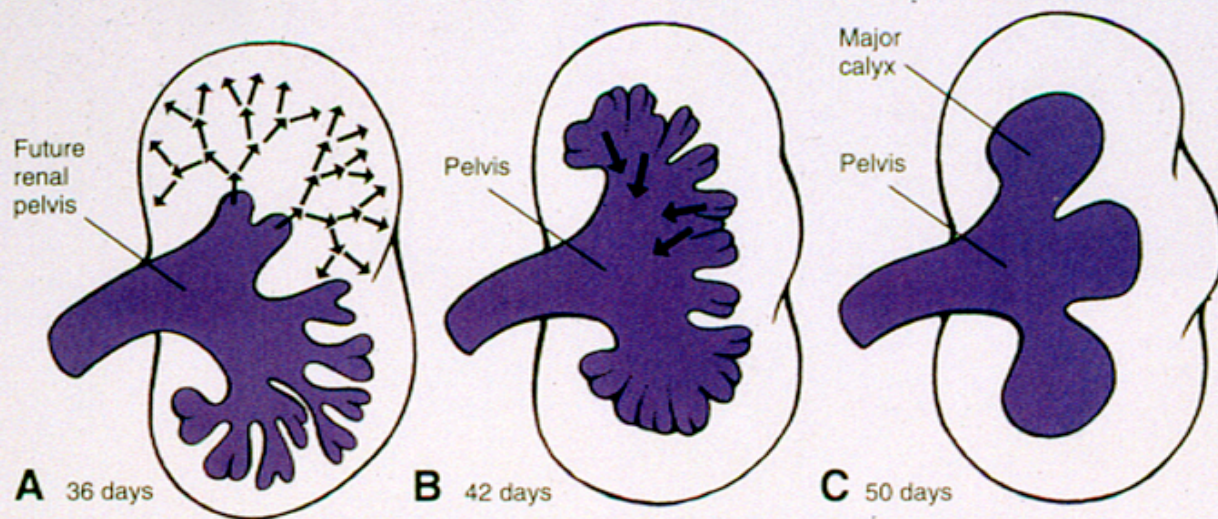
- BOTH WT-1 AND GDNF ARE NEEDED IN THE METANEPHRIC BLASTEMA FOR INDUCTION OF THE URETERAL BUD
- RET ENABLES GDNF AND WT ACTION AT THE URETERAL BUD

***Renal Agenesis  
(? WT-1 FAILURE)***



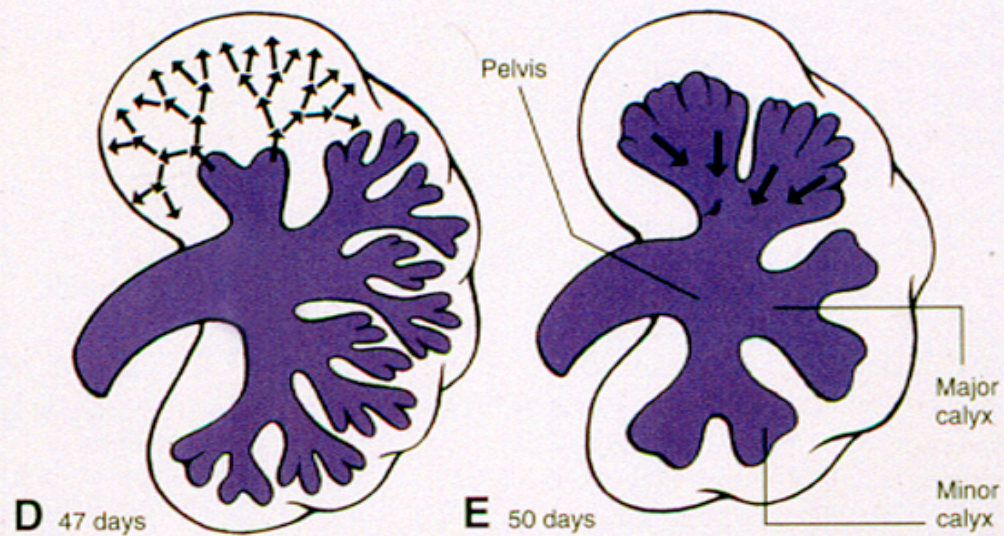
***Multicystic Kidney  
(? RET FAILURE)***





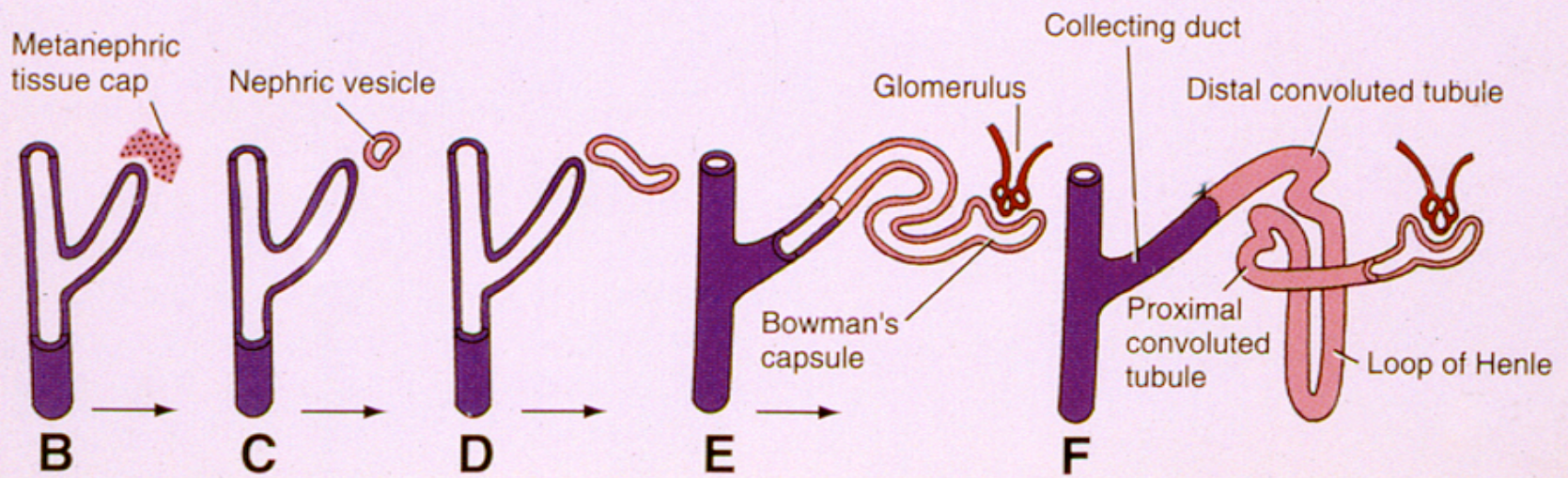
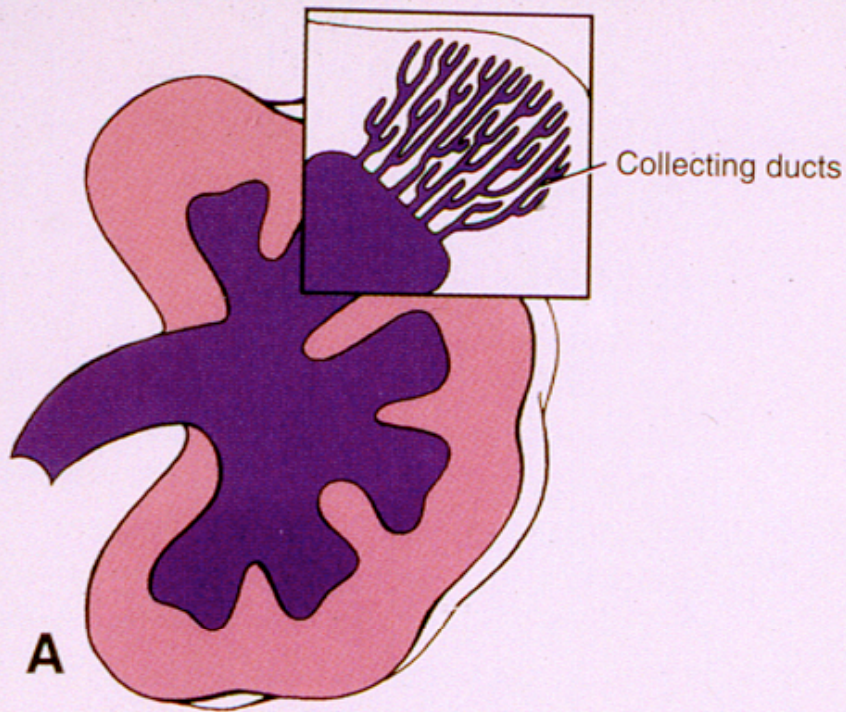
← Four generations of bifurcations →

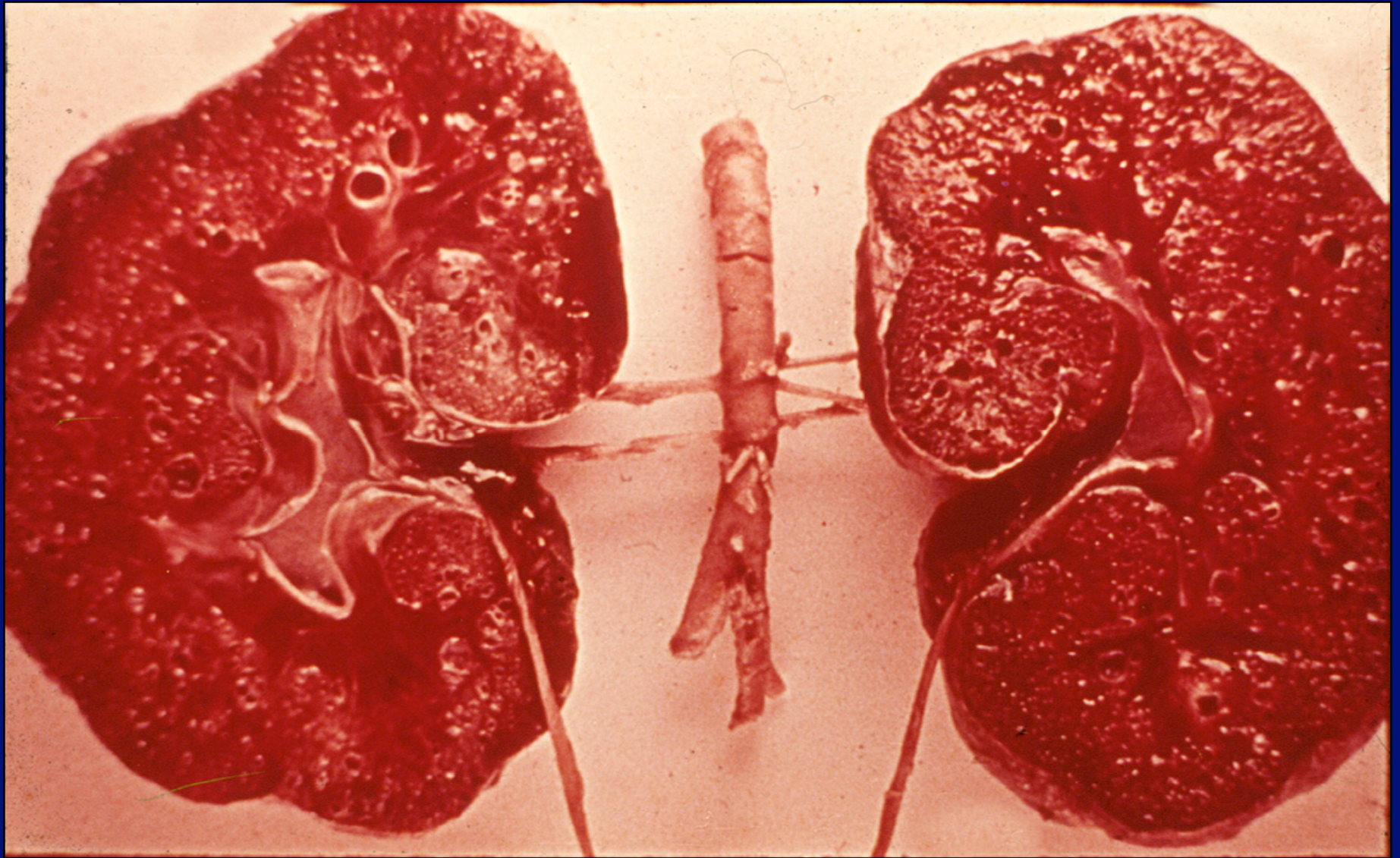
← Resorption →



← Branchings →

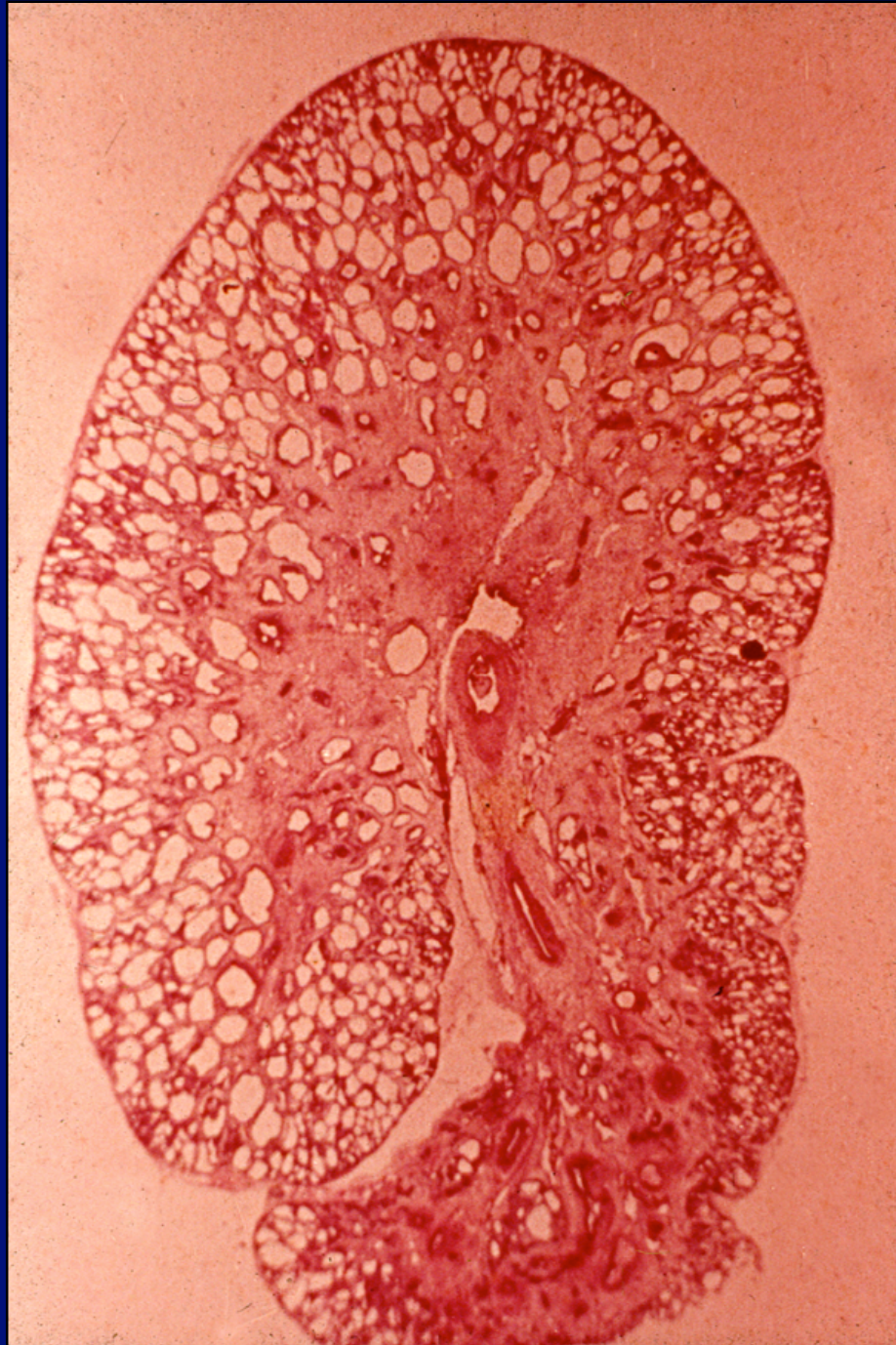
← Resorption →

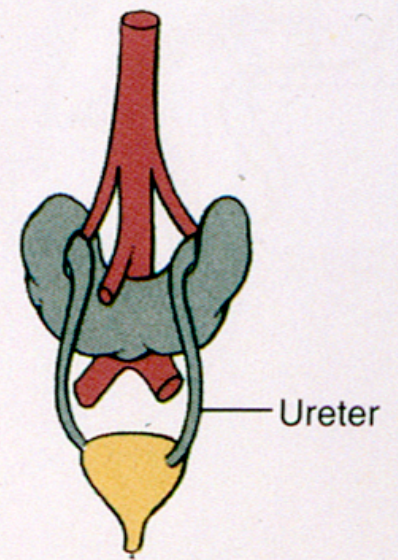
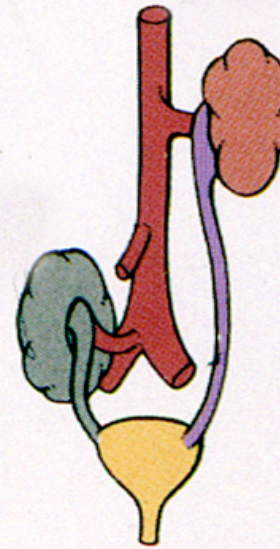
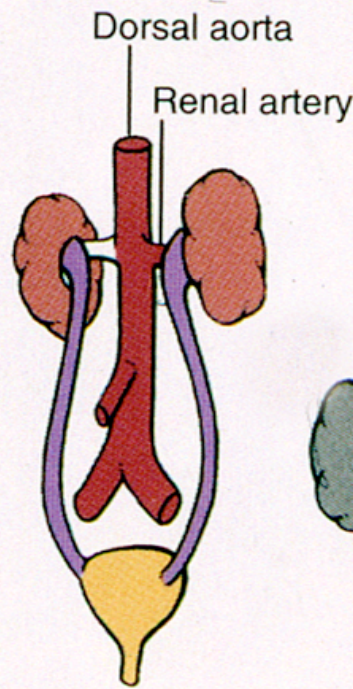
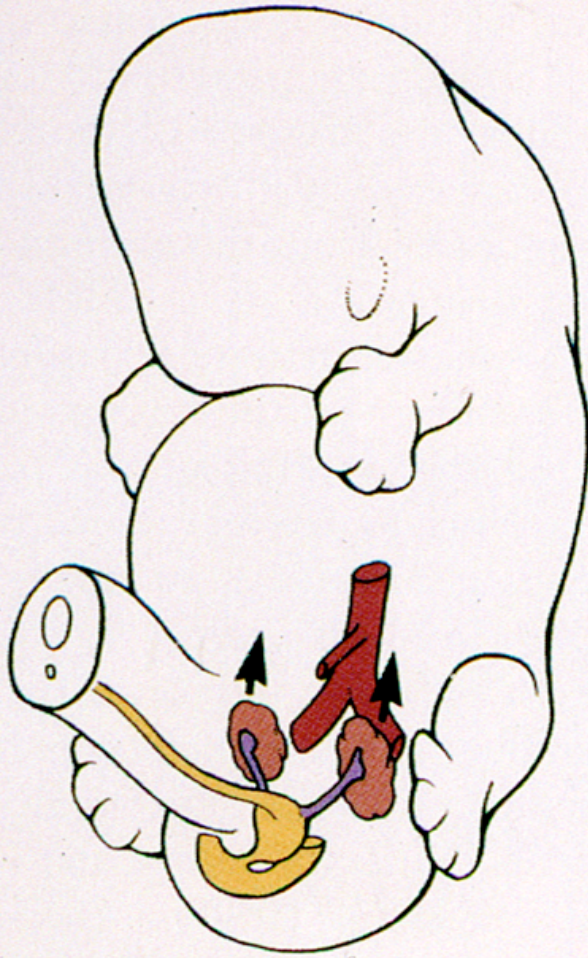




# RENAL MALDEVELOPMENT

- AN EXAMPLE OF ARPKD-AUTOSOMAL RECESSIVE POLYCYSTIC KIDNEY DISEASE.
- ASSOCIATED WITH NEARLY UNIFORM INFANT MORTALITY
- ASSOCIATED WITH PKHD1 ON CHROMOSOME 6



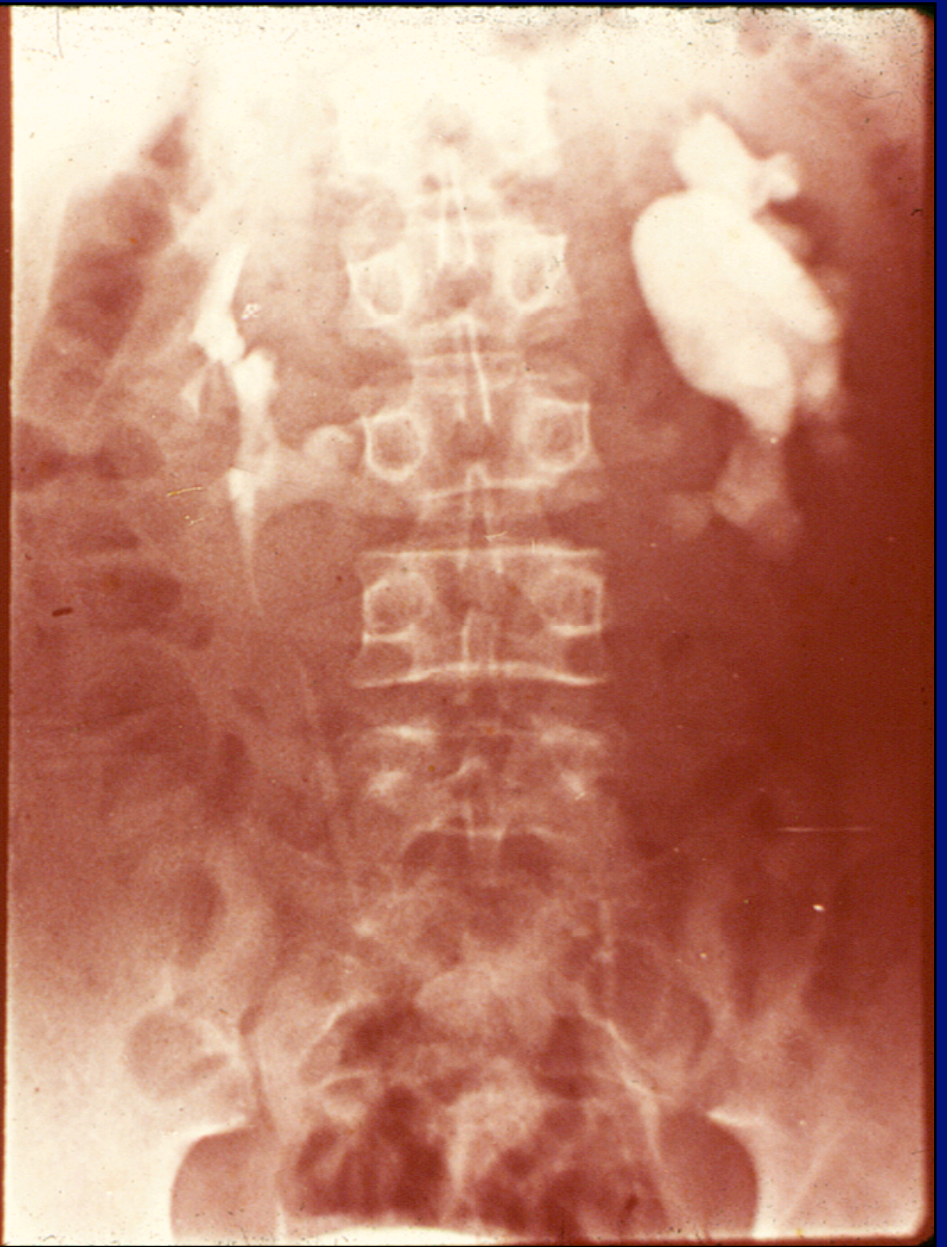
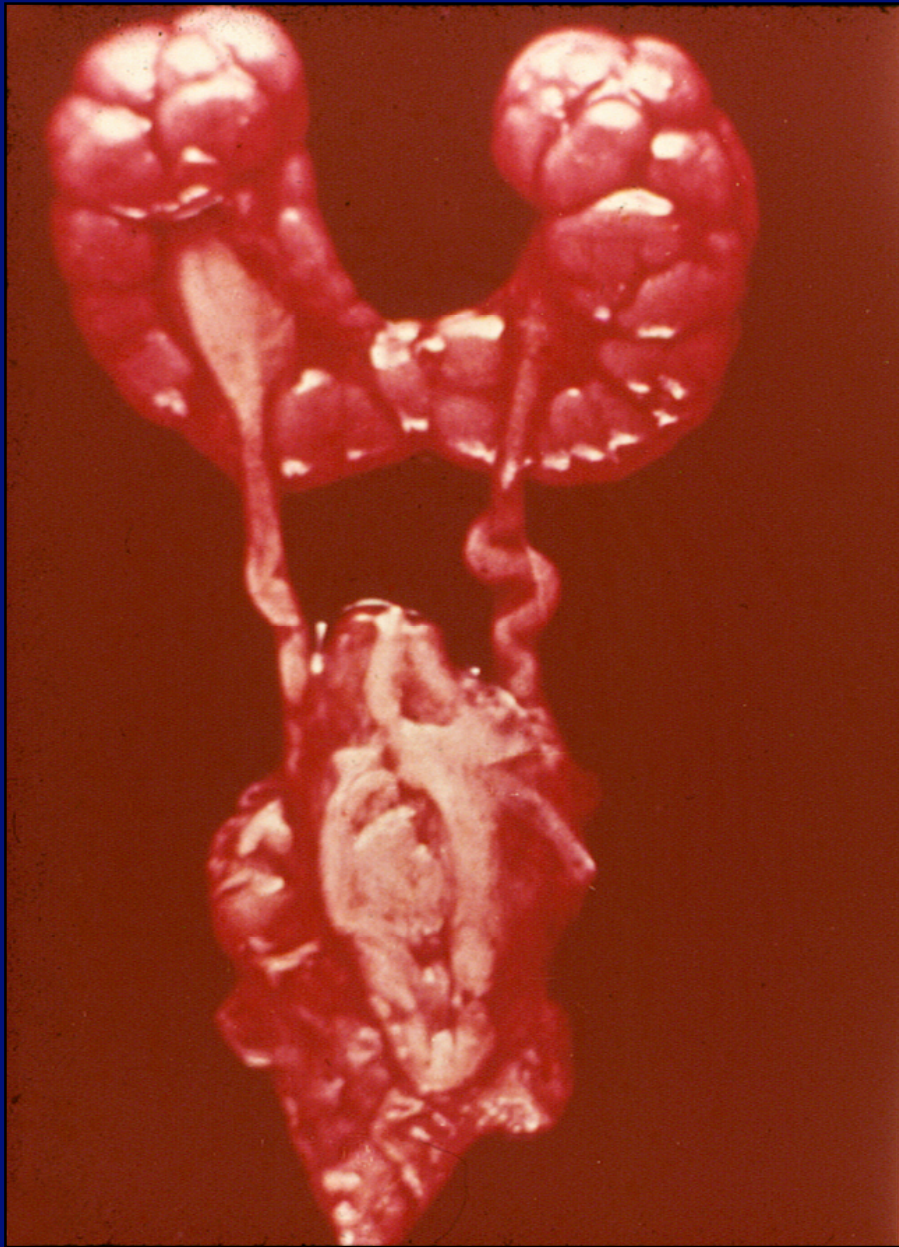

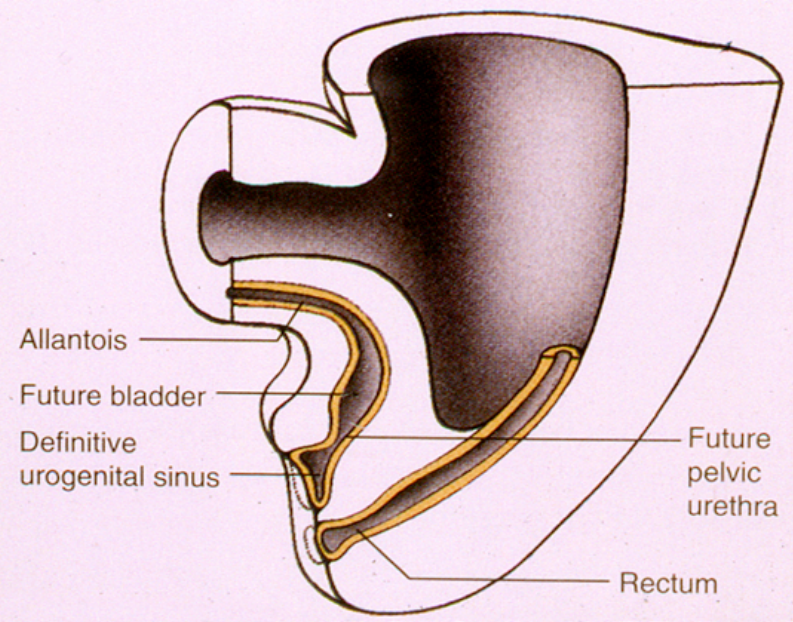
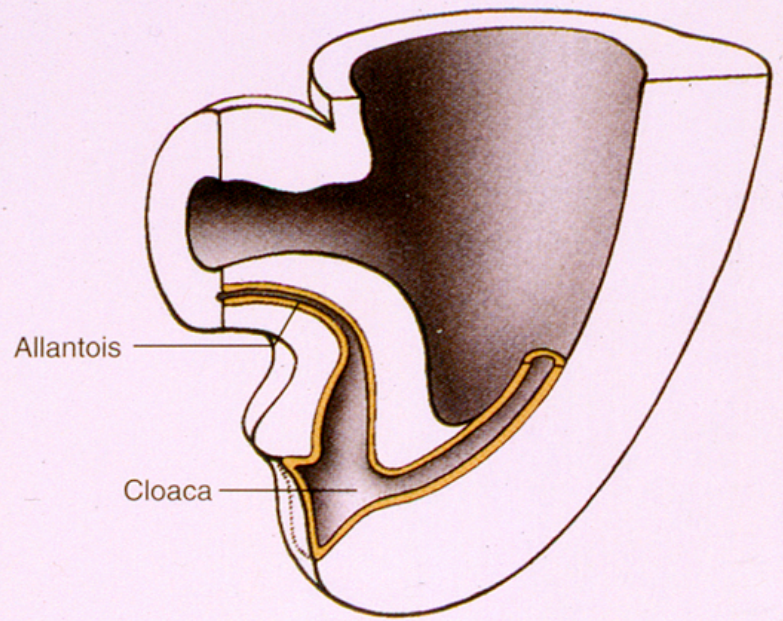
**A** 6th week

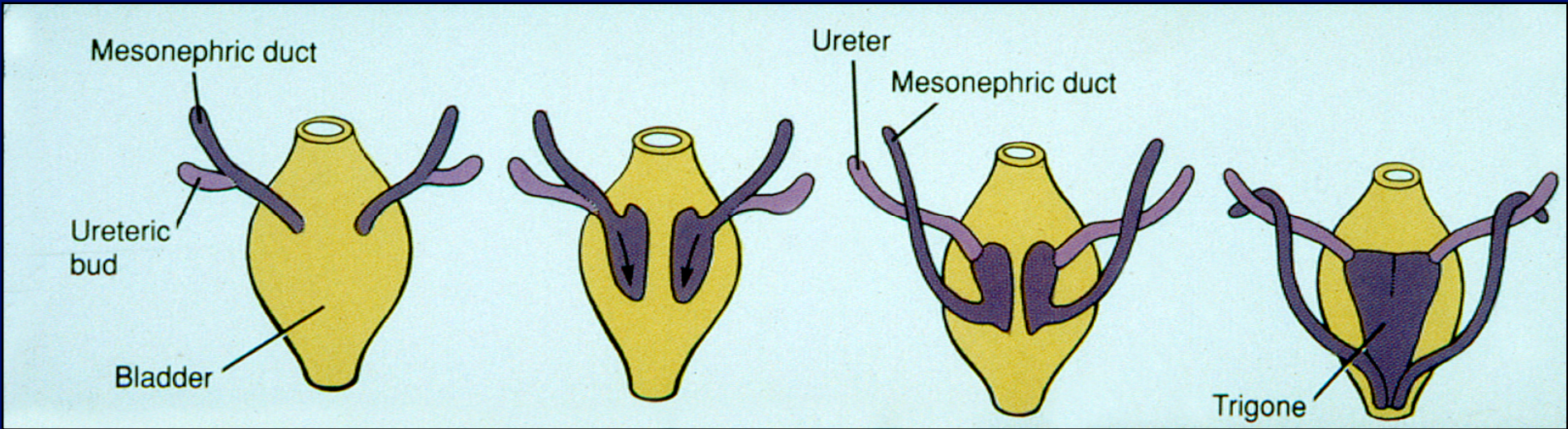
**B** Normal

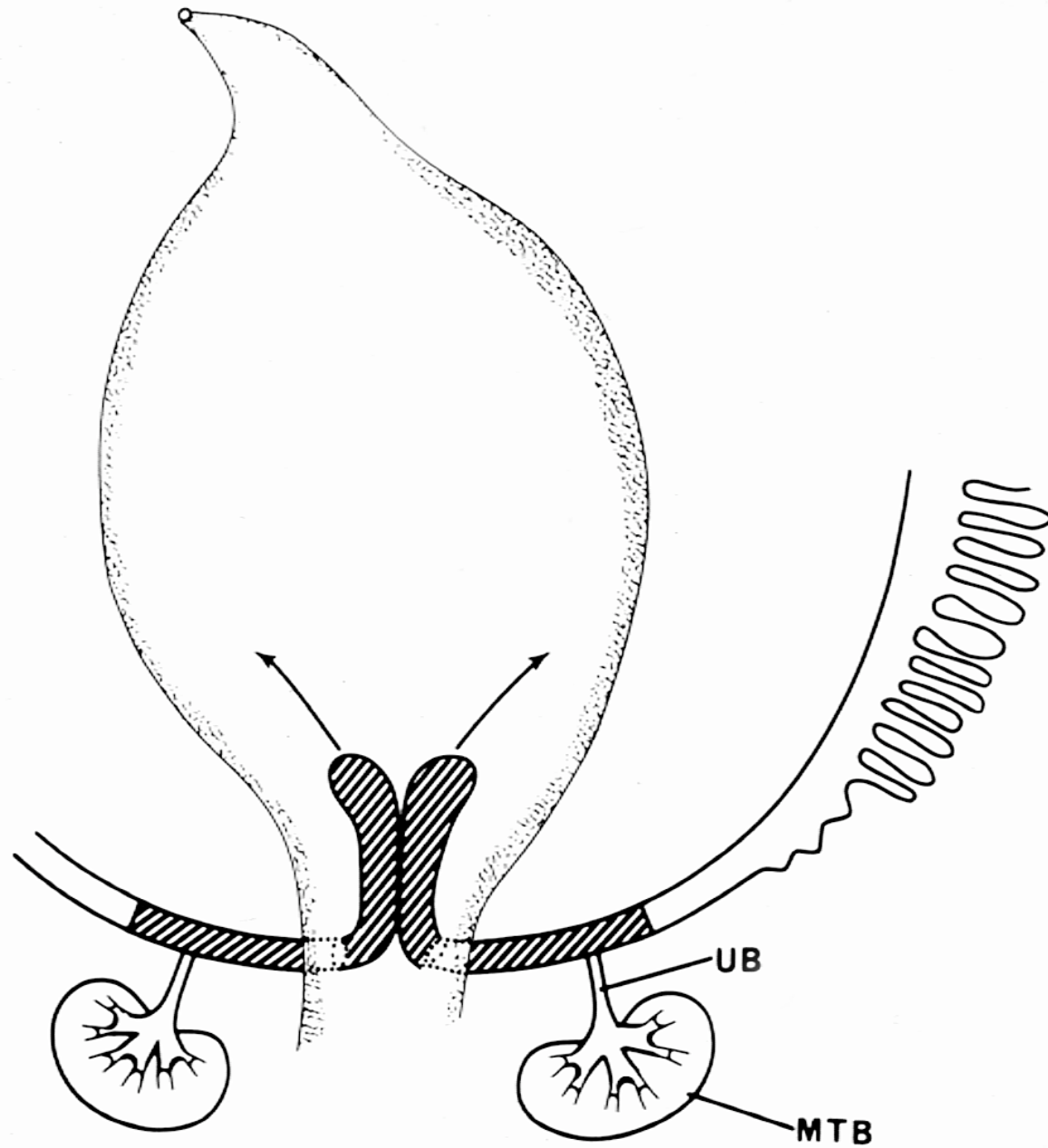
**C** Pelvic kidney

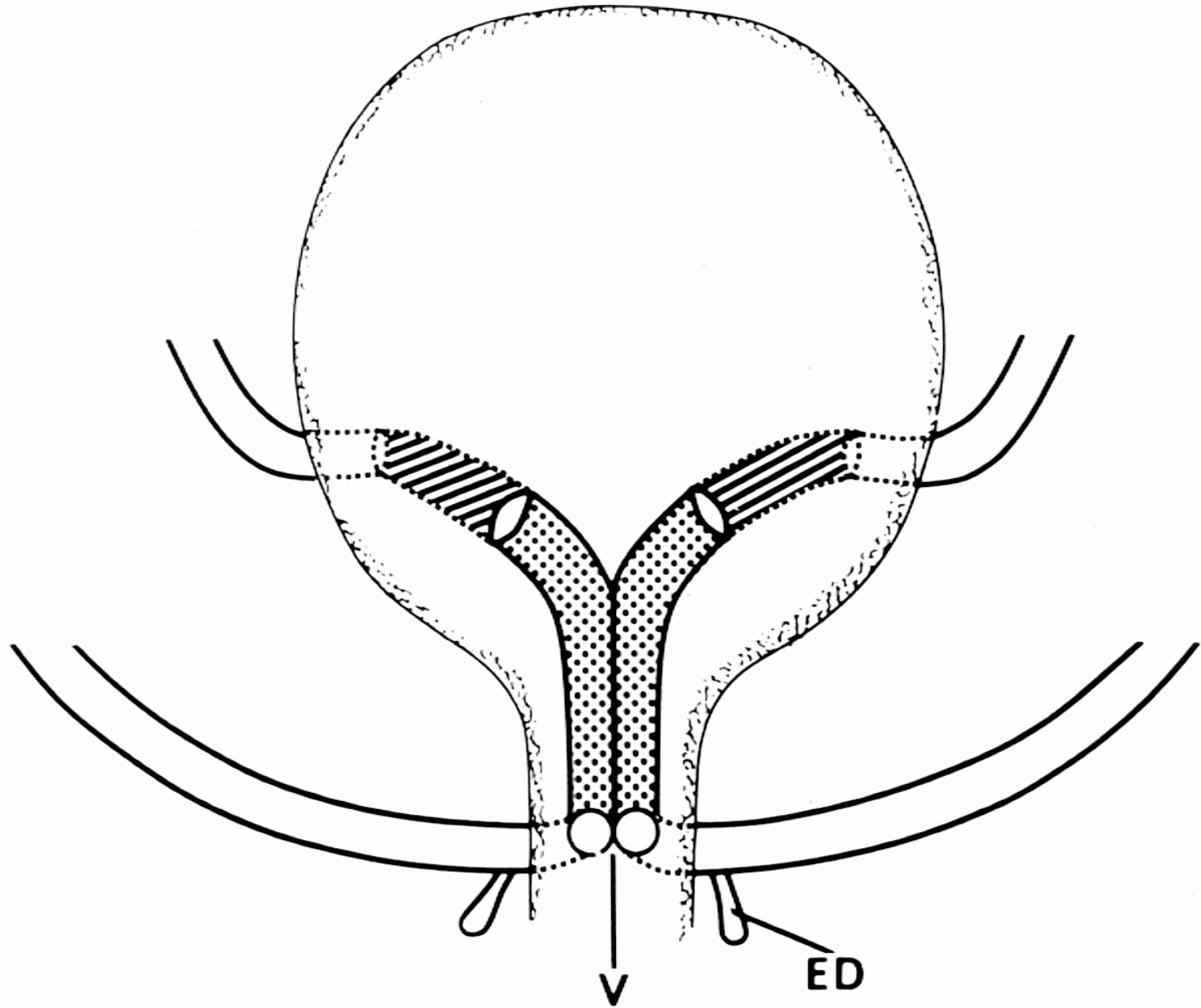
**D** Horseshoe kidney











# Abnormalities of Ureteral Bud Development

## URETERIC BUD DEFECT

## ASSOCIATED RENAL ANOMALY

Failure of bud

Renal agenesis

Abnormal position of bud

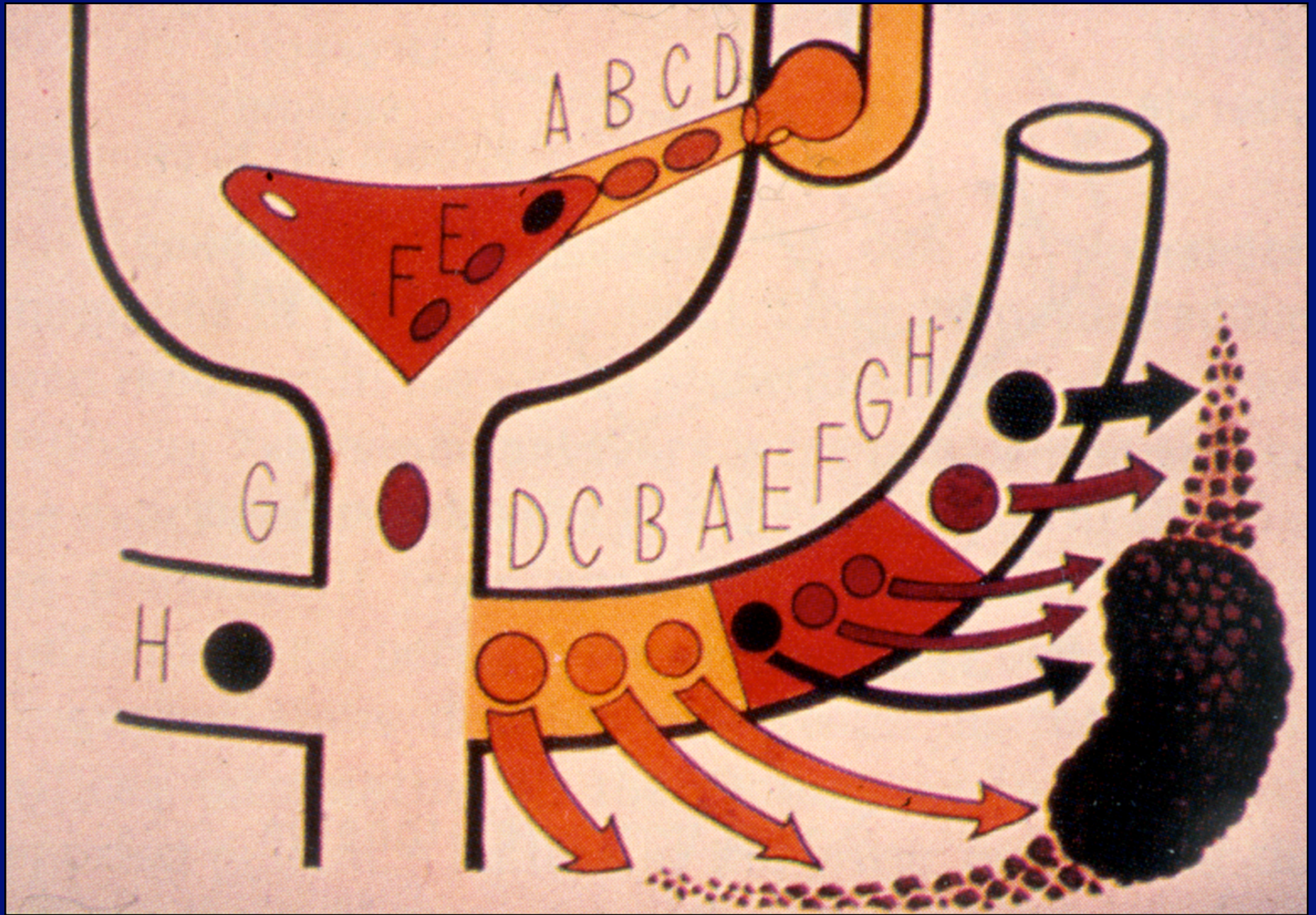
Ureterocele, ectopic ureter  
diverticulum

Splitting of bud

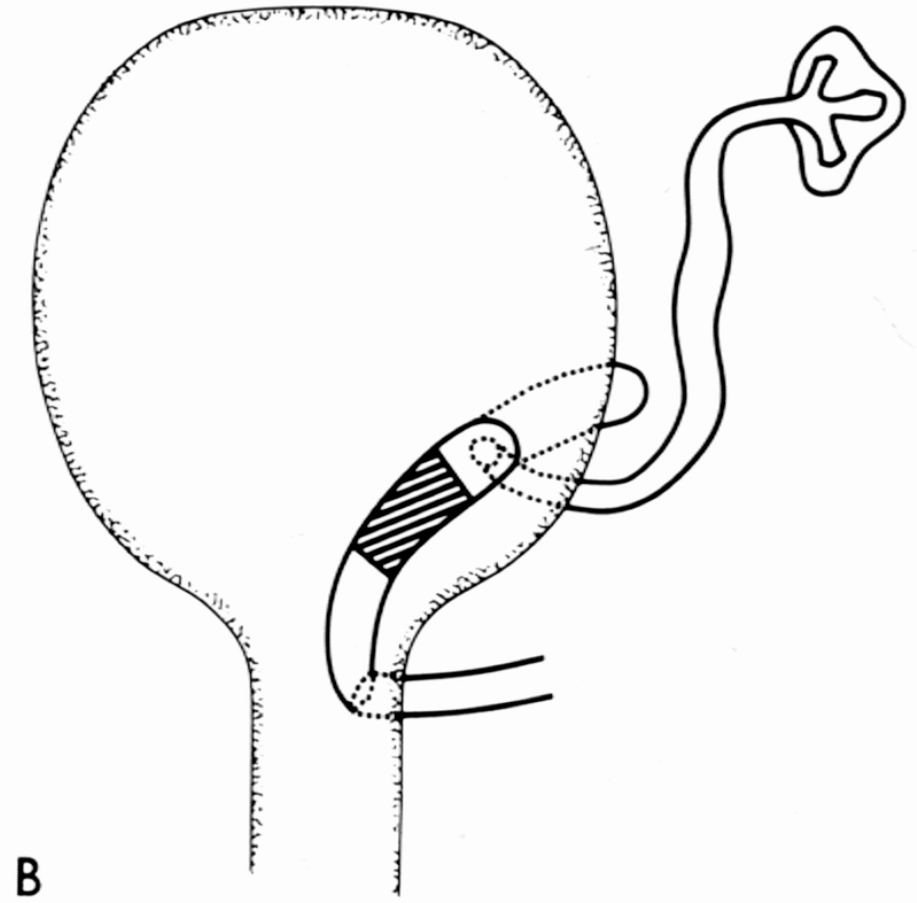
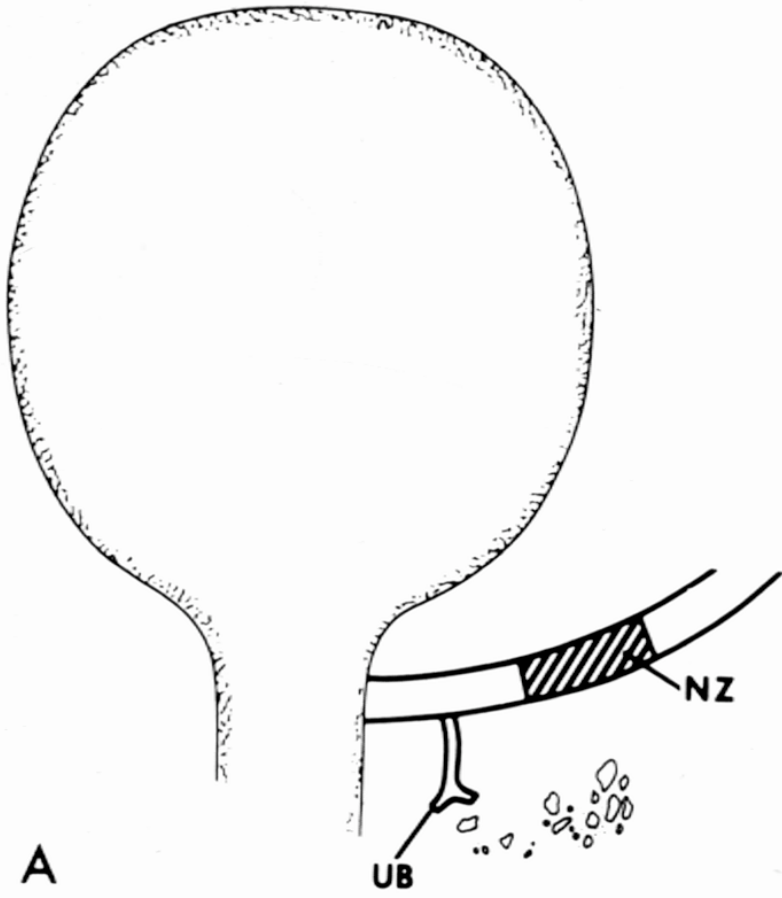
Duplication anomaly

Excess absorption of bud

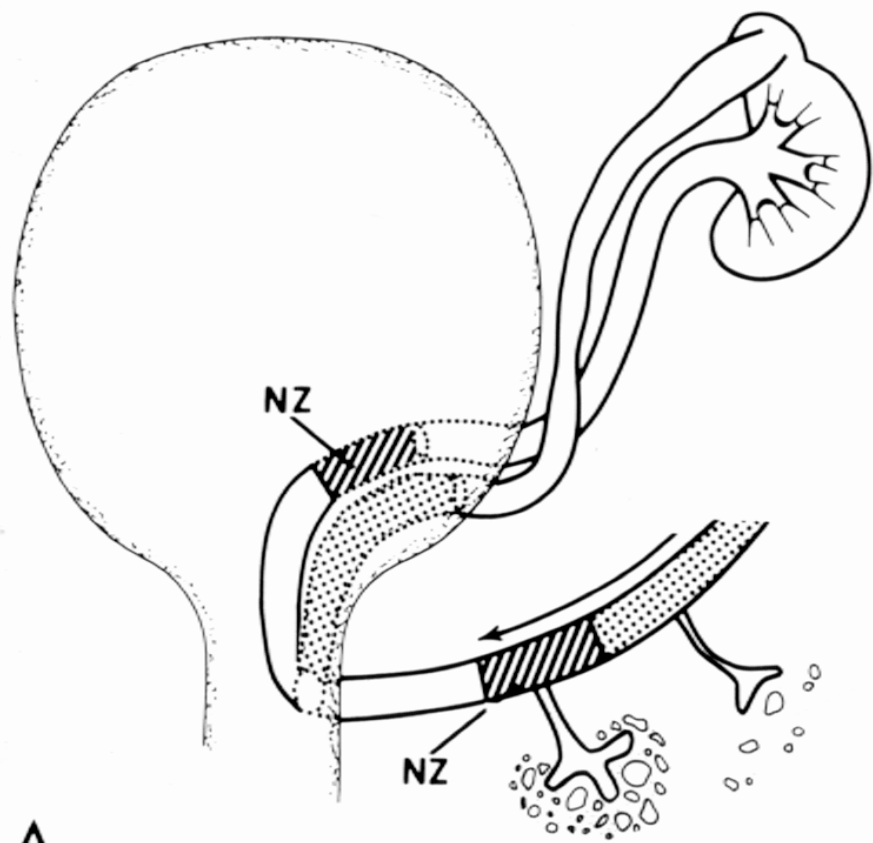
Refluxing orifice



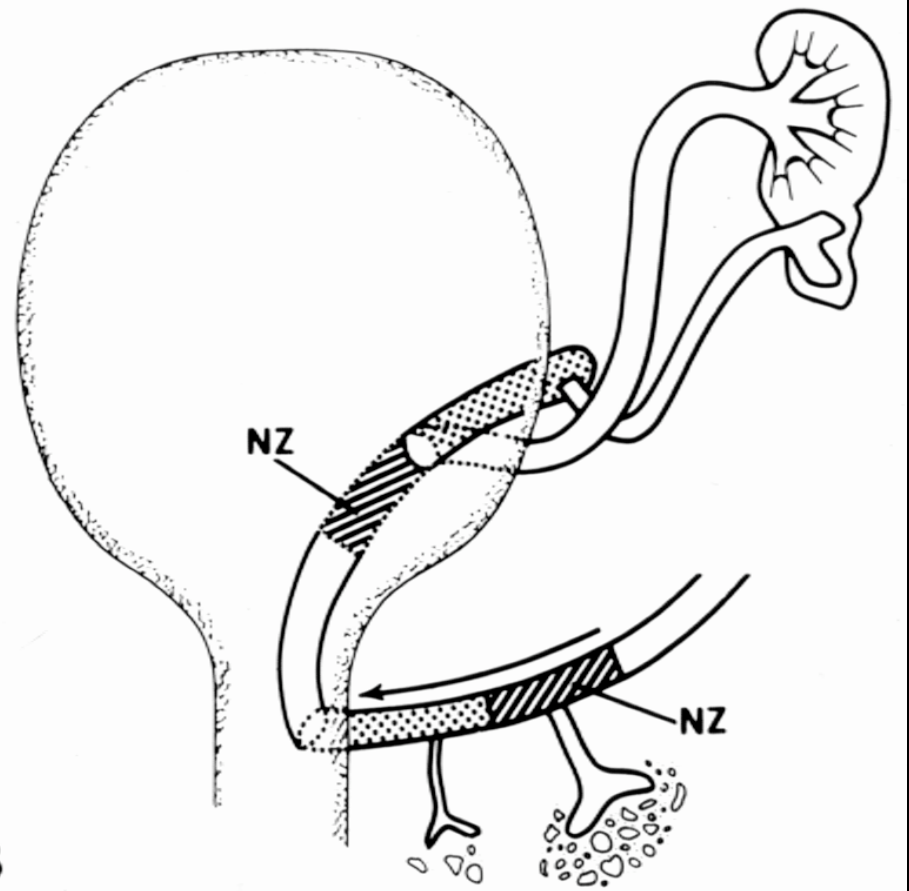
# ***Vesicoureteral Reflux***



# ***Ureteral Duplication***

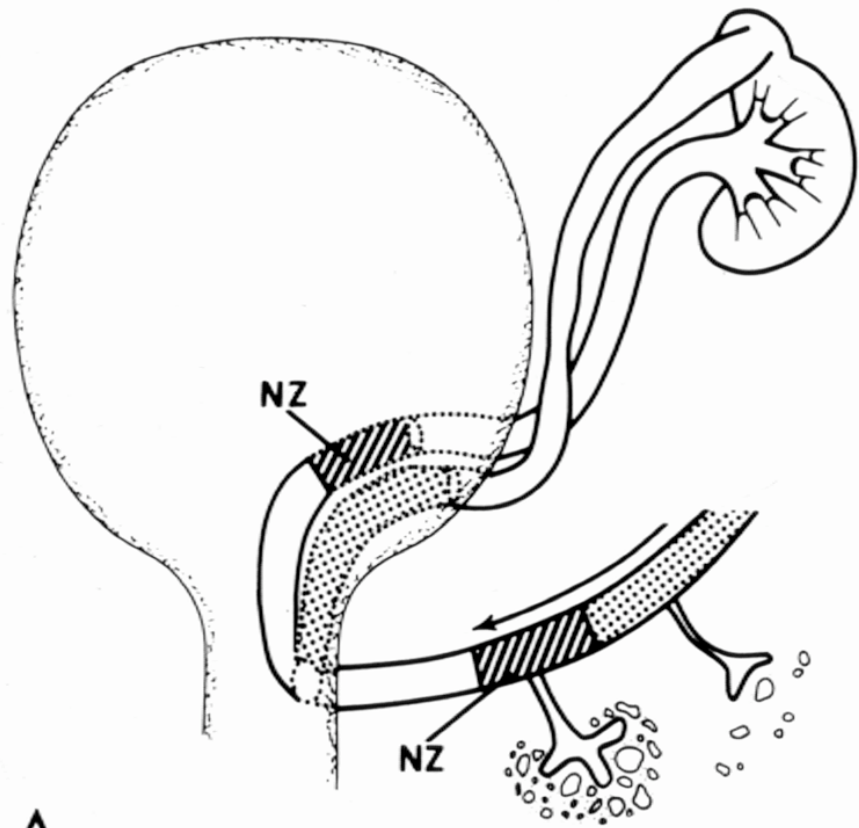


A

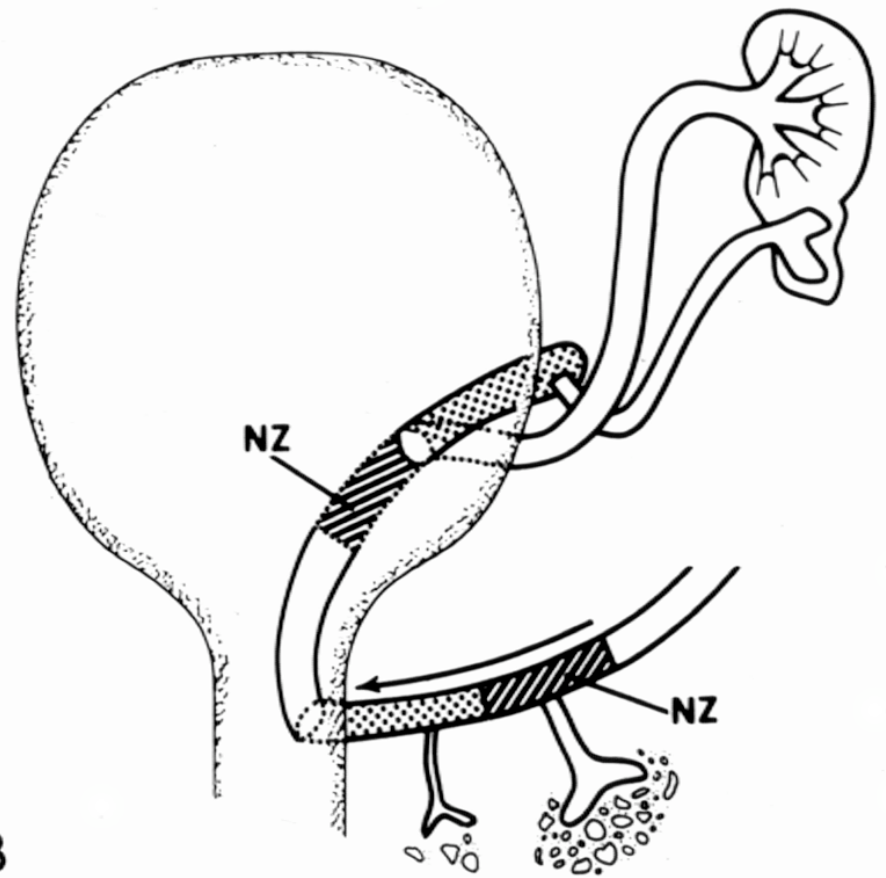


B

# ***Ectopic Ureter***

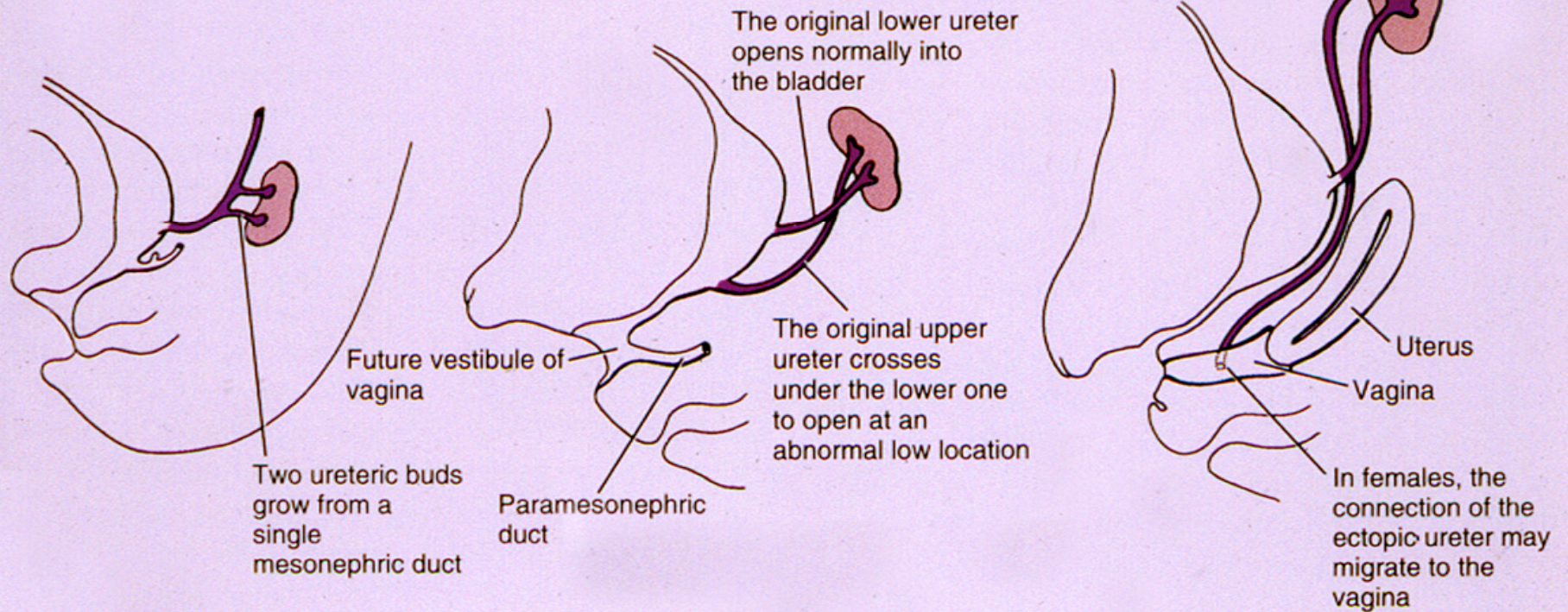


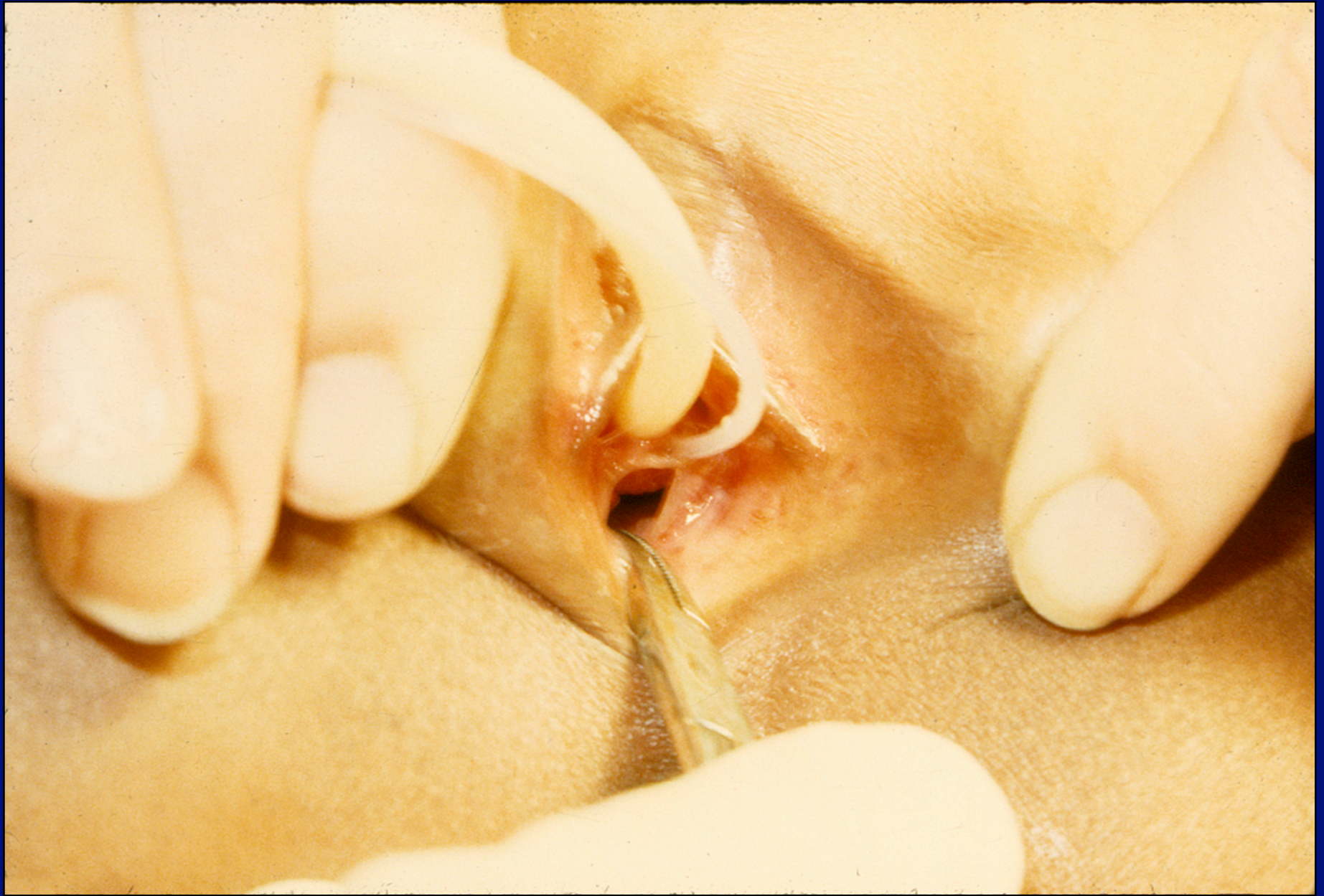A



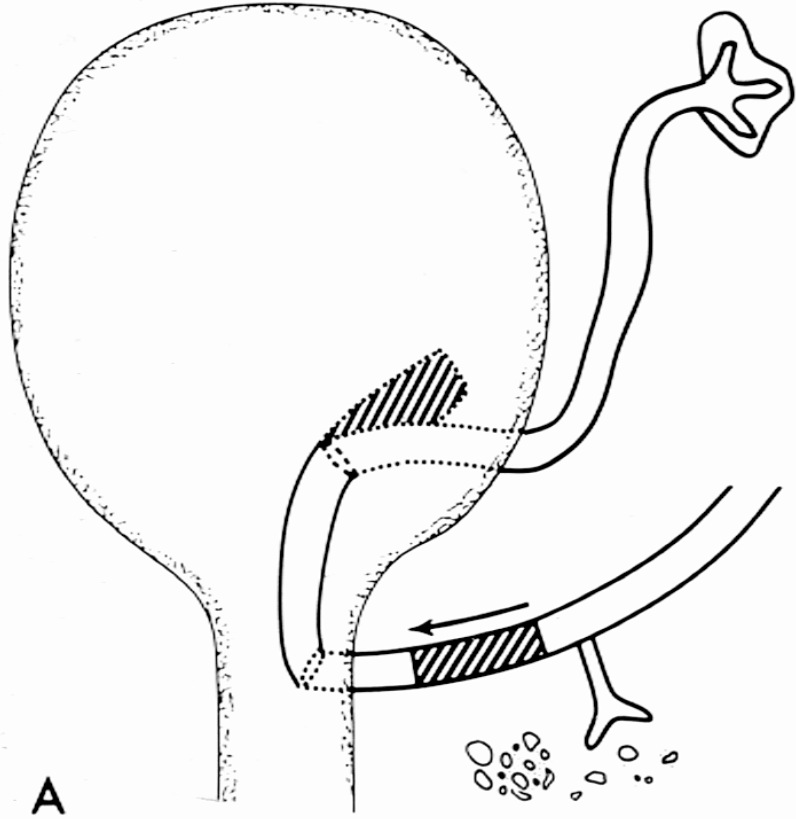
B

The ureters invert their positions as they exstrophy into the bladder (the Weigert-Meyer rule):

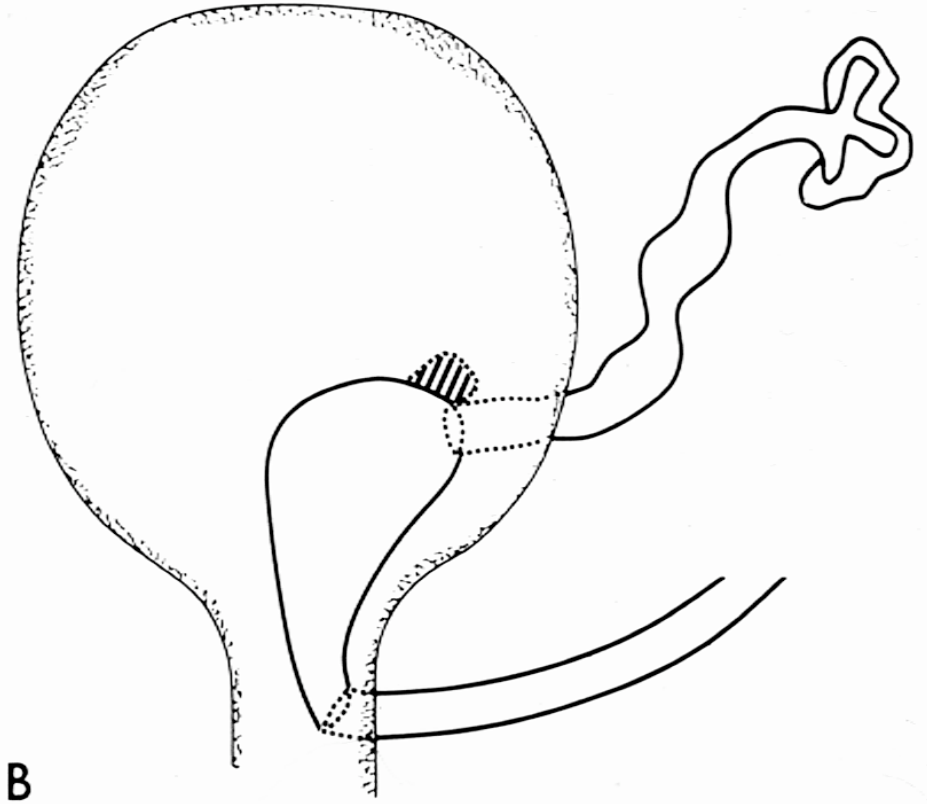




# ***Ureterocele***



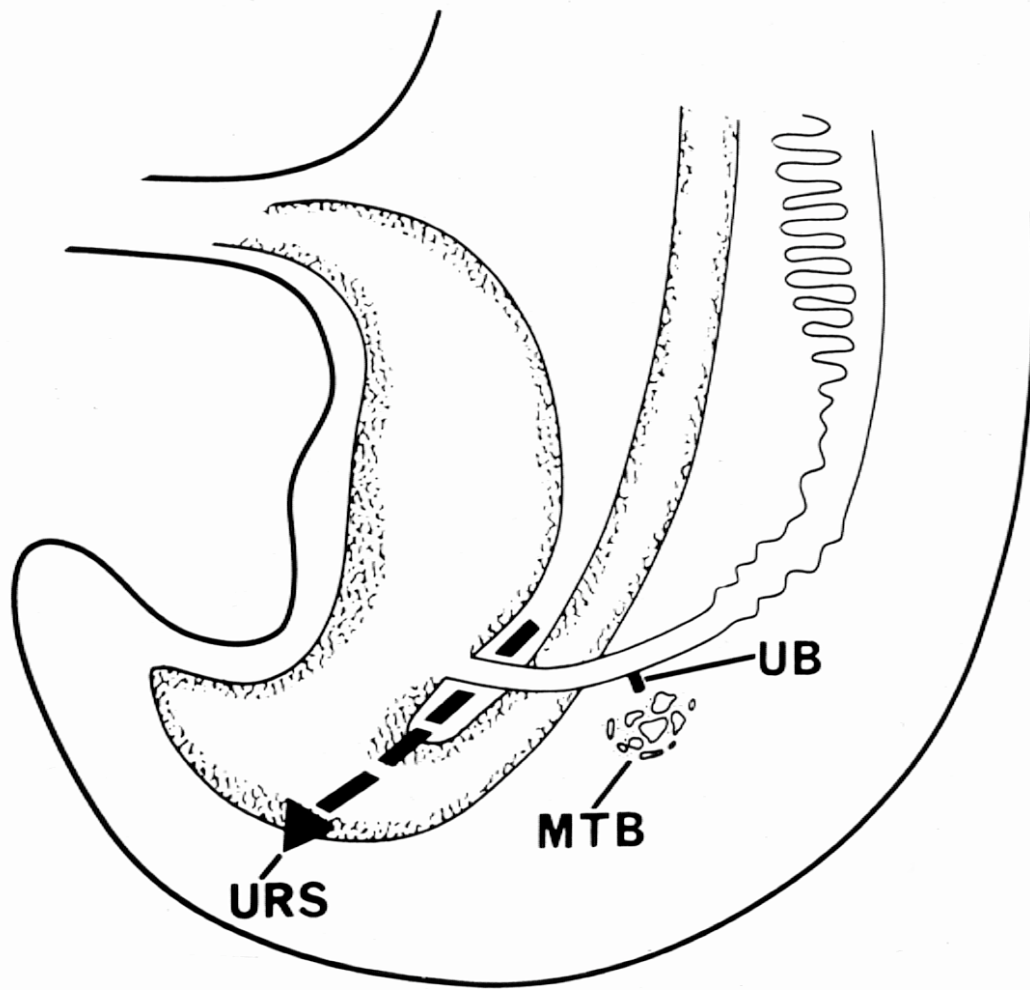
A

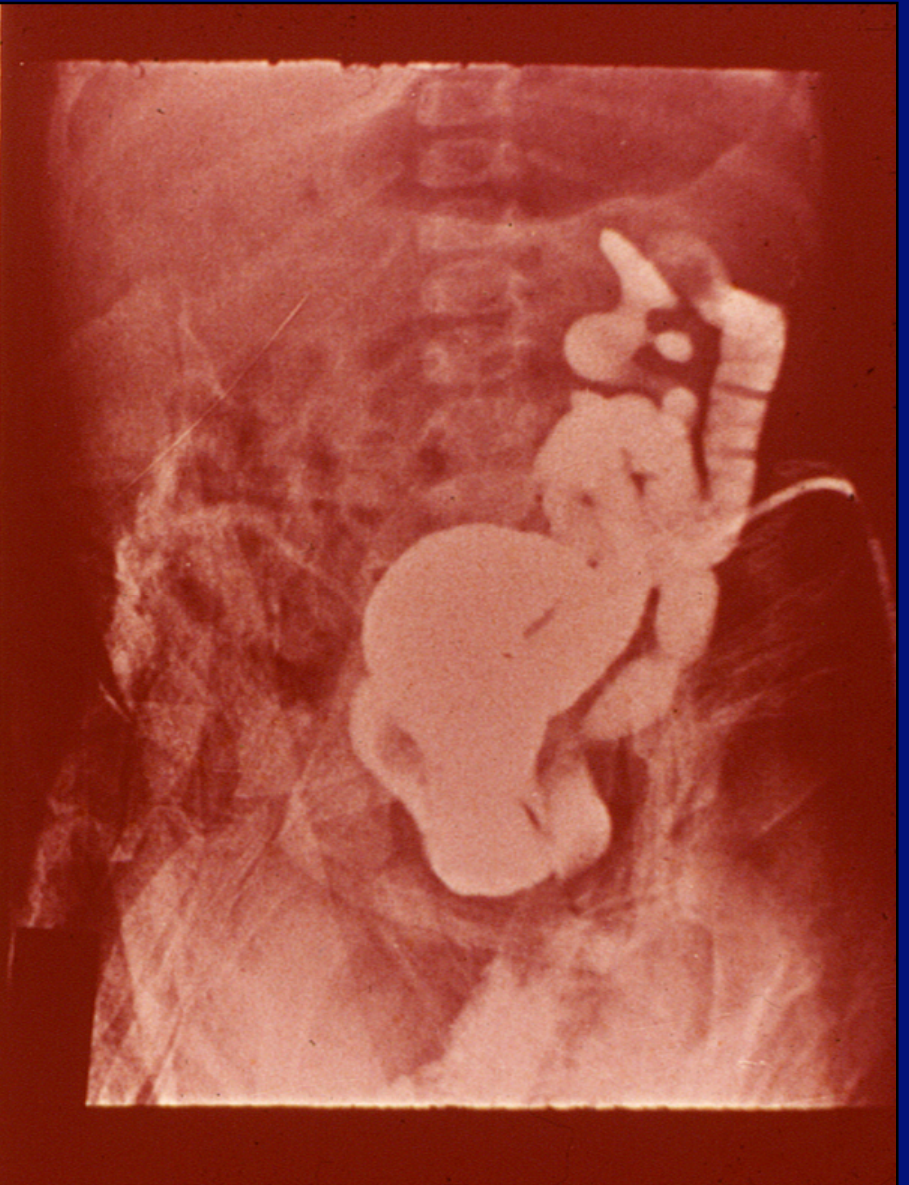
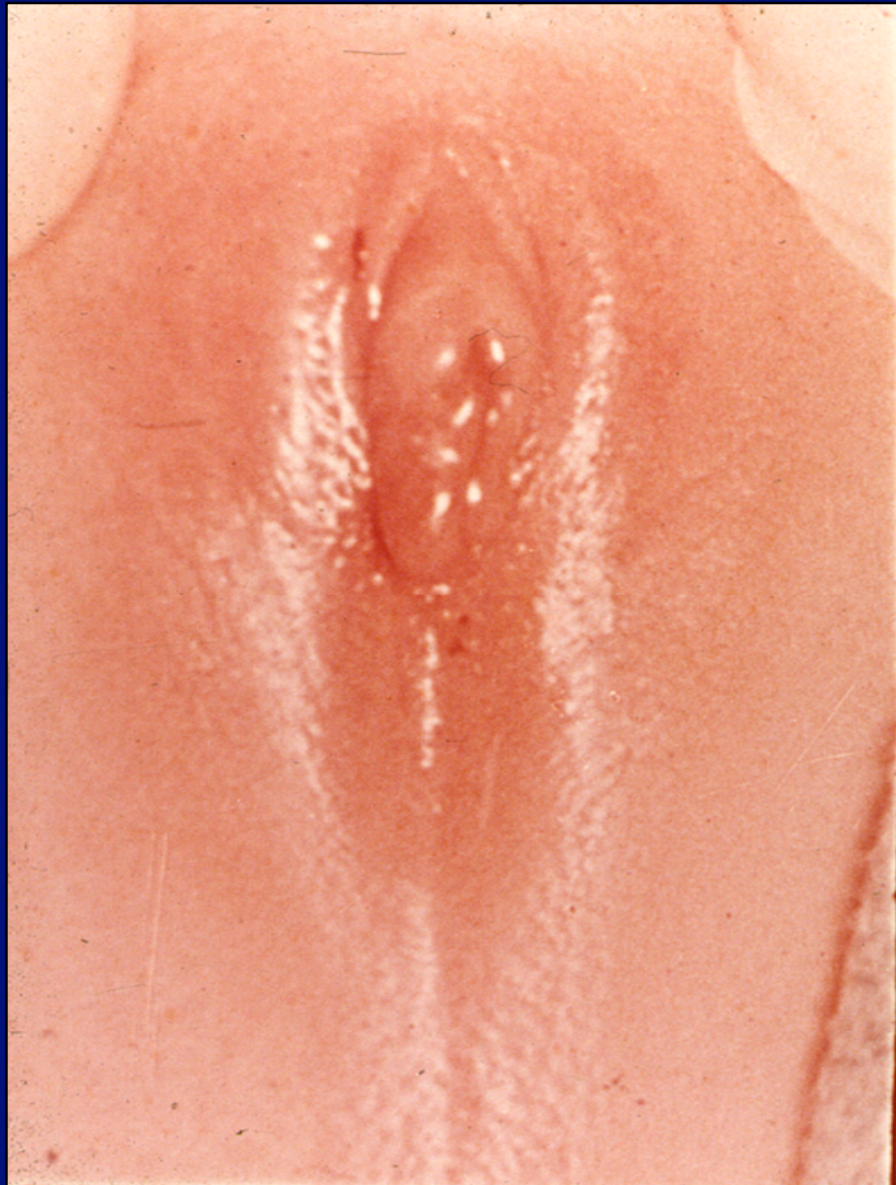

B

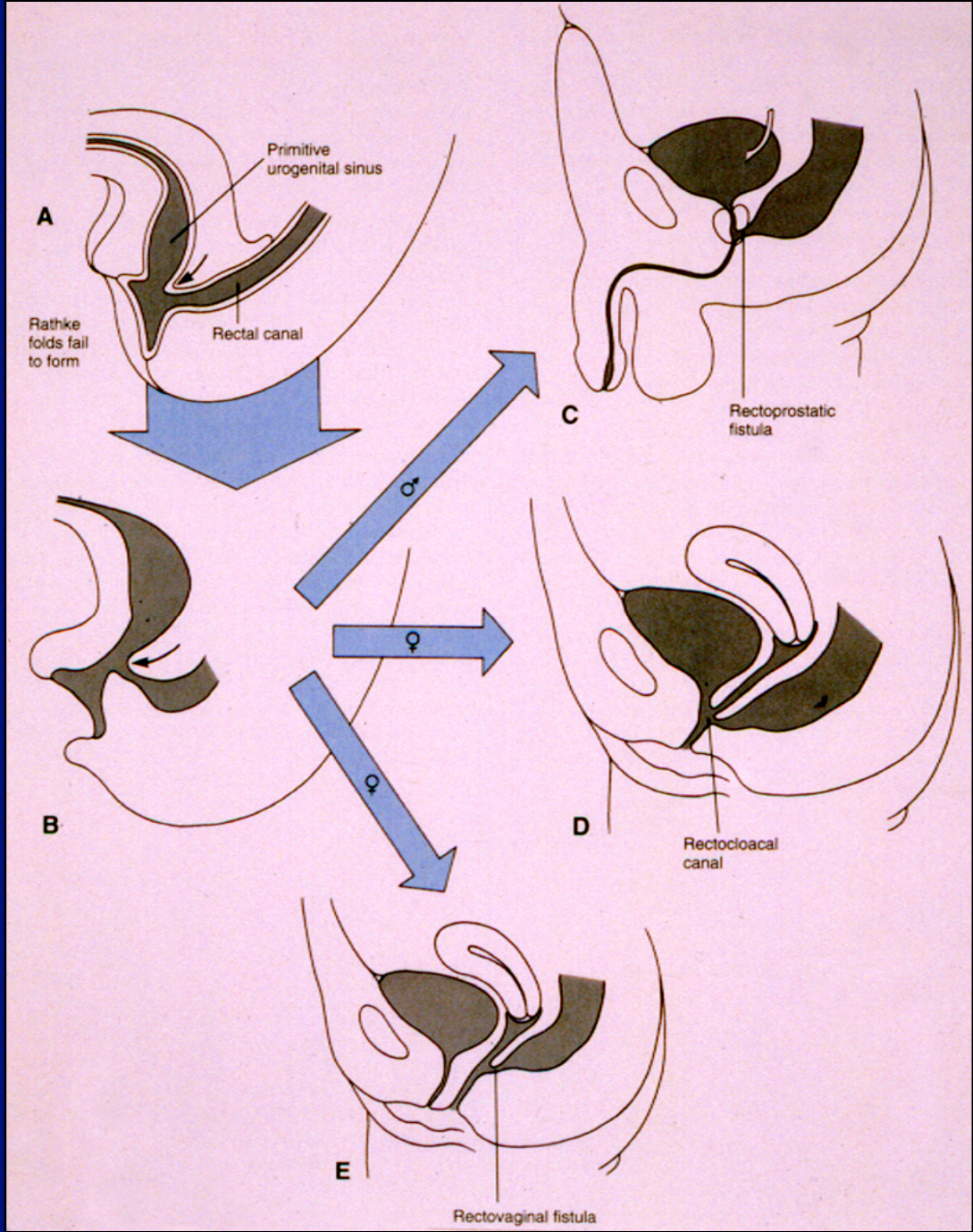
# ***Diverticulum (Paraureteral)***

# ***Cloacal Anomaly***

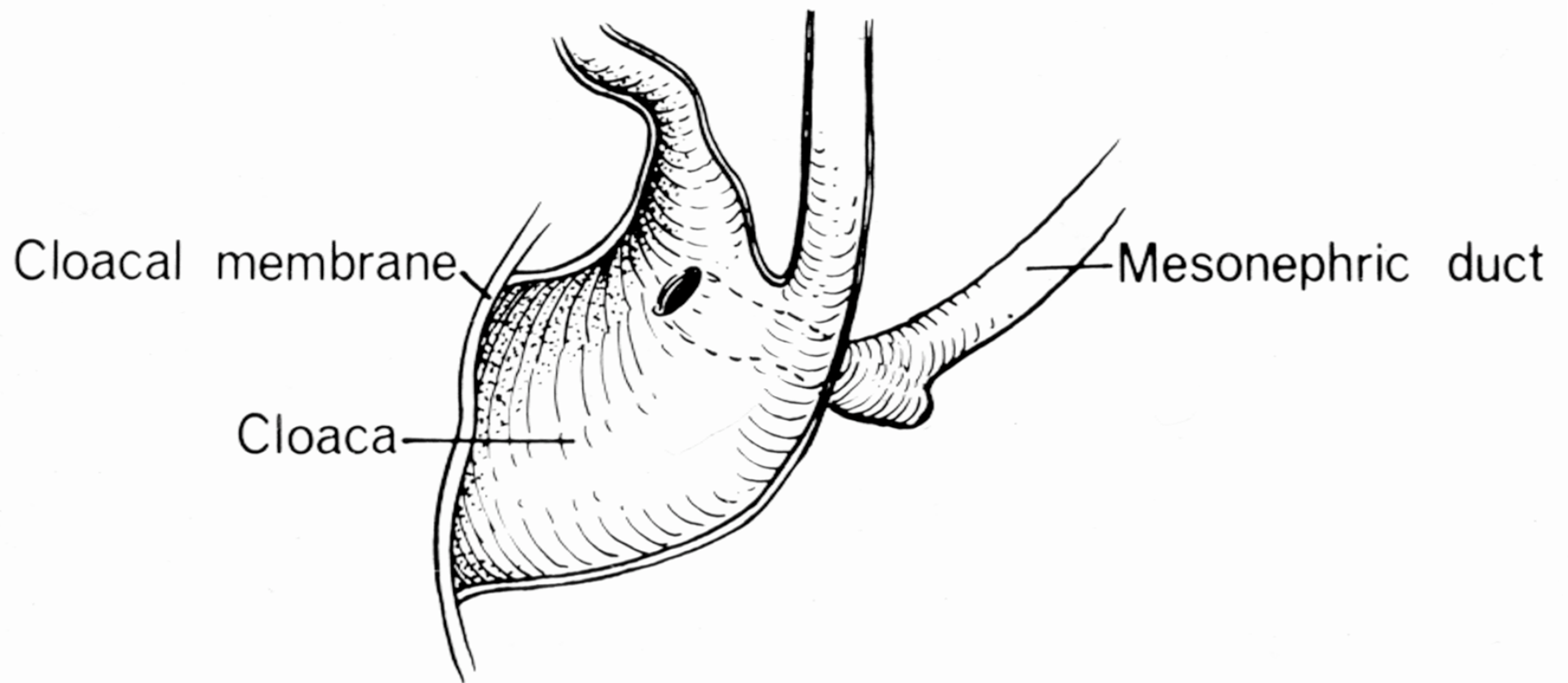




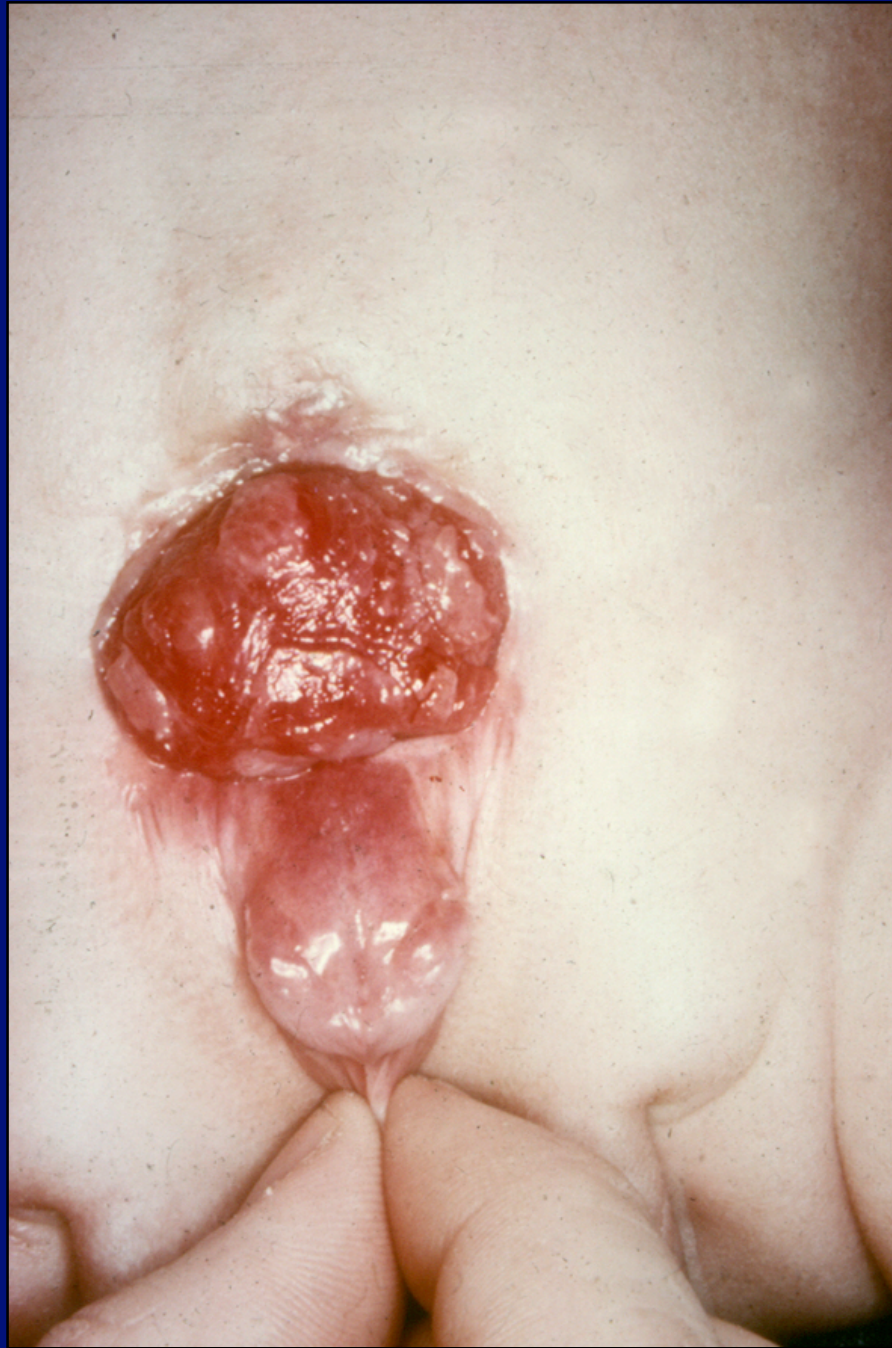
# ***Imperforate Anus***

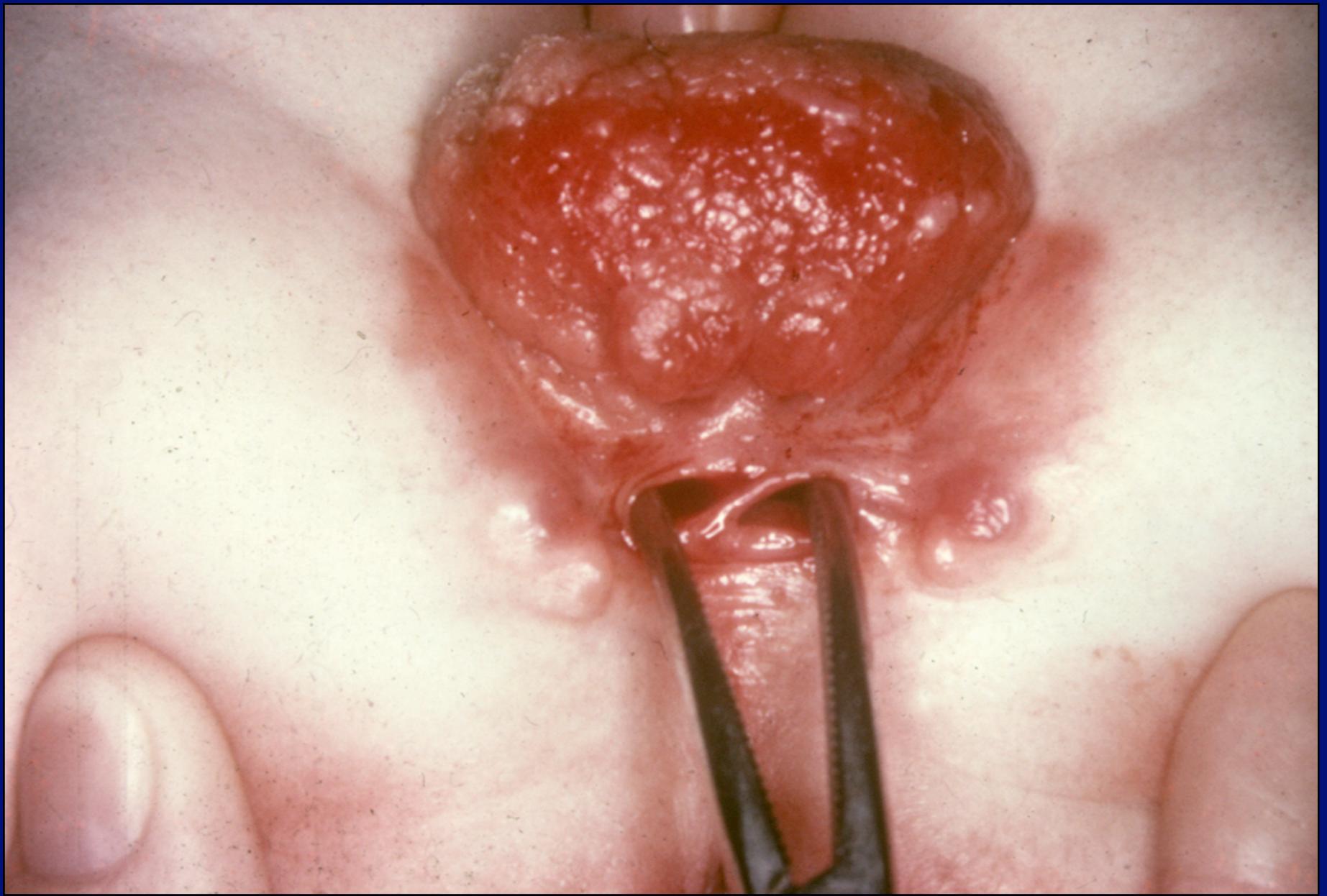


# ***Exstrophy - Epispadias Complex***

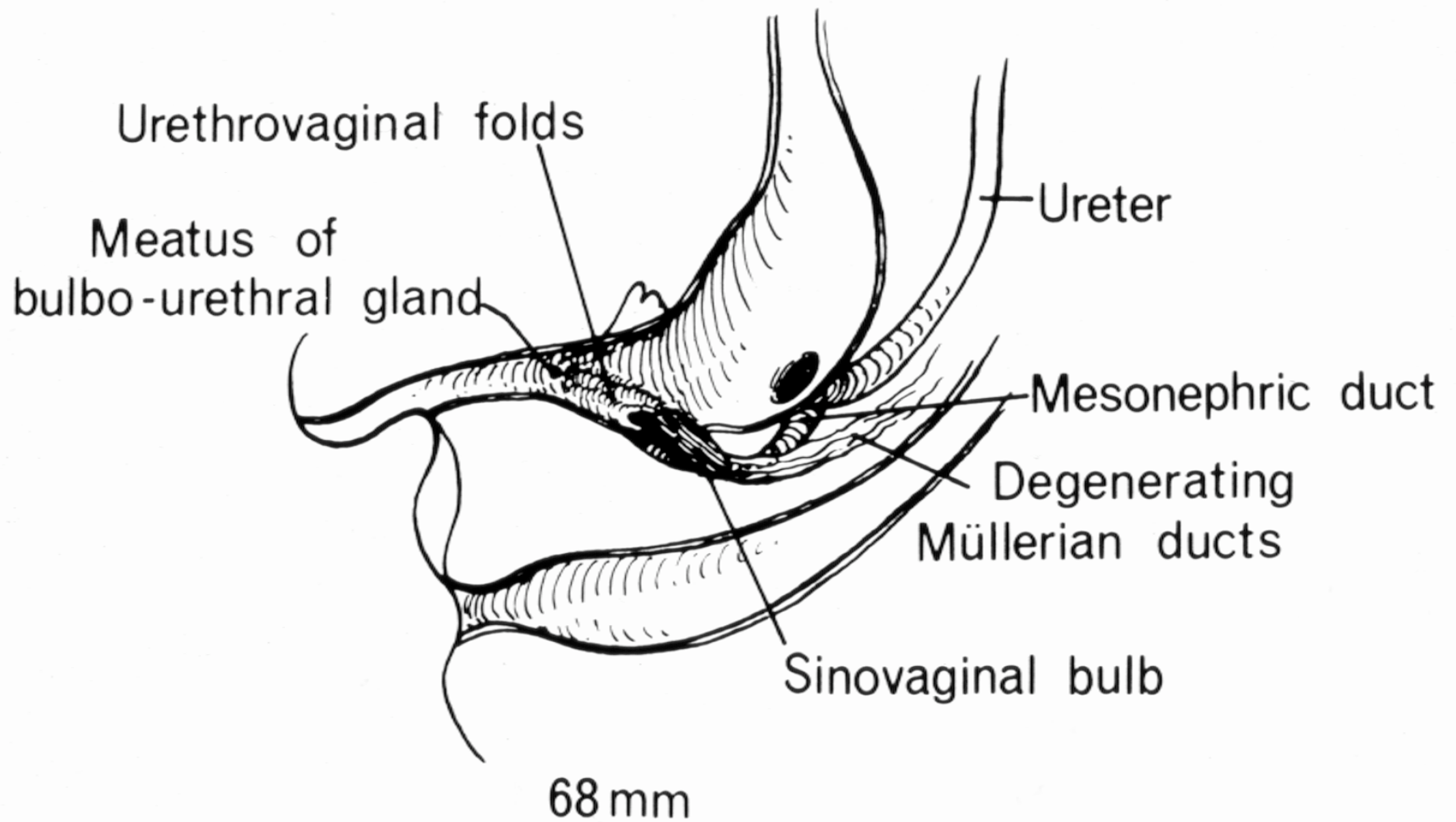


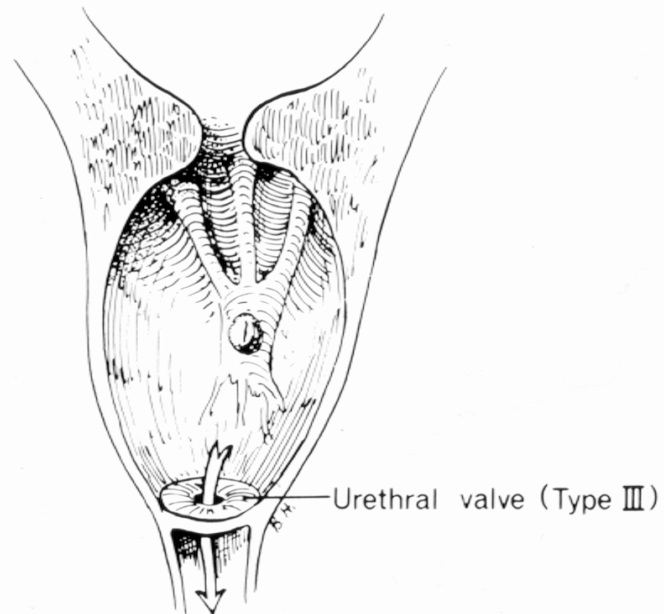
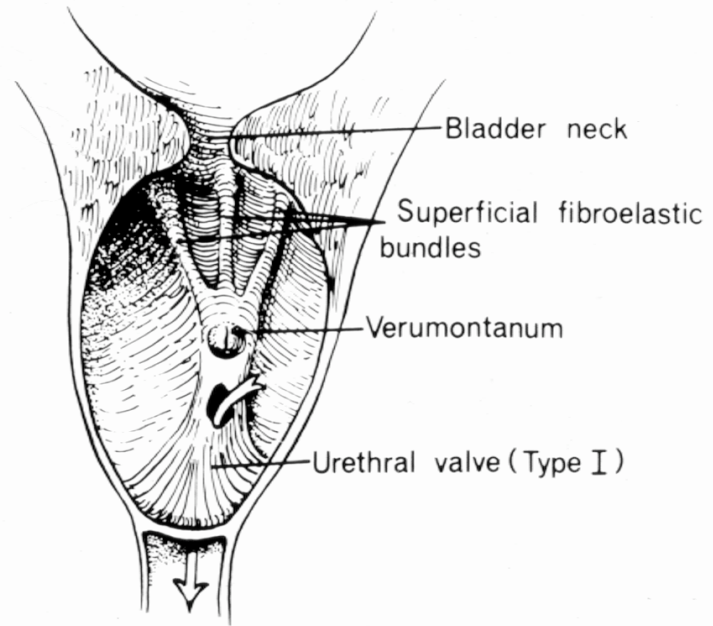
4 mm

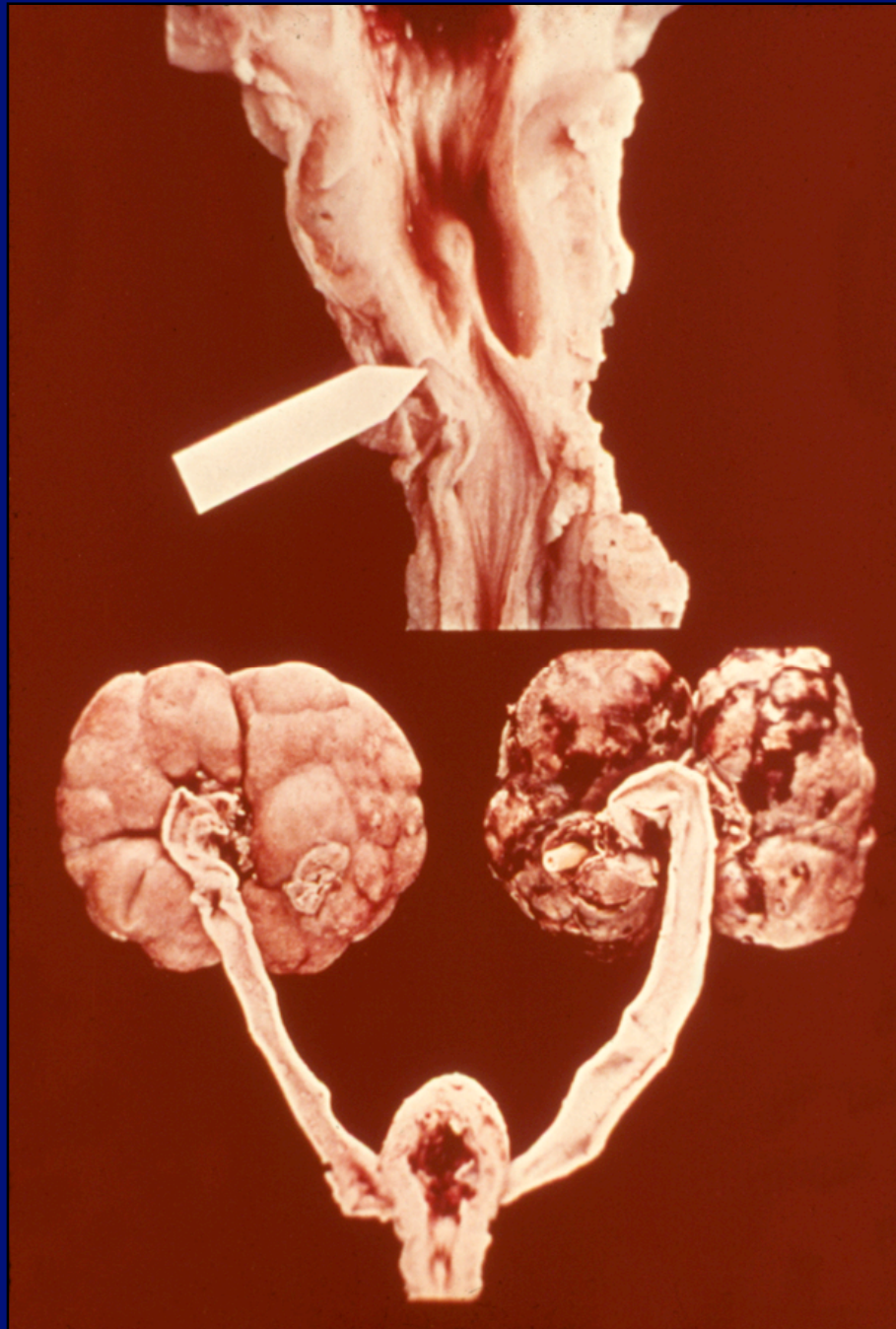


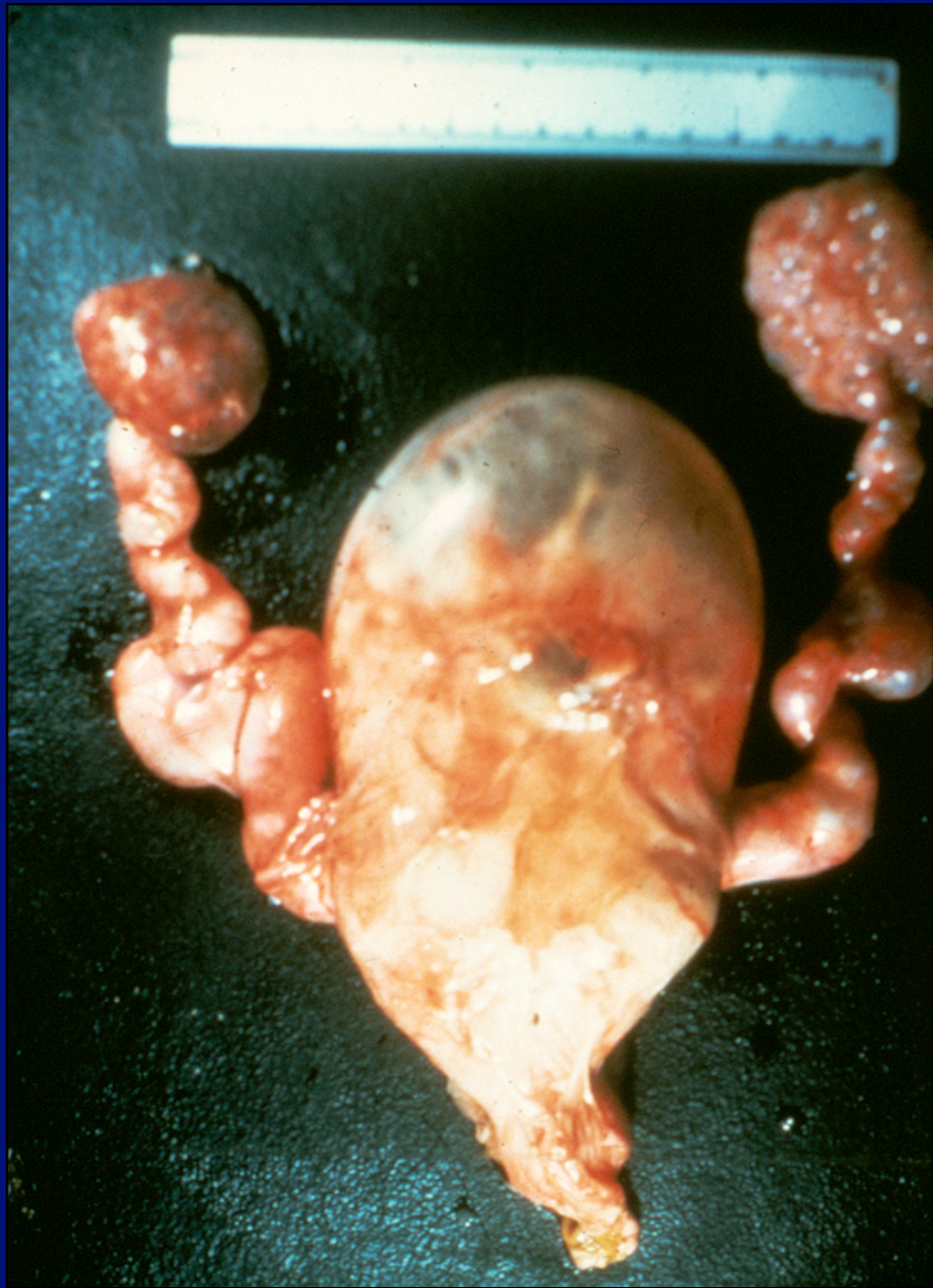
# ***Posterior Urethral Valves***

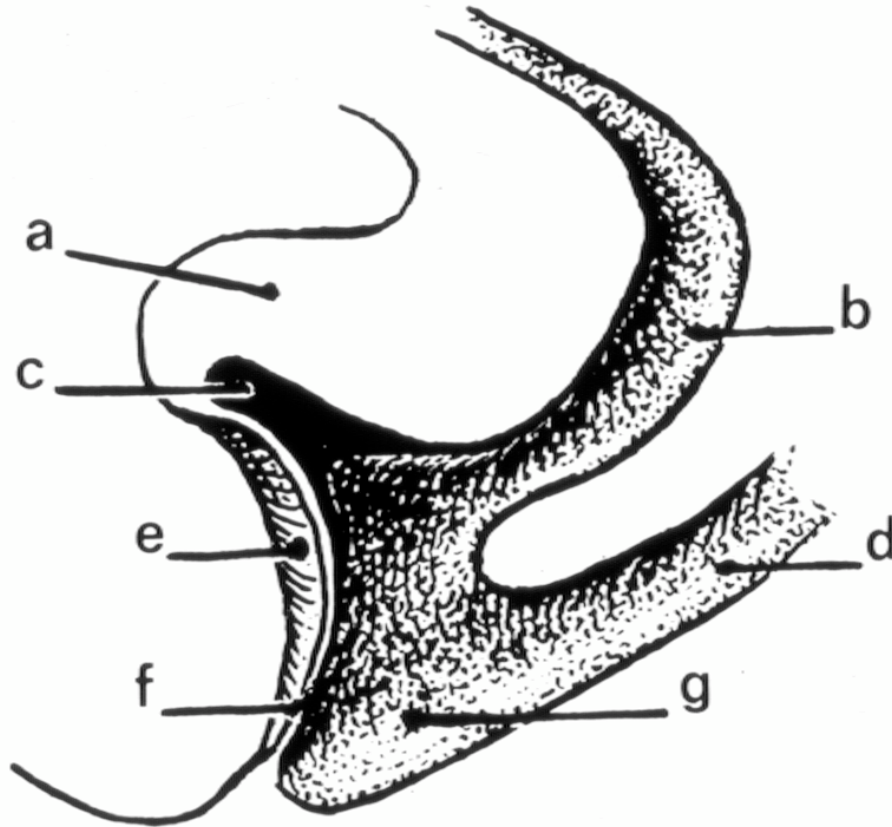




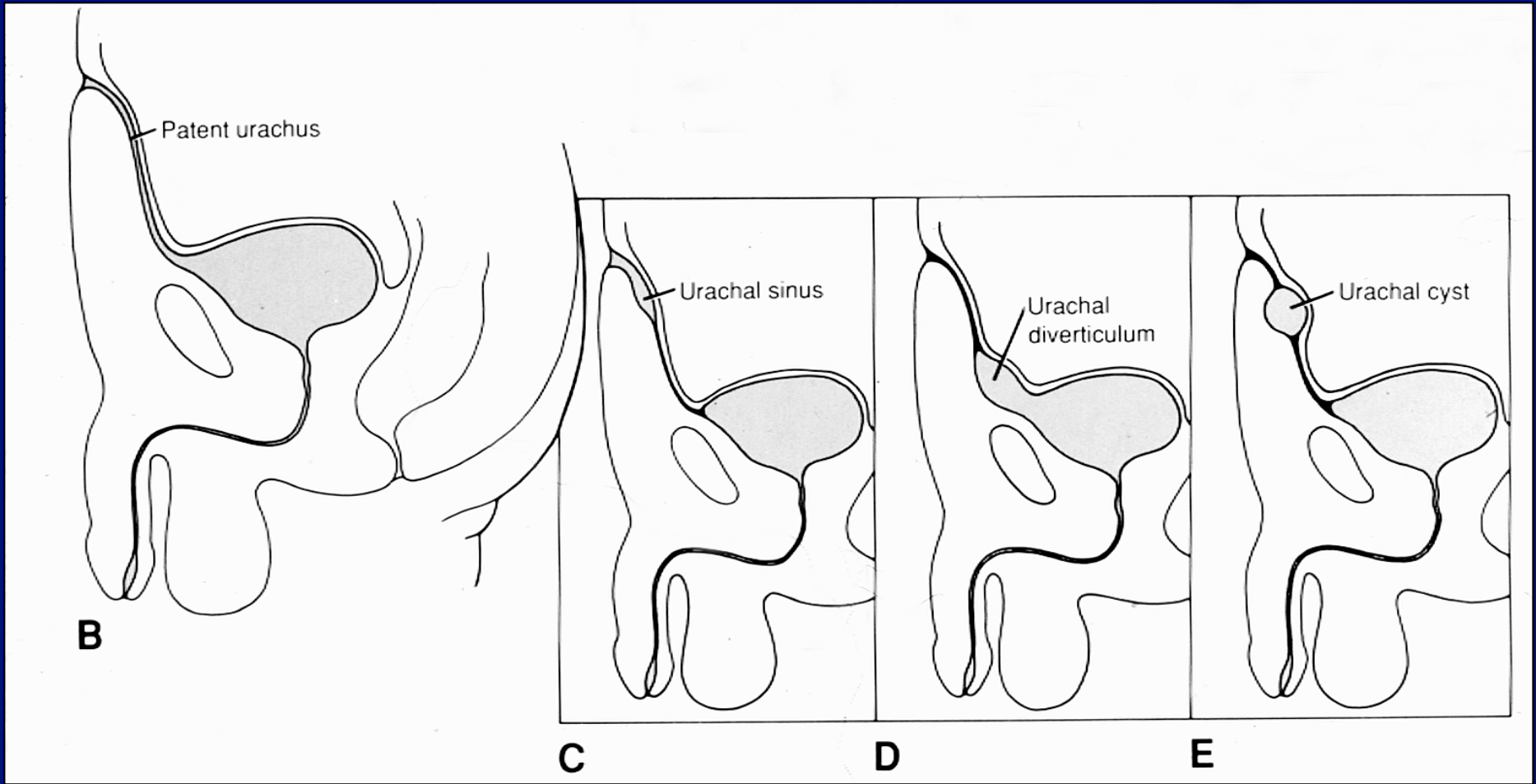


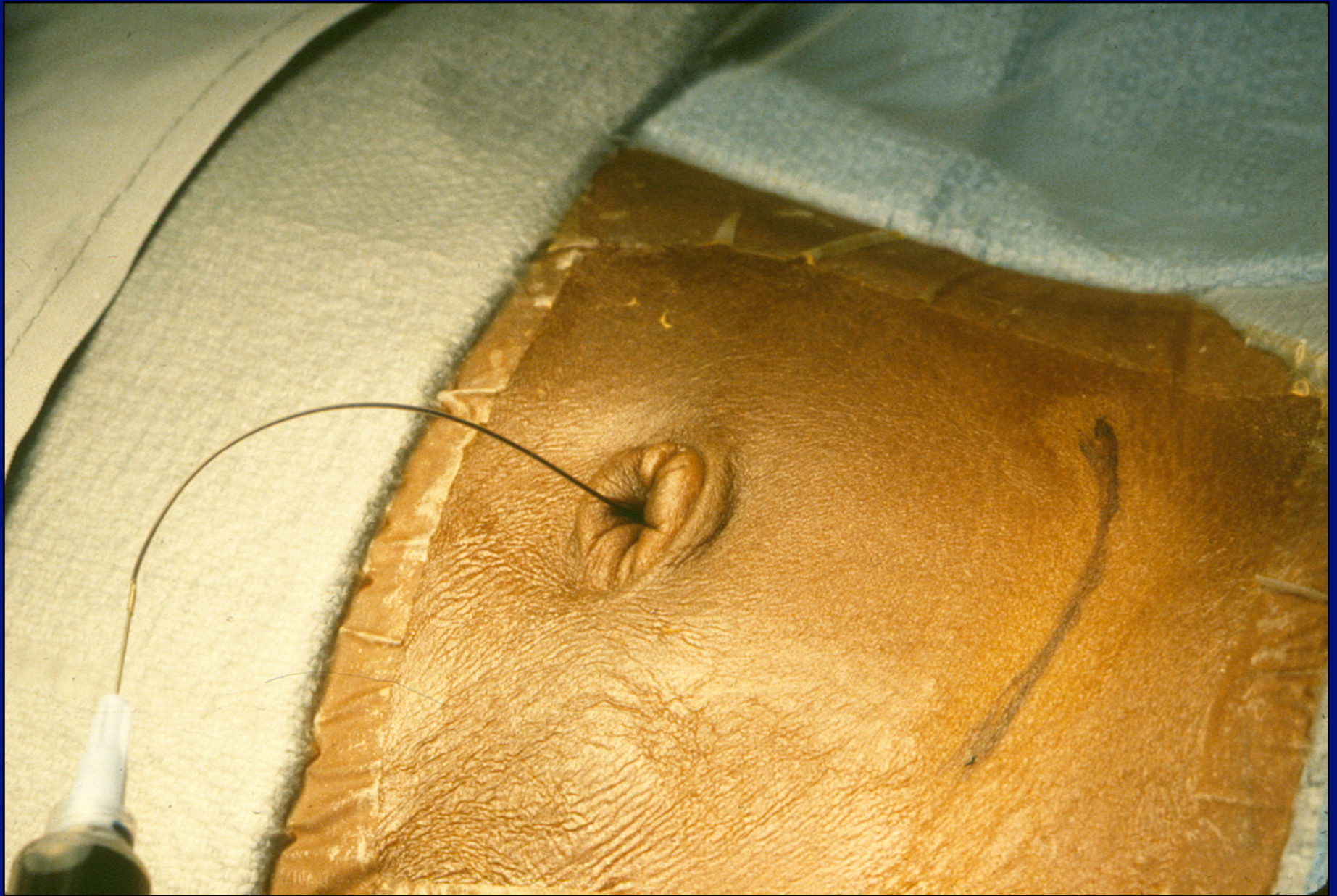


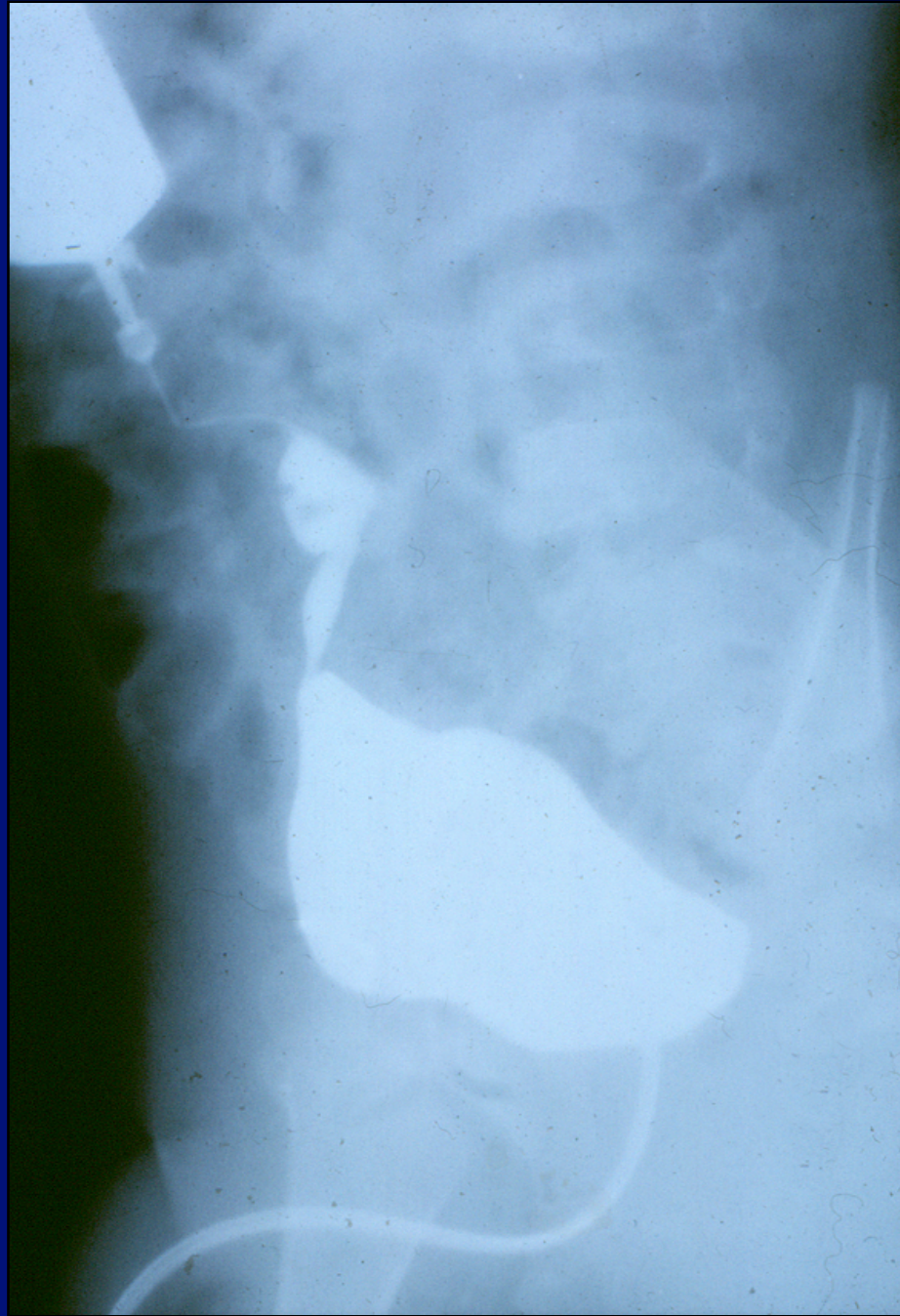
# ***Urachal Abnormalities***

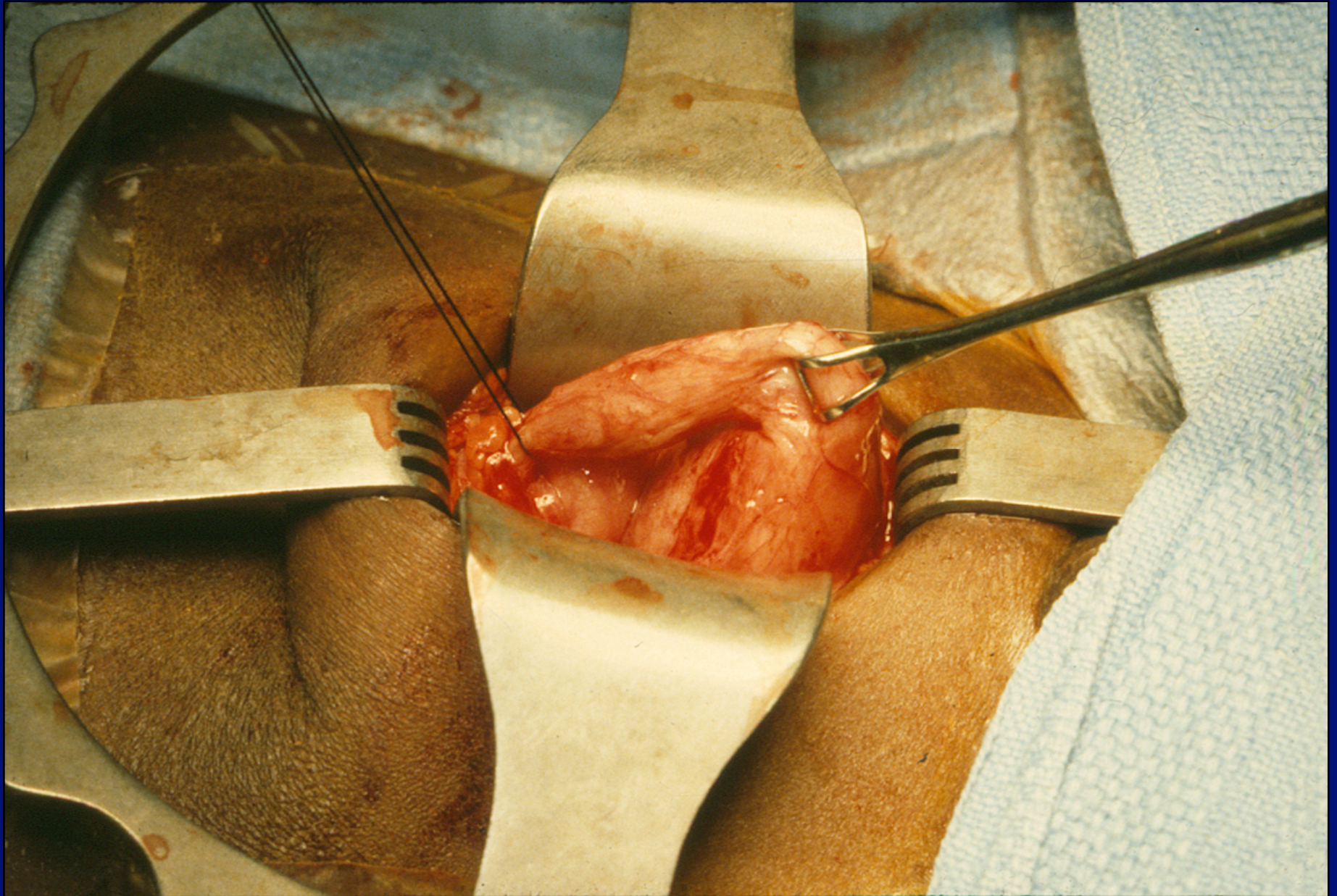


Cloacal endo-  
derm penetrates inferior aspect  
of genital tubercle to form ure-  
thral plate: a, genital tubercle;  
b, primitive urogenital sinus; c,  
urethral plate; d, hindgut; e,  
primitive urethral groove; f,  
cloacal membrane; g, cloaca.

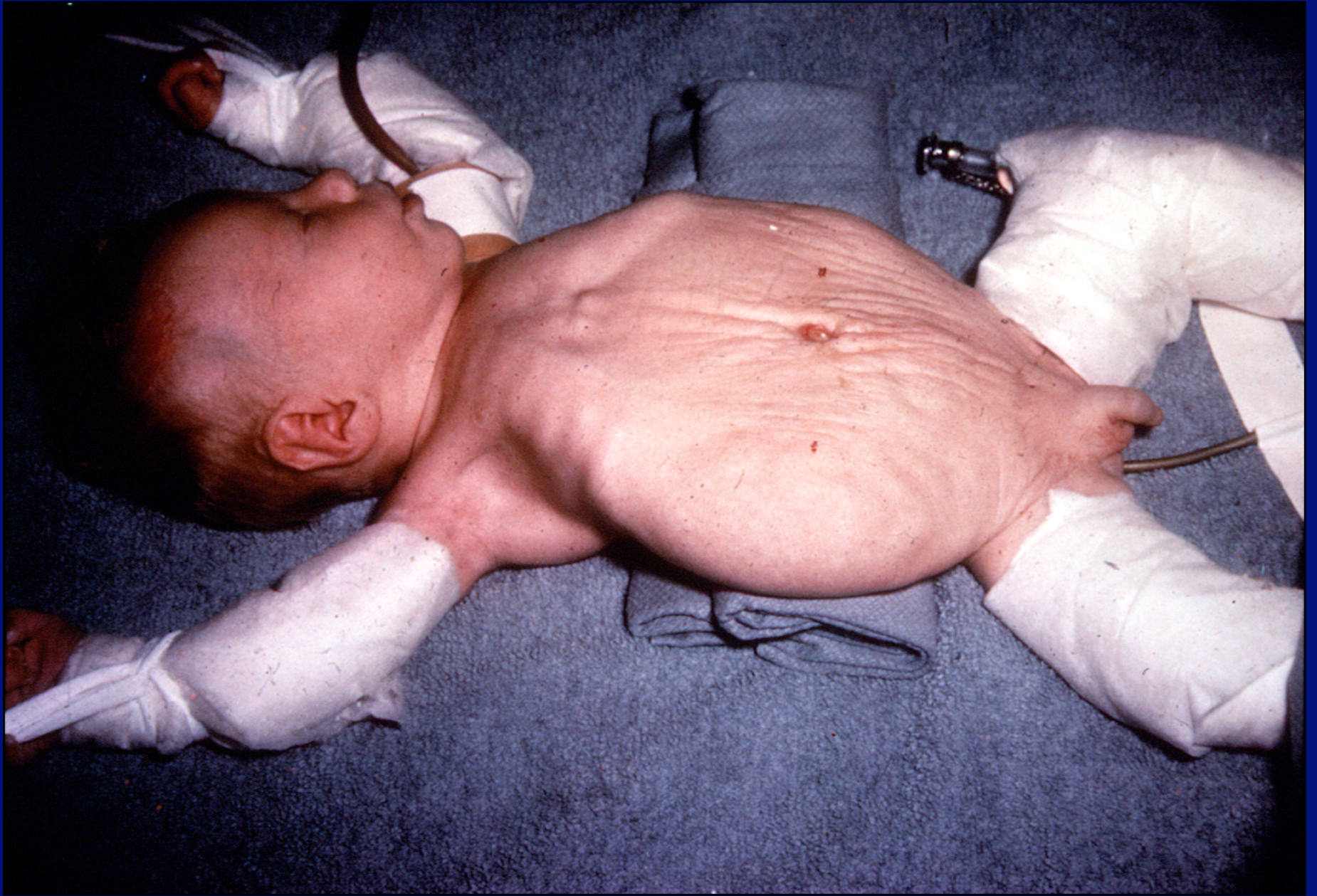




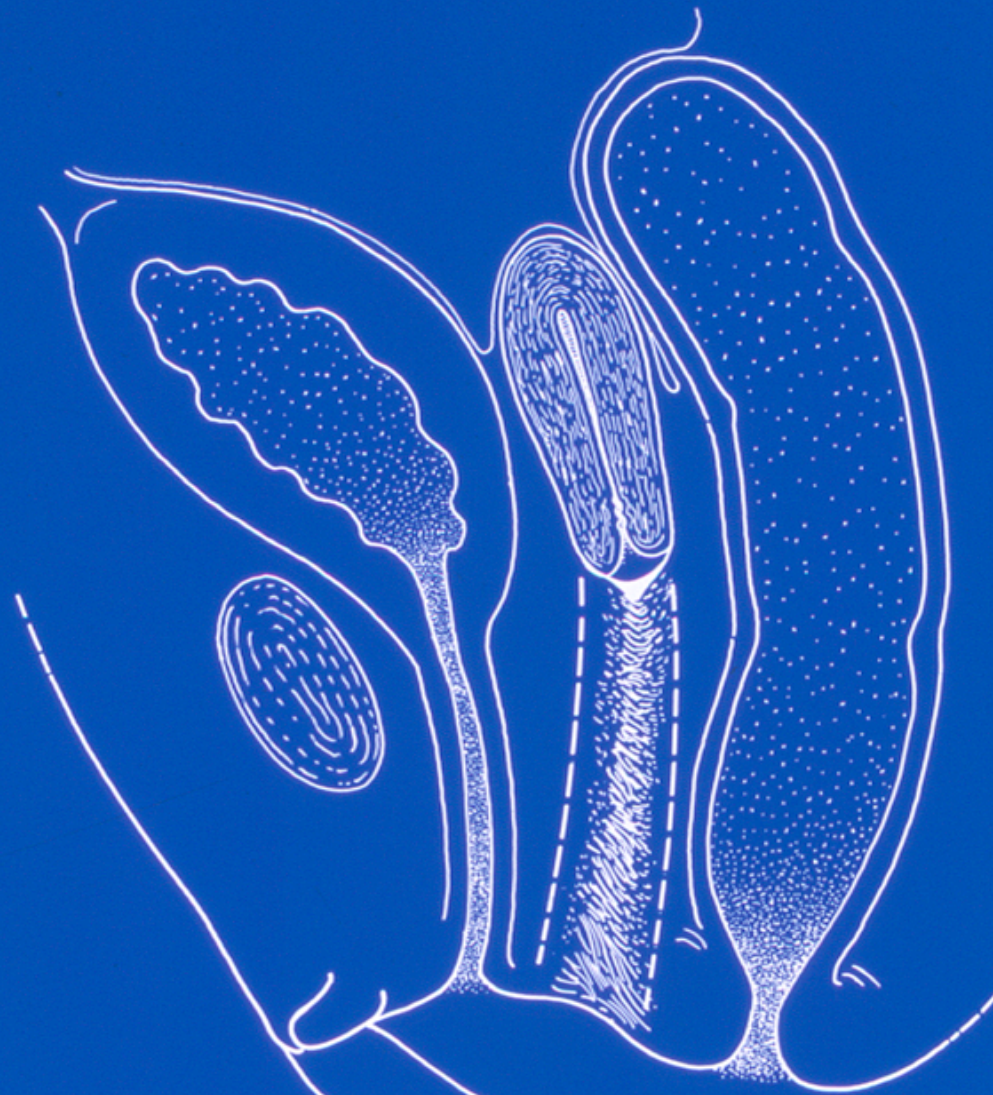



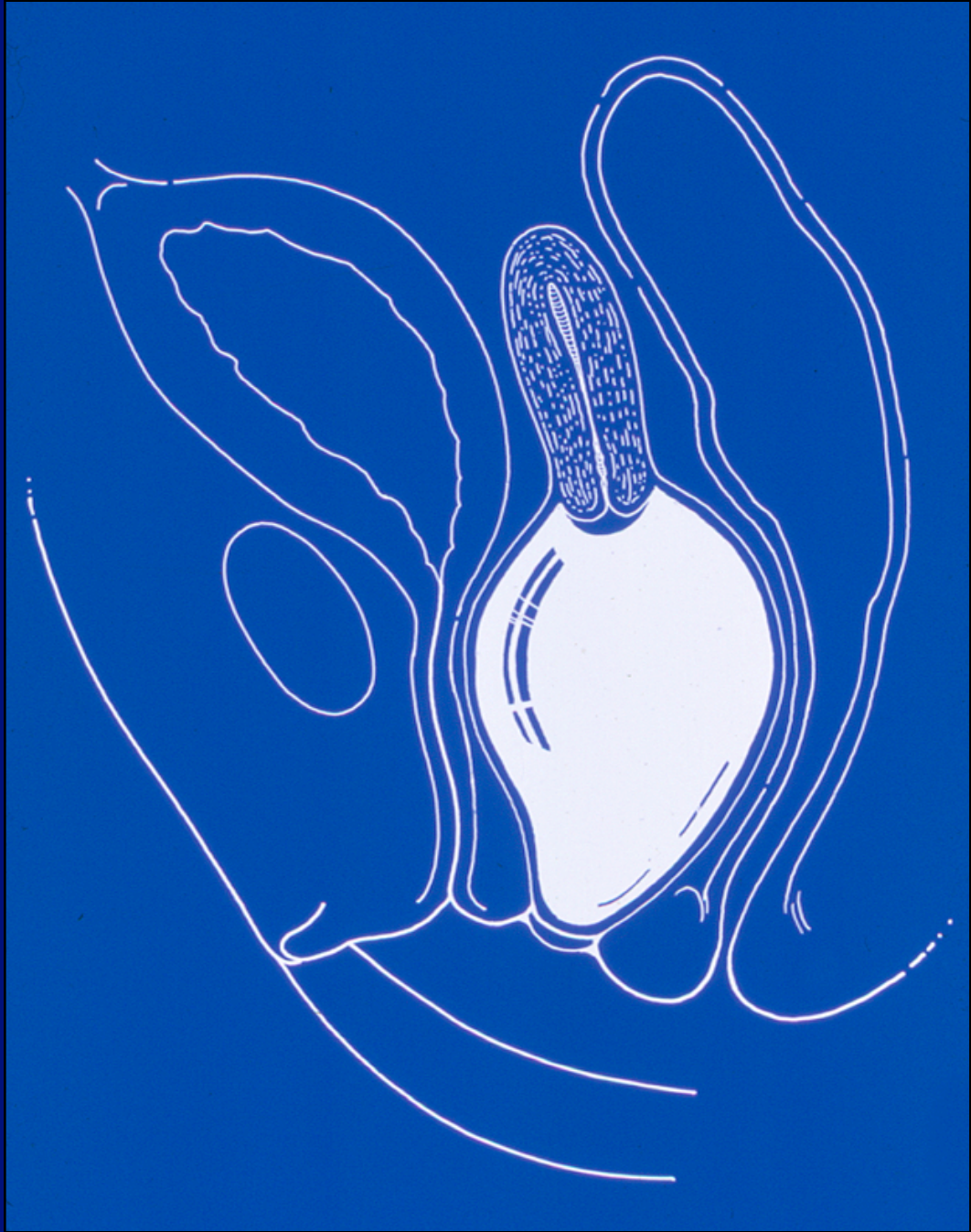
# ***Prune Belly Syndrome***

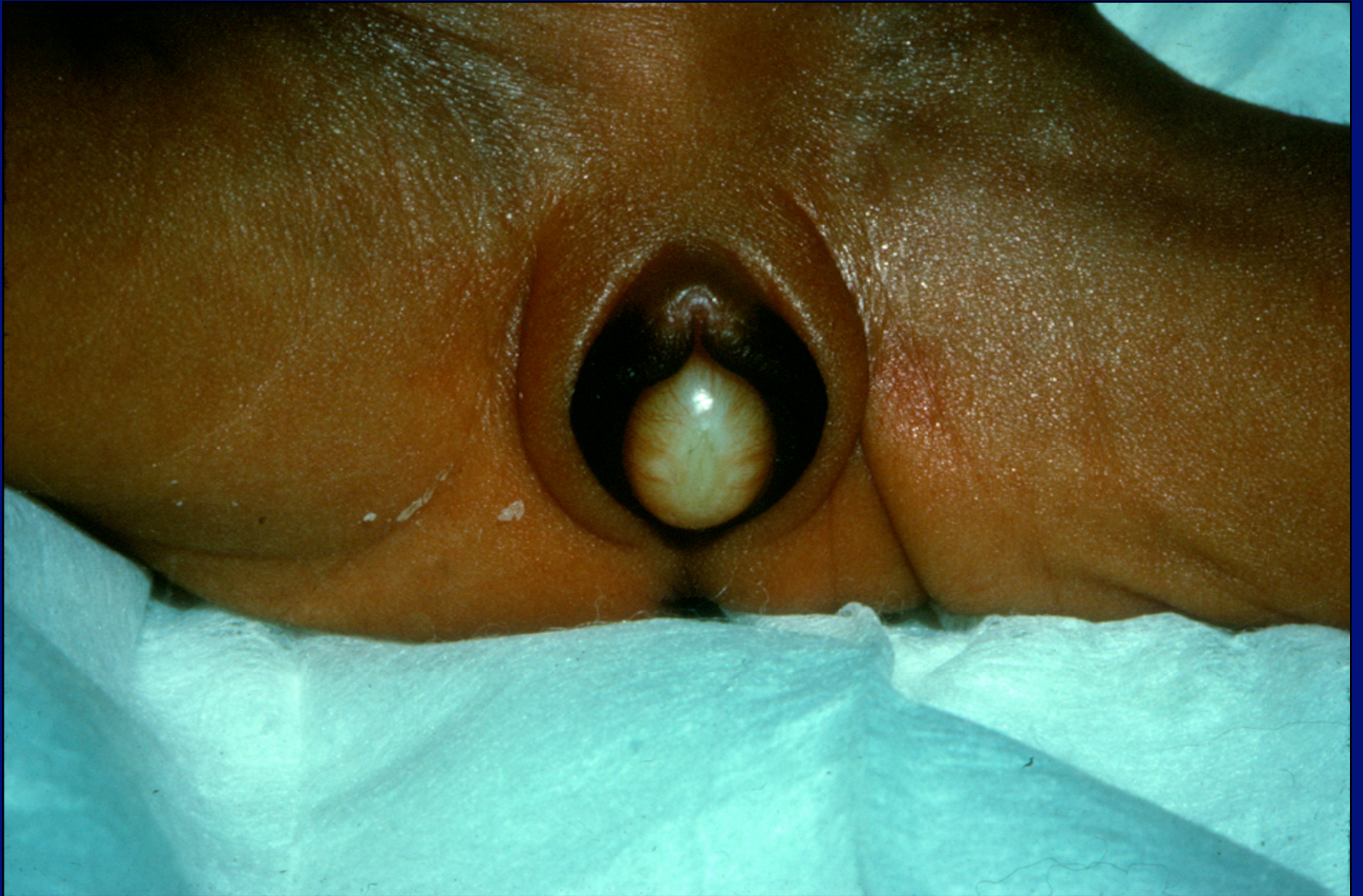

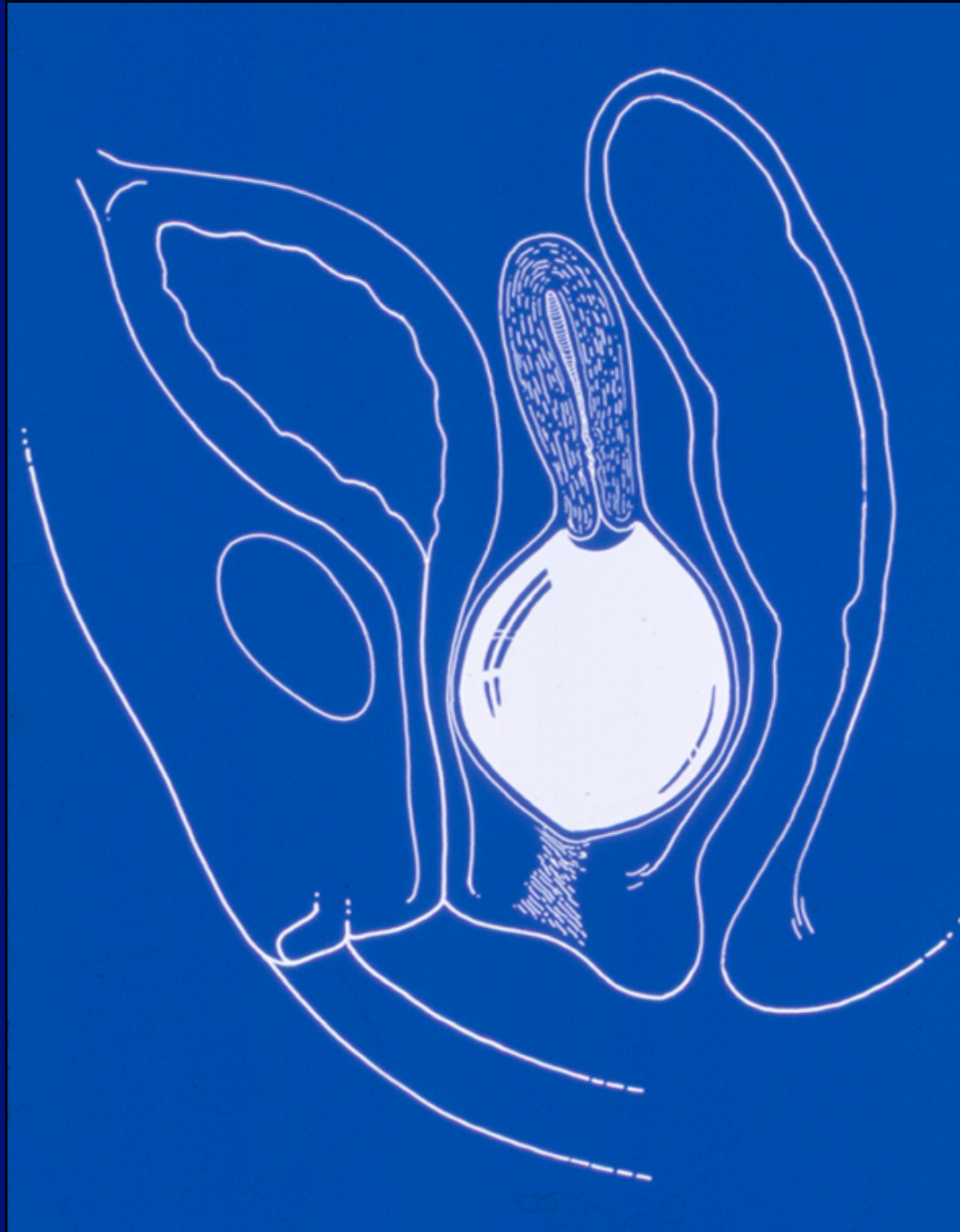
***Anomalies of  
Vaginal Plate Canalization***

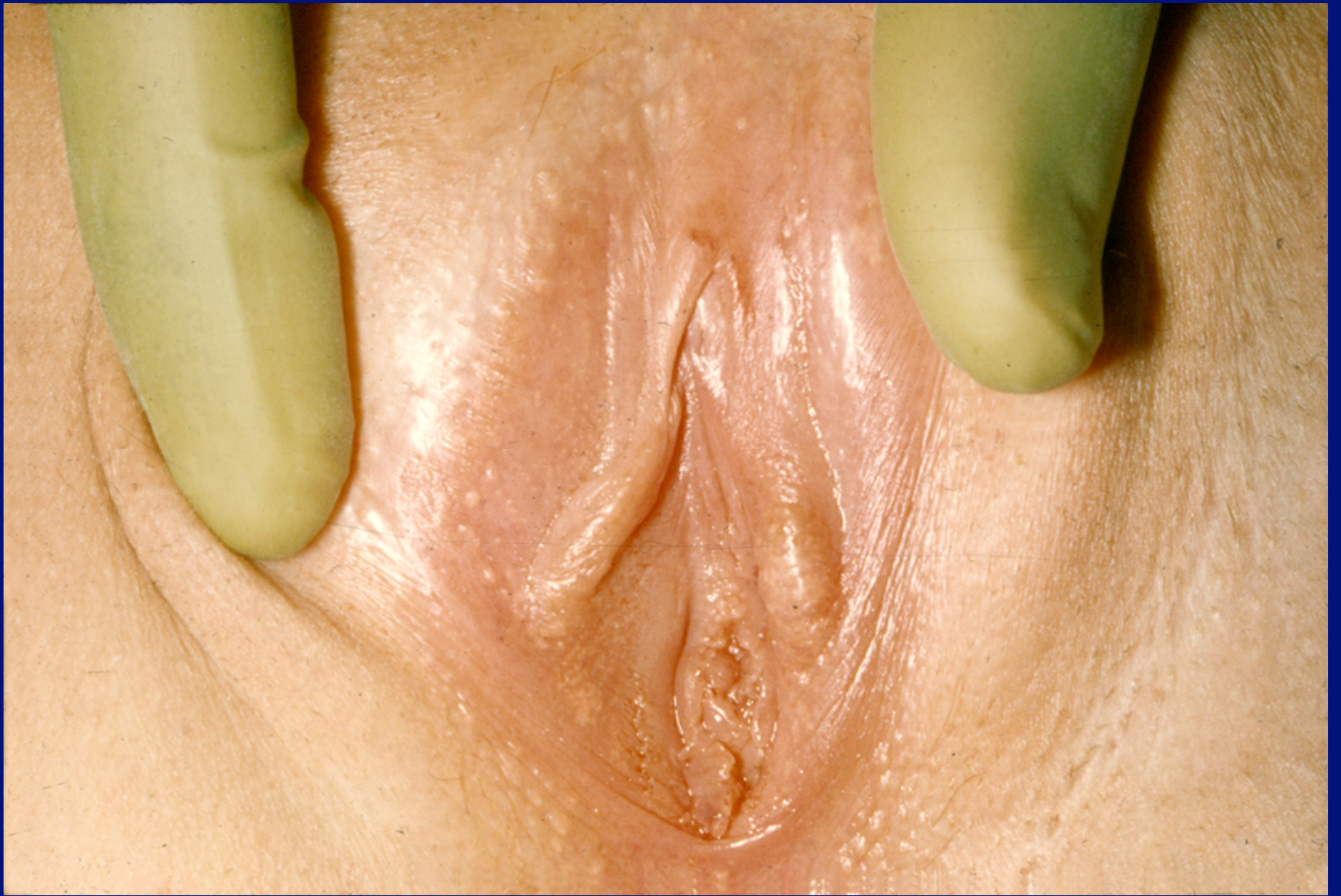

CANALIZATION OF  
OF VAGINAL PLATE

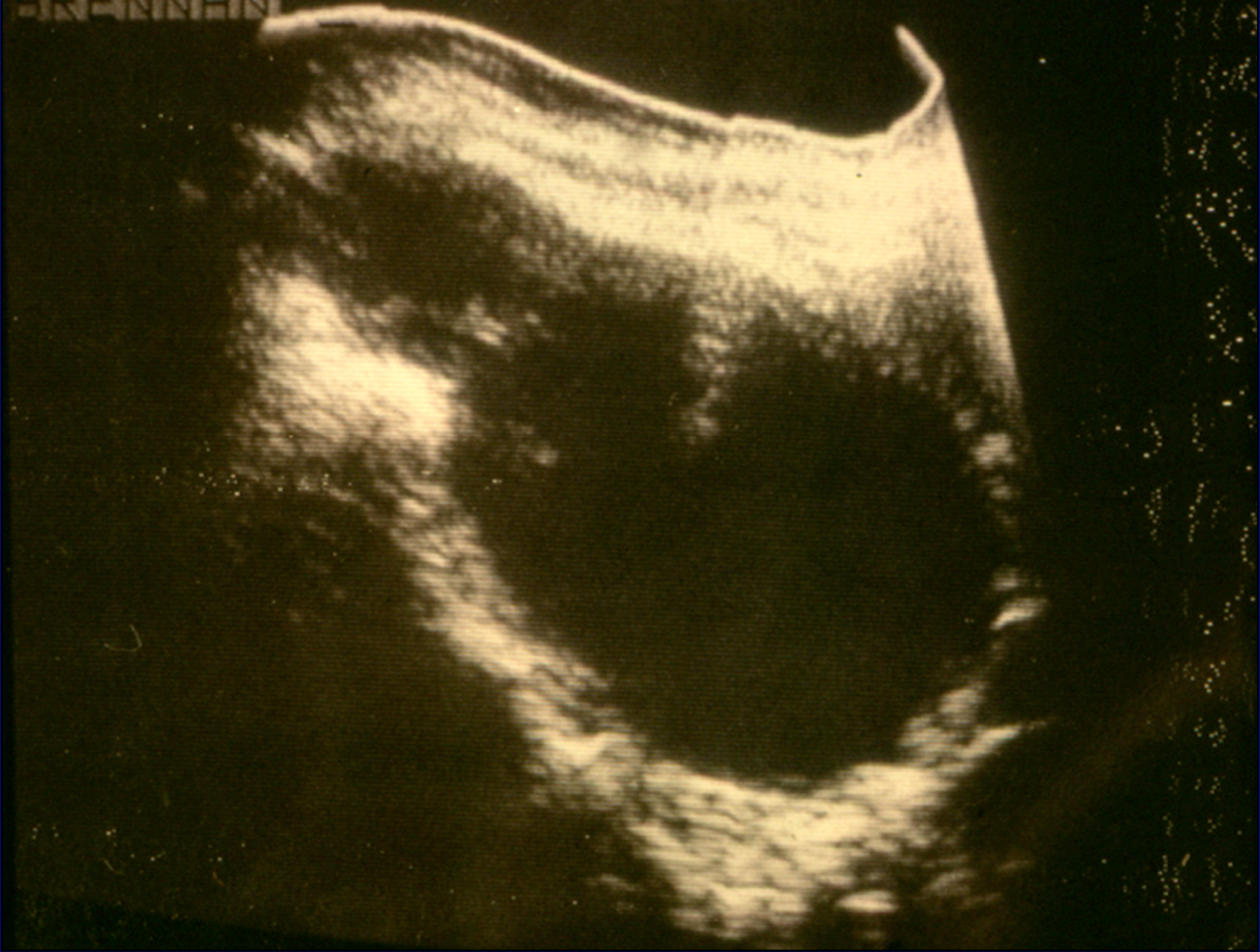


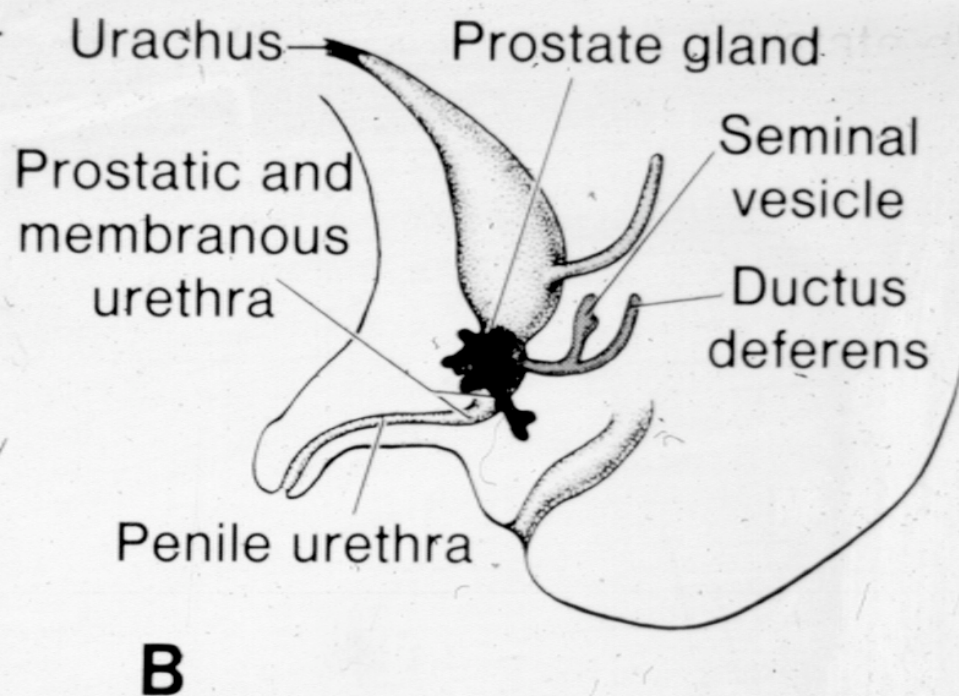
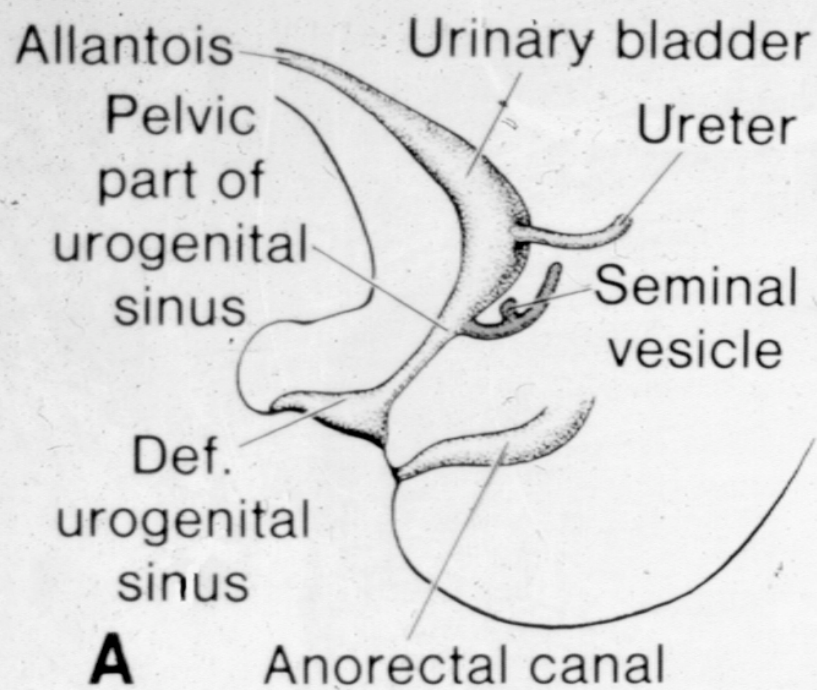


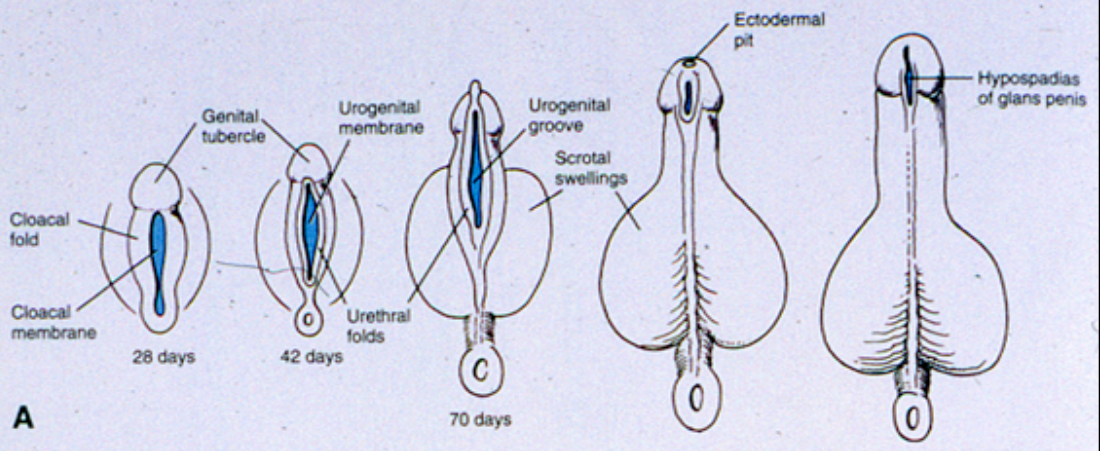




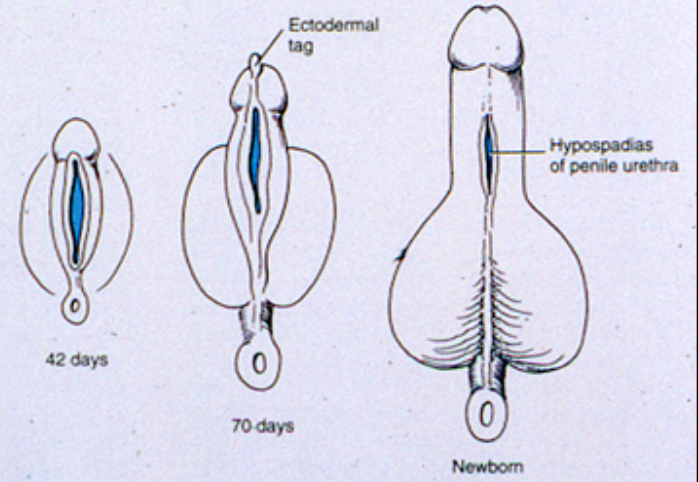
12-11-2011





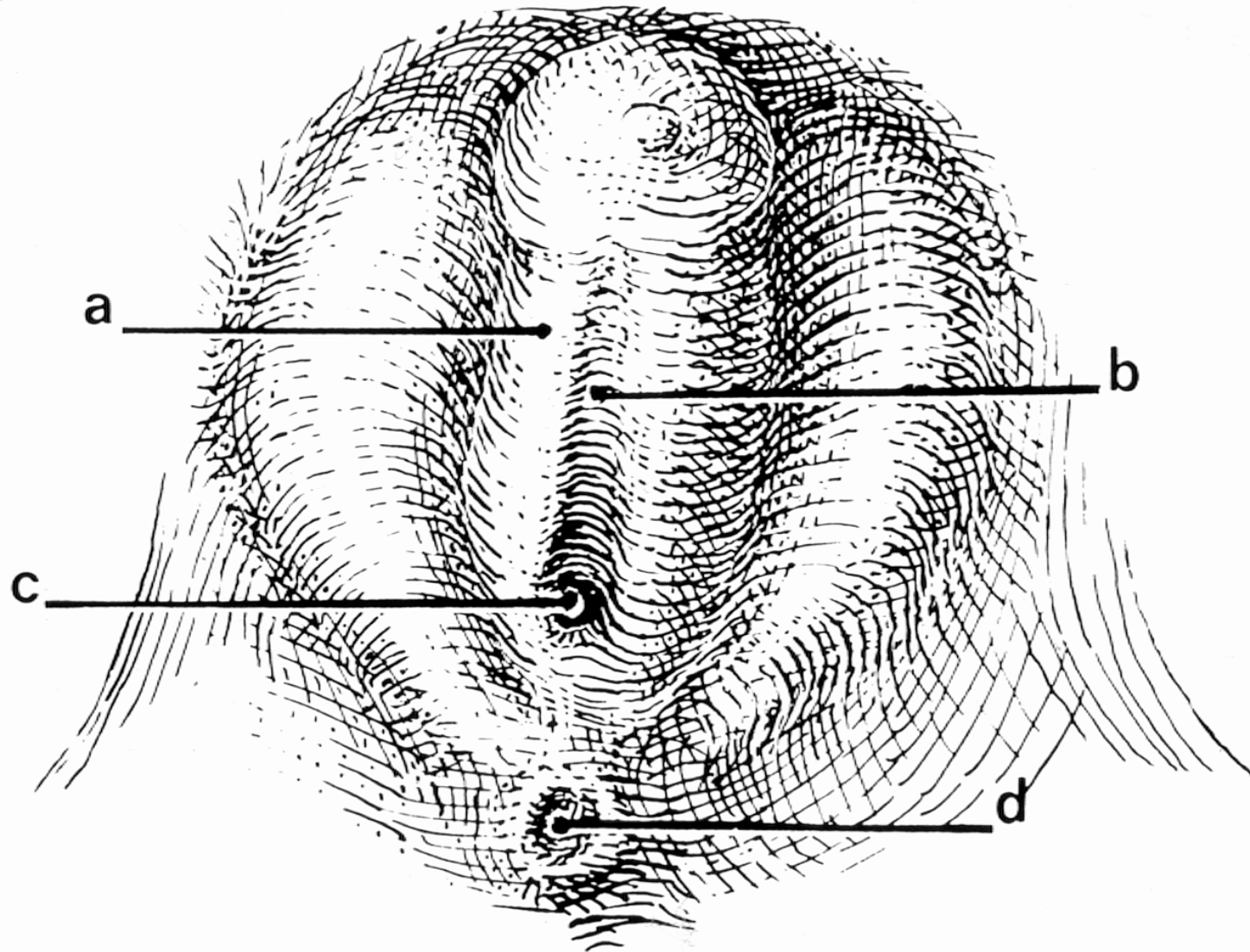


**A**

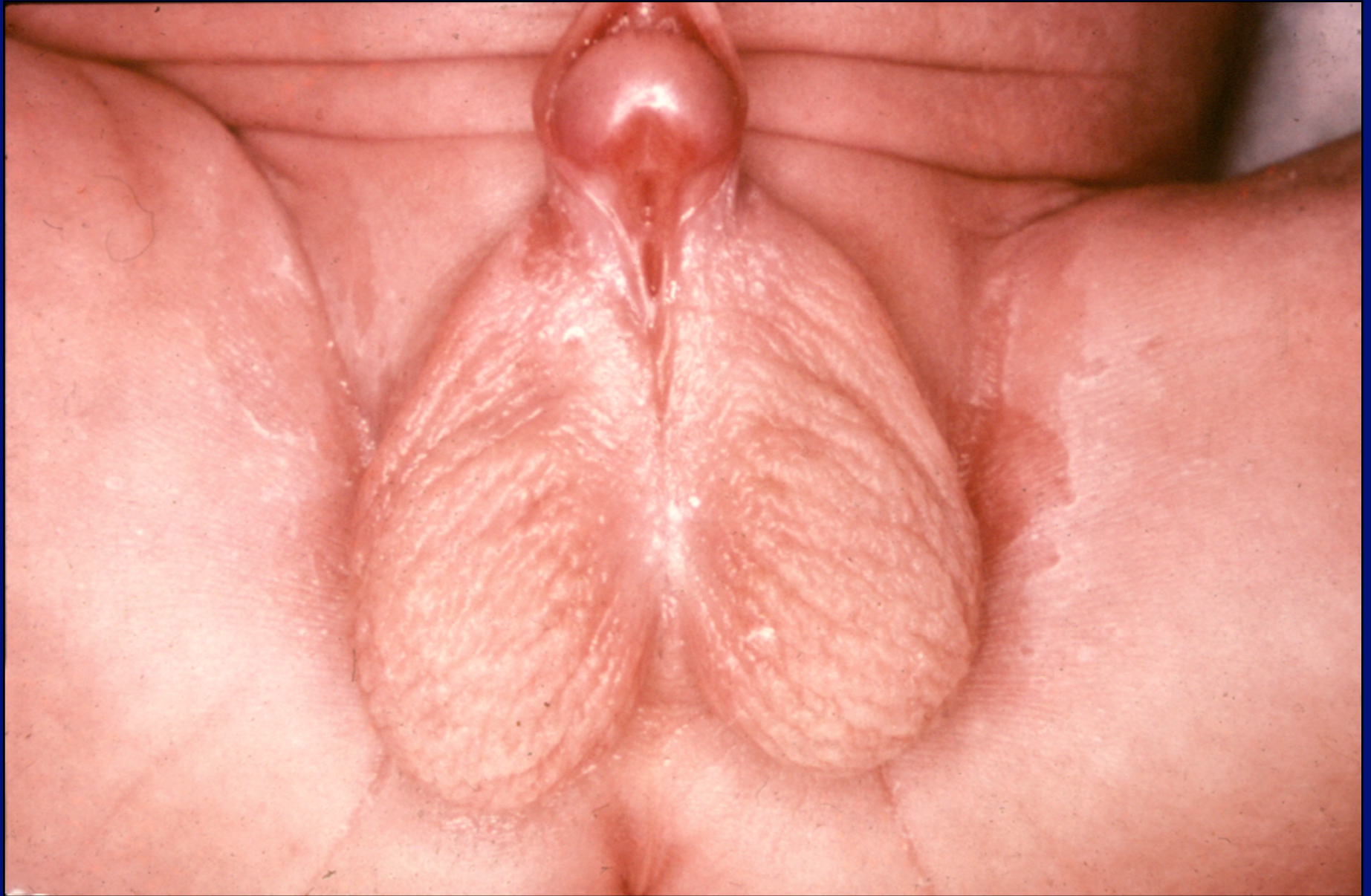

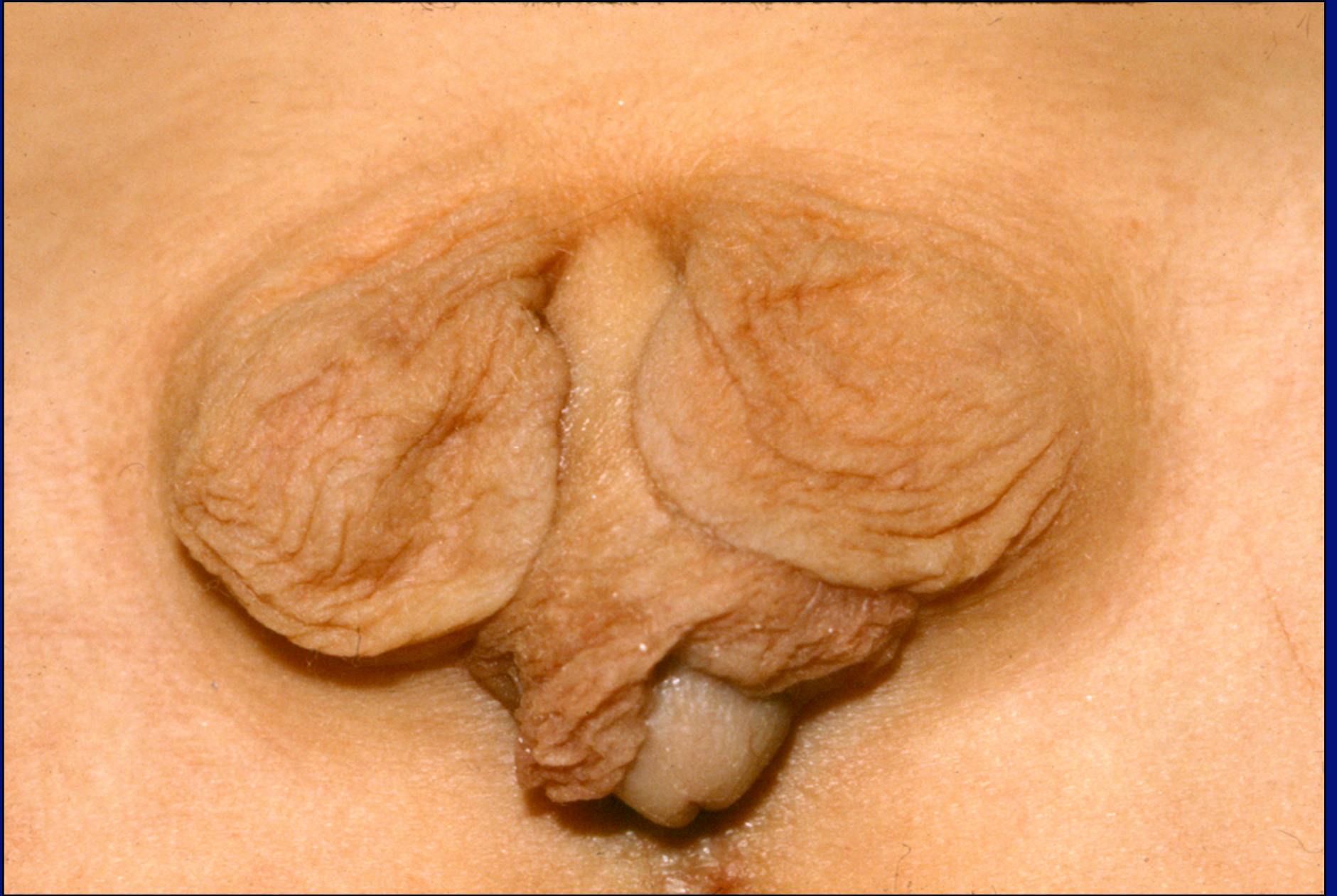**B**

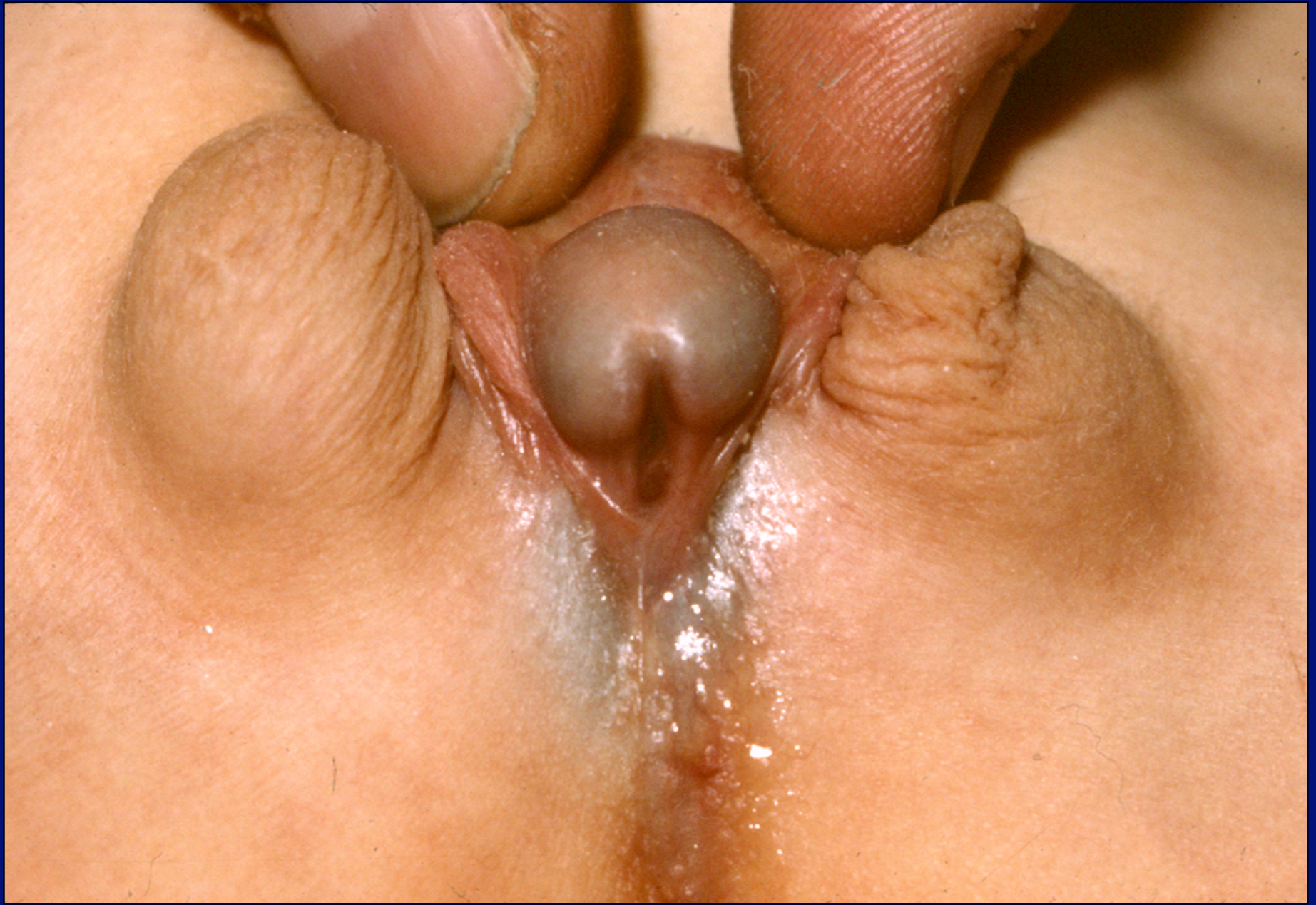# *Hypospadias*



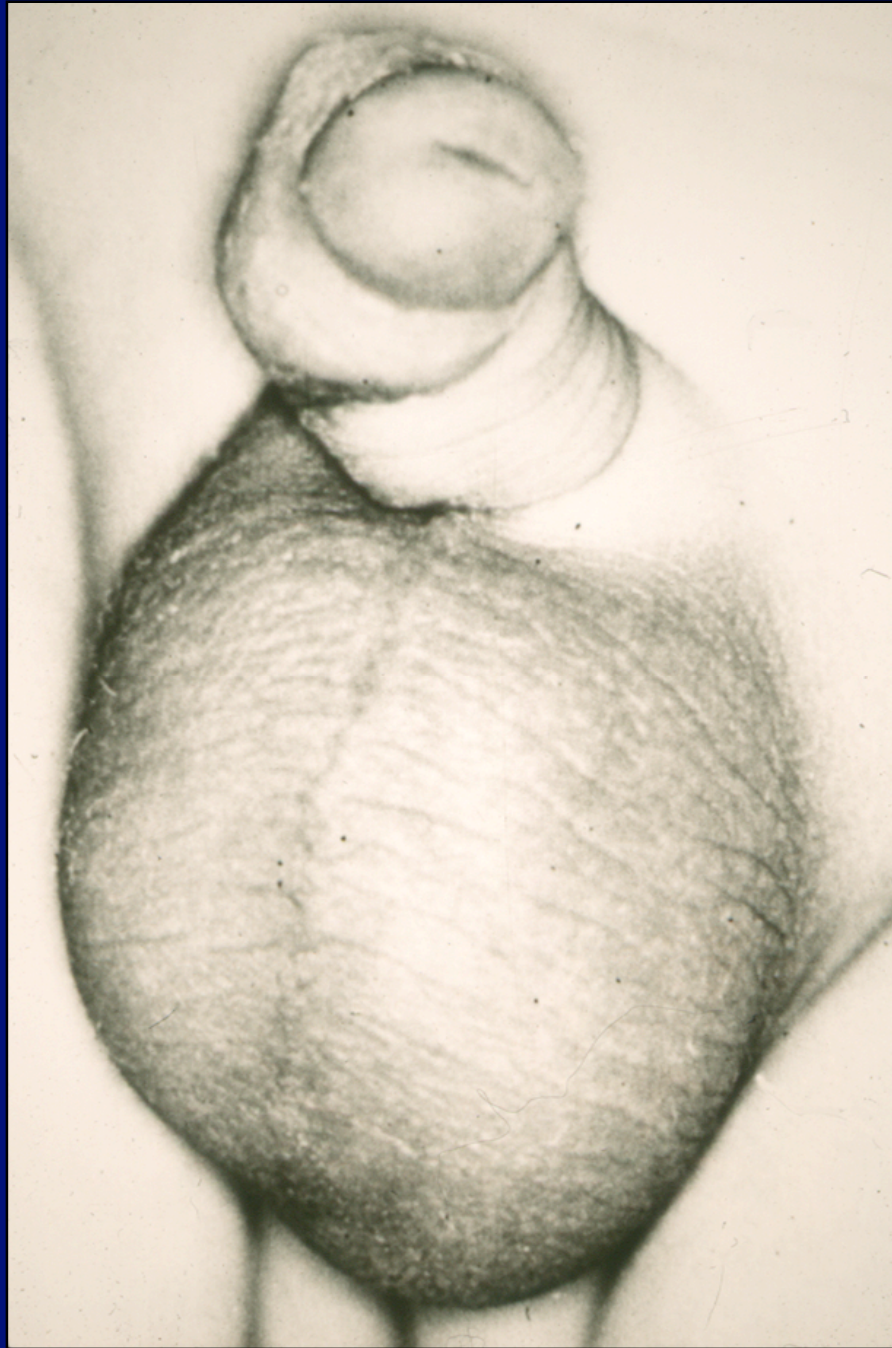
External genitalia after cloacal division: a, urethral fold; b, primitive urethral groove; c, urogenital sinus opening; d, anal membrane.

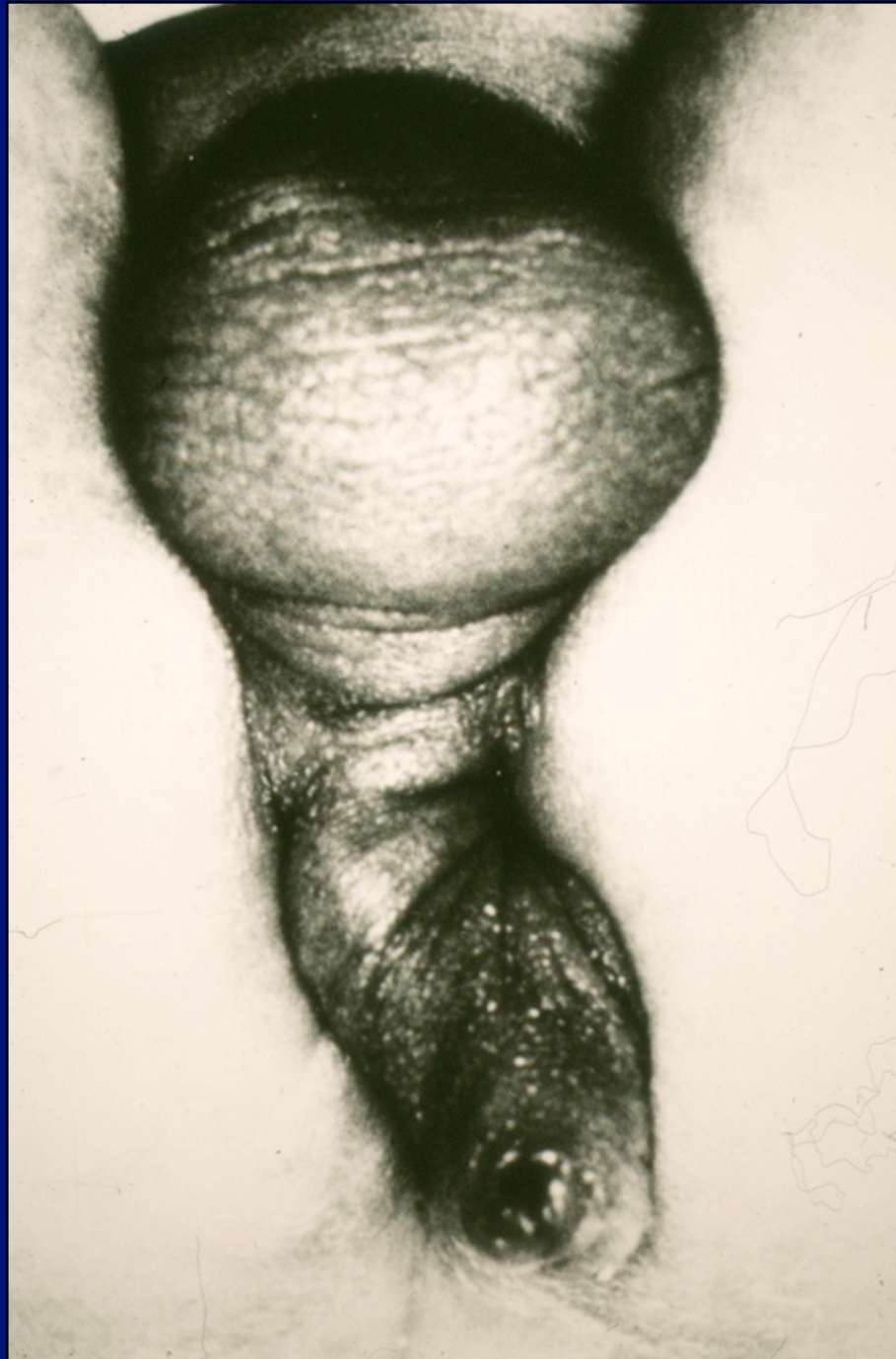


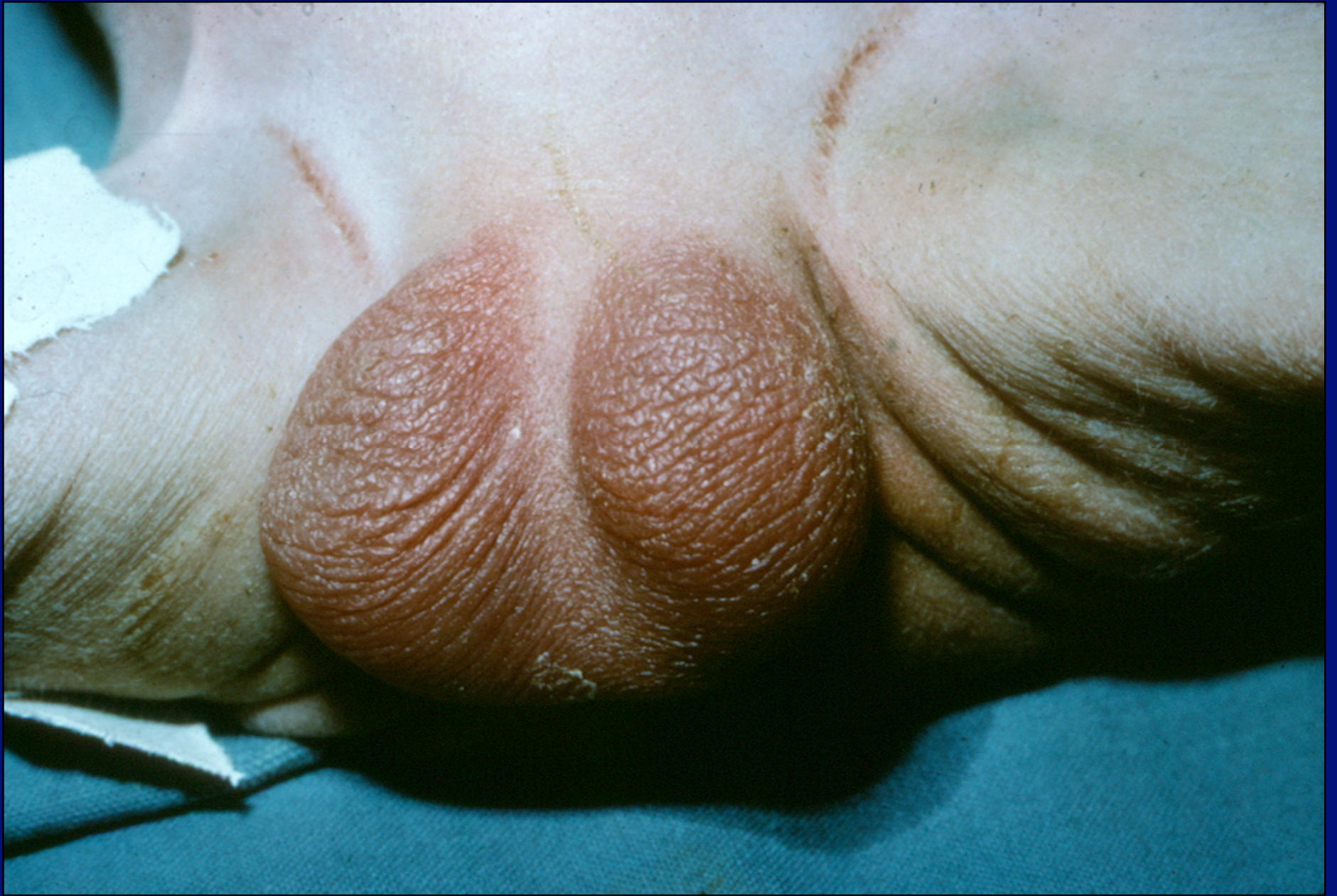


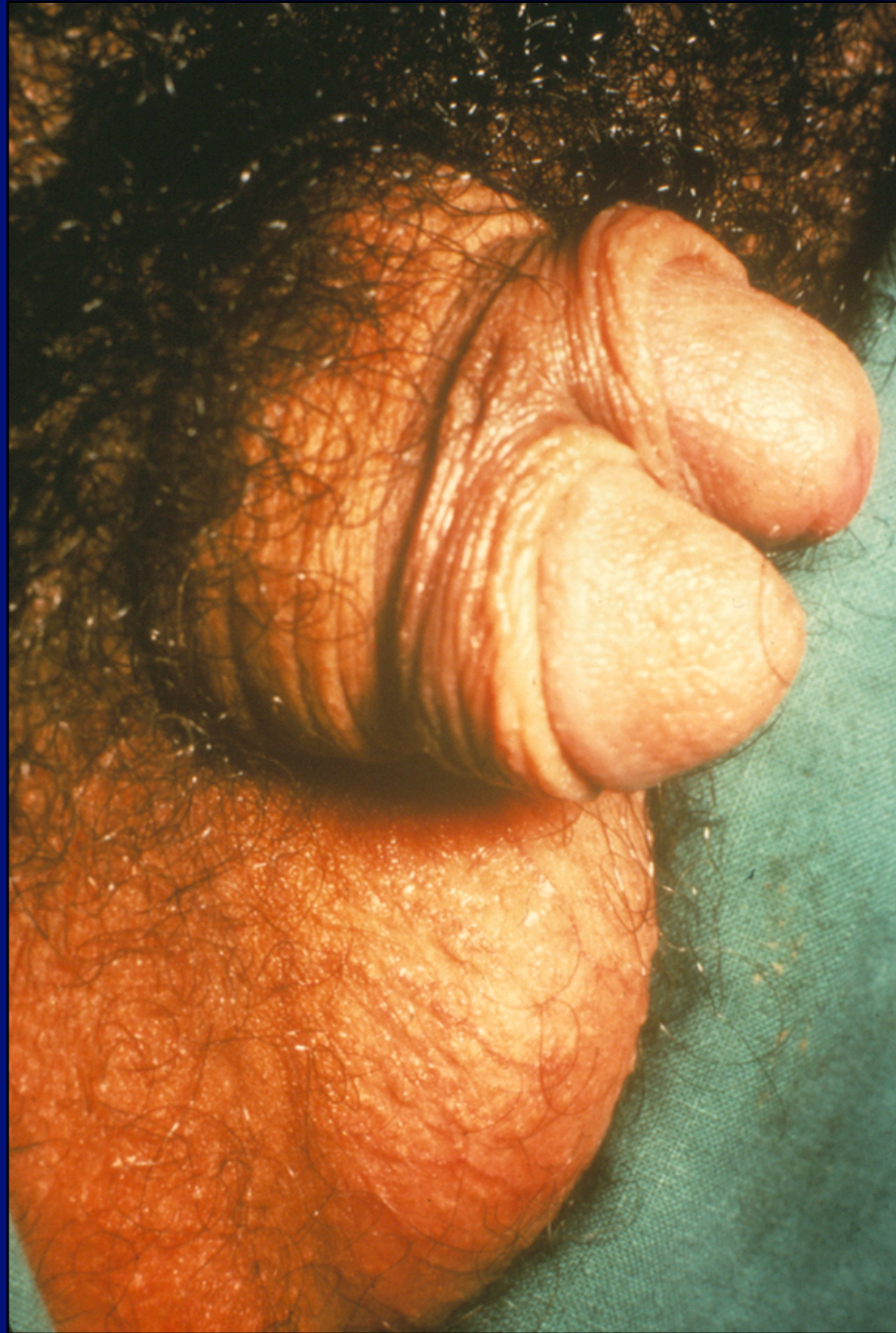













*WHICH CAME FIRST?*

# Urinary System Abnormalities

<u>ANOMALY</u>	<u>GESTATION</u>	<u>ETIOLOGY</u>
Bladder duplication	3 weeks	Notochord Duplication
Agensis of Vas and Seminal Vesicles	3 - 4 weeks	Mesonephric duct abnormality
Agensis of penis	4 weeks	Genital tubercle defect
Obstructive megaureter	4 weeks	Mesonephric duct abnormality
Uteral duplication	5 weeks	Ureteral bud defect

# Urinary System Abnormalities

<u>ANOMALY</u>	<u>GESTATION</u>	<u>ETOLOGY</u>
Exstrophy- Epispadias	5 - 6 weeks	Cloacal membrane anomaly
Ectopic Ureter	5 - 6 weeks	Ureteral bud defect
Imperforate Anus	6 weeks	Failure of urorectal septum
Ureterocele	7 - 8 weeks	Persistence of Chwalle's membrane
Posterior urethral valves	8 weeks	Persistence of Muller's tubercle

# Urinary System Abnormalities

<u>ANOMALY</u>	<u>GESTATION</u>	<u>ETOLOGY</u>
Hypospadias	8 weeks	Failure of urethral groove
Urachal Abnormalities	9 weeks	Persistent allantois
Prune Belly Syndrome	12 weeks	Secondary failure of mesoderm
Undescended Testis	7 months	Failure of end organ response