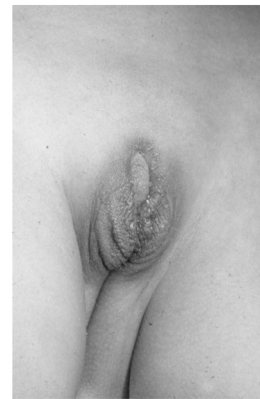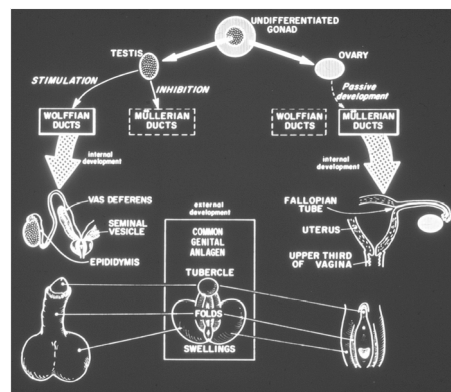


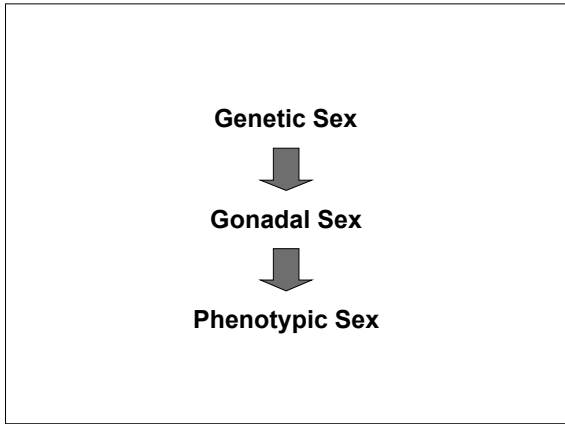
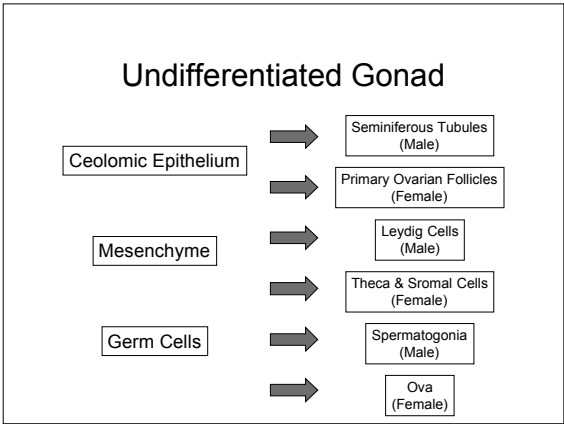
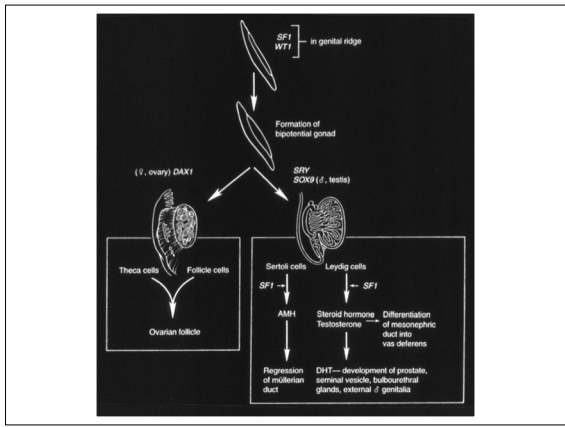
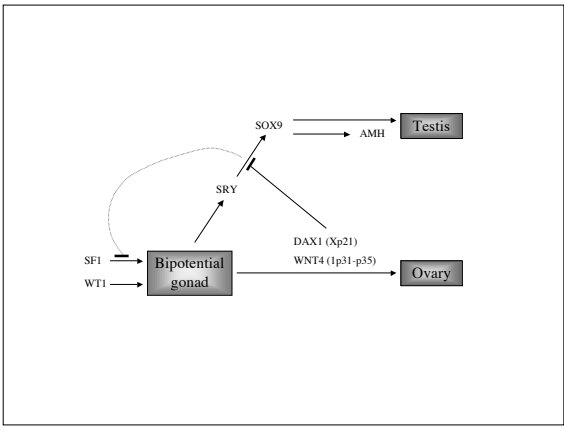
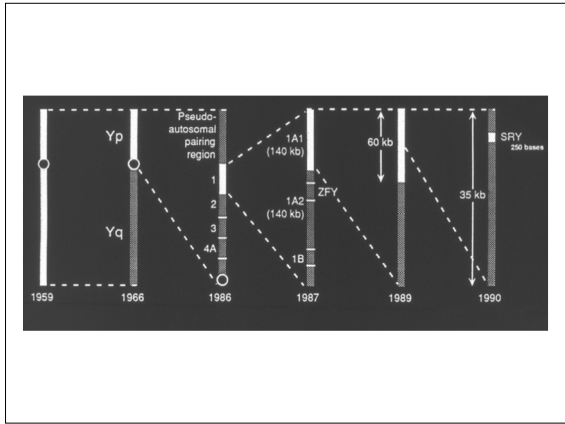
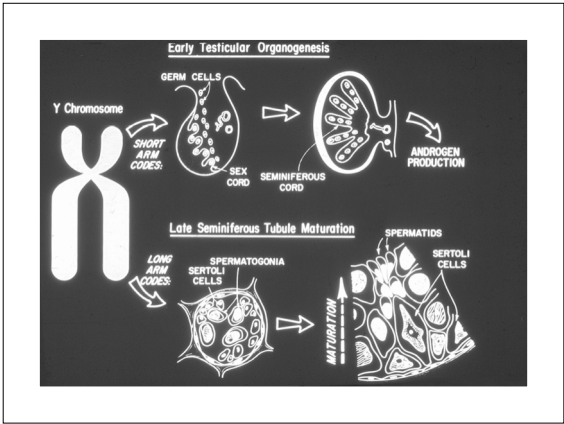
Sex

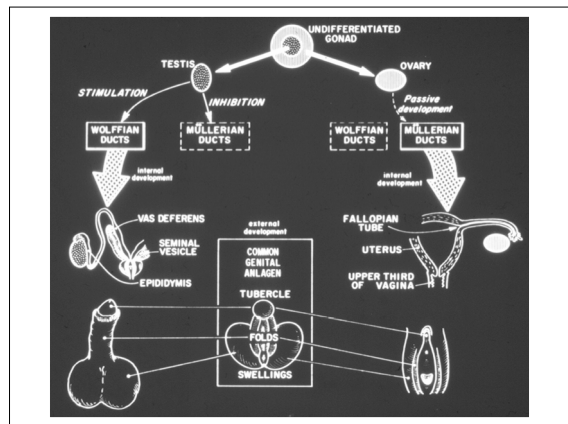
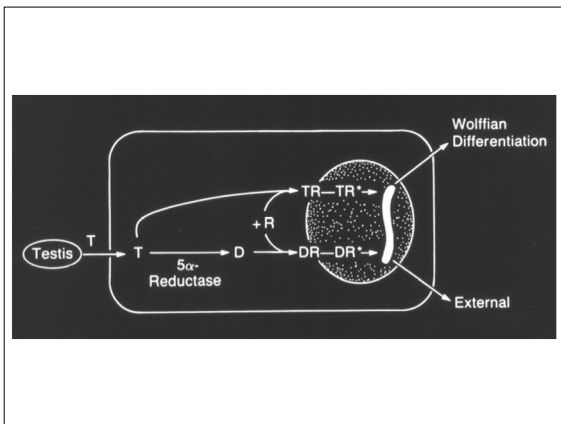
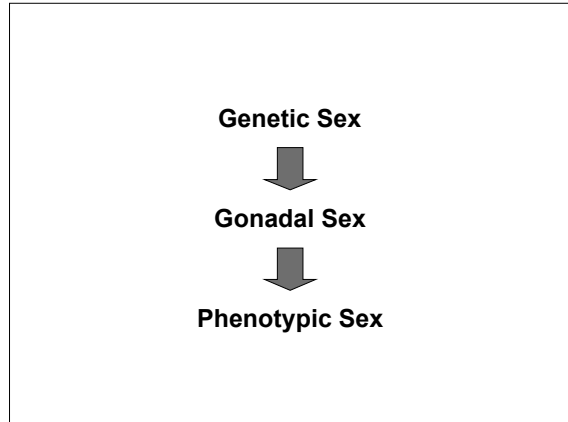
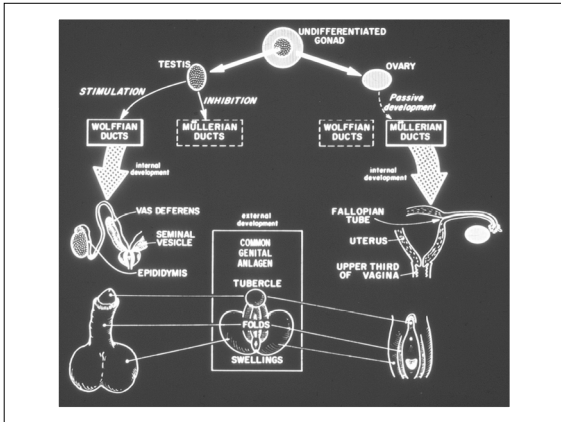
Sex



Genetic Sex  
↓  
Gonadal Sex  
↓  
Phenotypic Sex







- ### Genetic Control of Male Phenotype
- Y Chromosome
    - Testicular Differentiation
  - X Chromosome
    - End Organ Receptor
  - Autosome
    - Enzymatic Control of Testosterone Biosynthesis
    - Conversion of I to DHT
    - Control of MIS Action

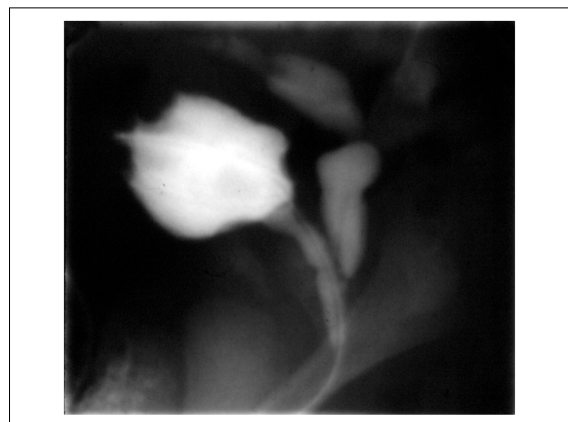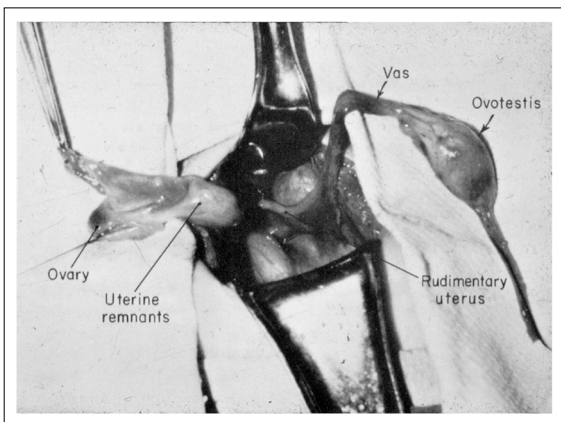
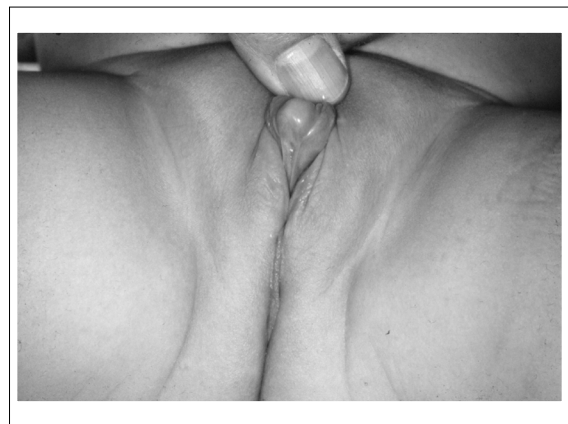
- ### Intersex Questions
- What gene is integral in development of the bipotential gonad from the urogenital ridge?
  - What gene is responsible for differentiation of the bipotential gonad into fetal testis?
  - What is the major androgen of the fetal testis?
  - What is the timing of its action?
  - What stimulates fetal testis to produce androgen?
  - What is the receptor site in fetal testis?
  - What causes differentiation of external genitalia & U-G Sinus?

## Intersex - Differential Diagnosis

- True Hermaphrodite
- Mixed Gonadal Dysgenesis
- Female Pseudohermaphrodite
- Male Pseudohermaphrodite

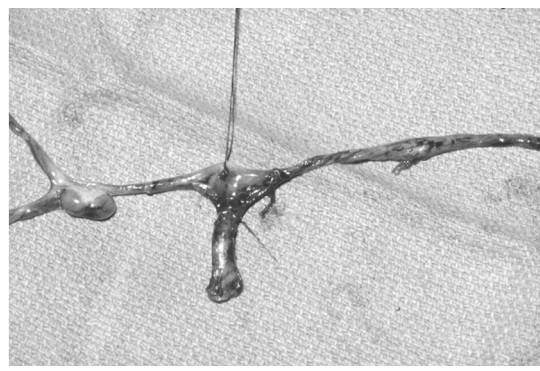
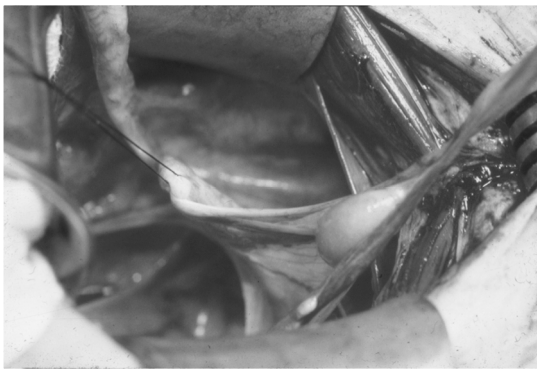
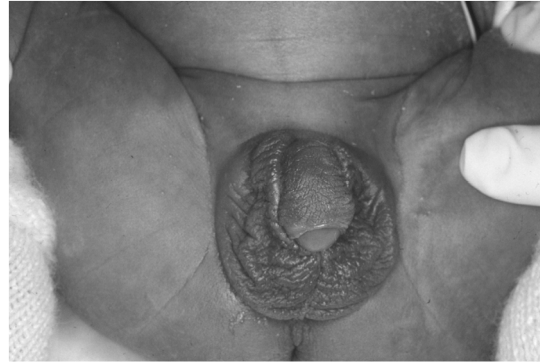
## True Hermaphrodite

- 60% Look Male
- Most Will Have at Least a Rudimentary Vagina
- Internal Duct Structures Will Correspond to the Gonad on the Ipsilateral Side

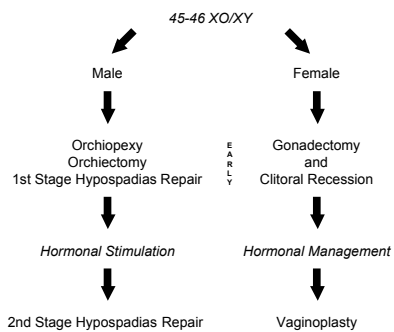


## Mixed Gonadal Dysgenesis

- 45 XO/XY
- Streak+Testis (OVO)
- Poorly Virilized
- Sterile Male
- Short Stature
- High Incidence of Testis Tumor

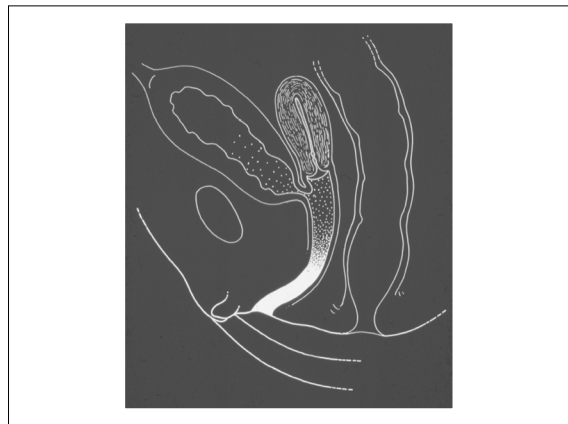
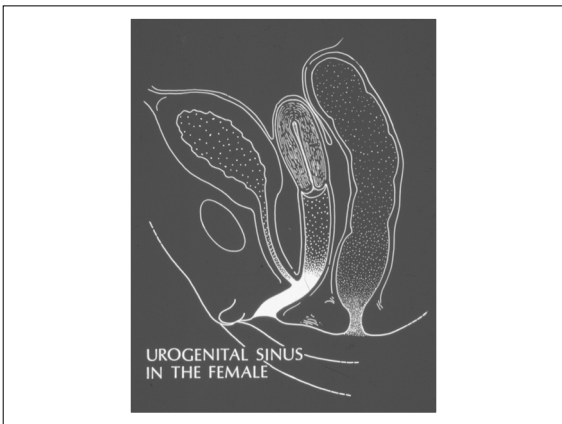
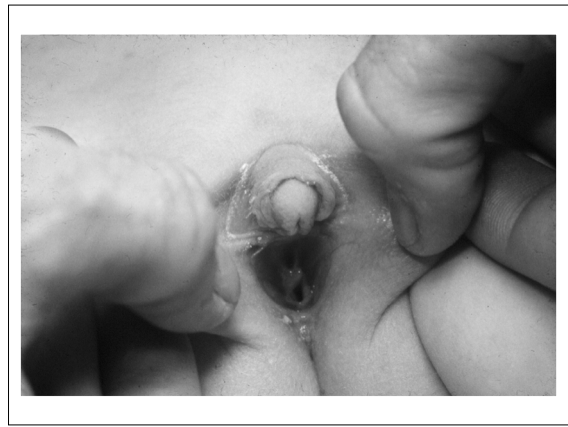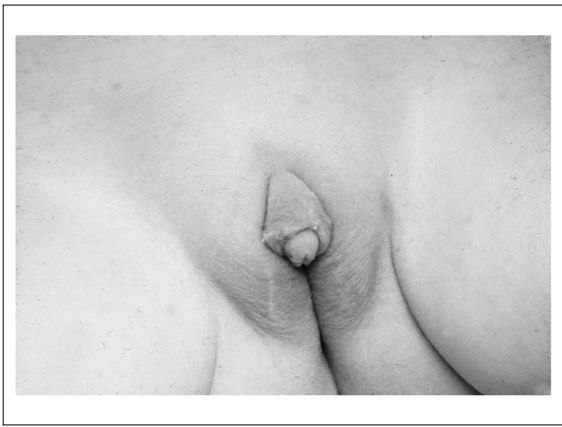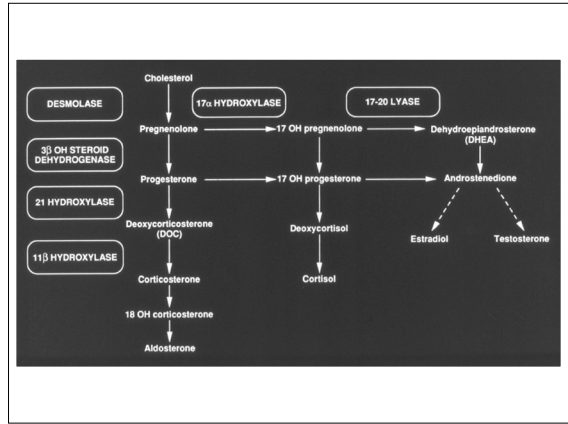
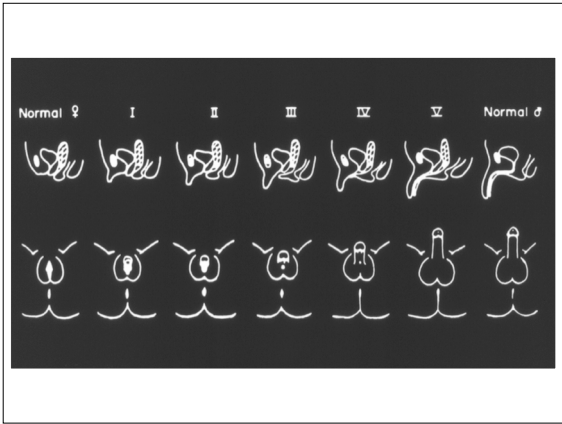


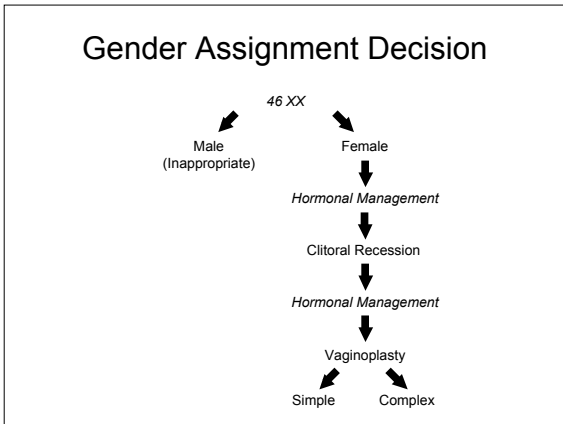
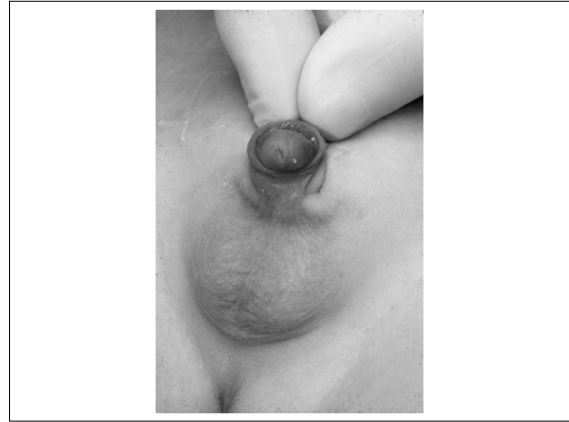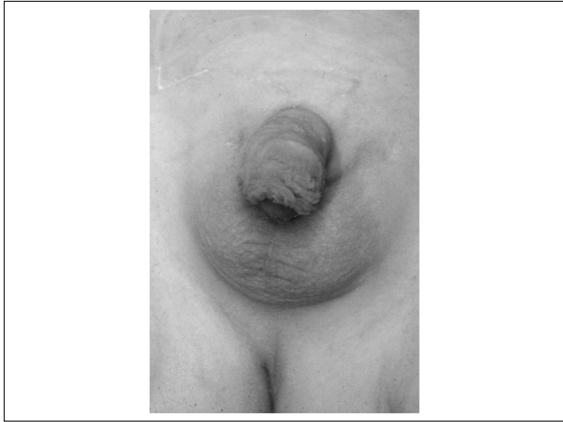## Gender Assignment Decision



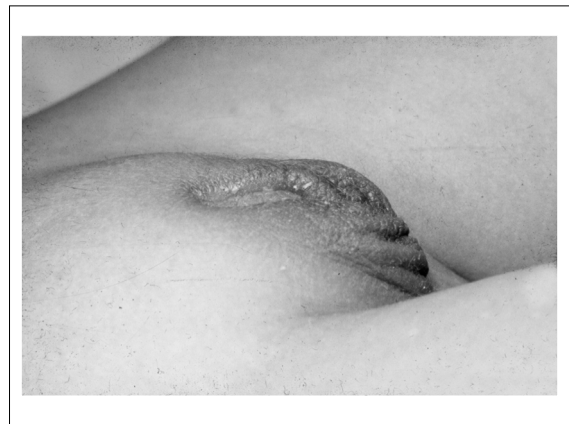
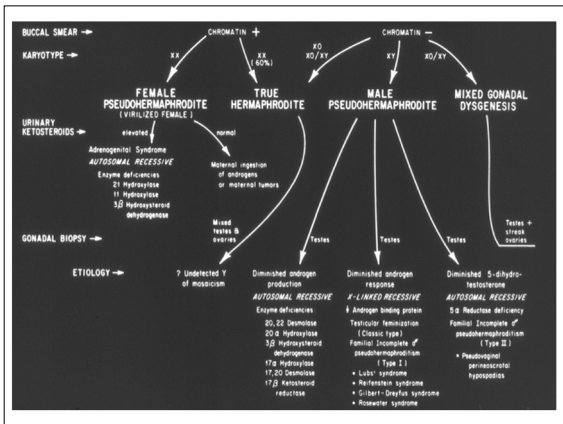
## Female Pseudohermaphrodite

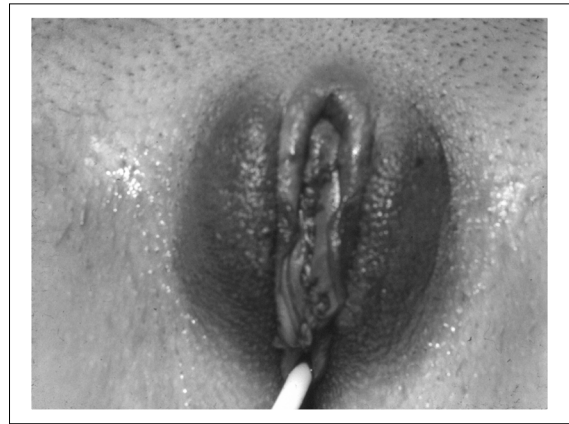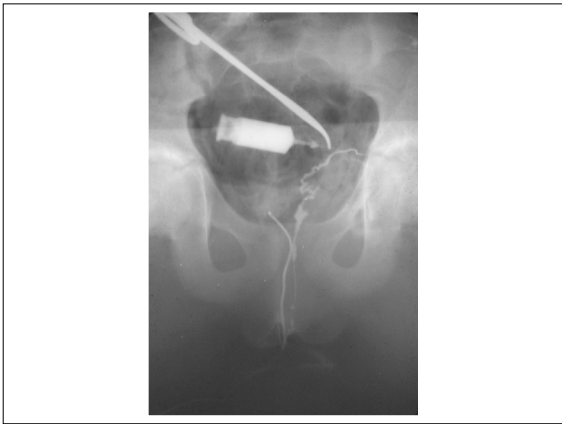
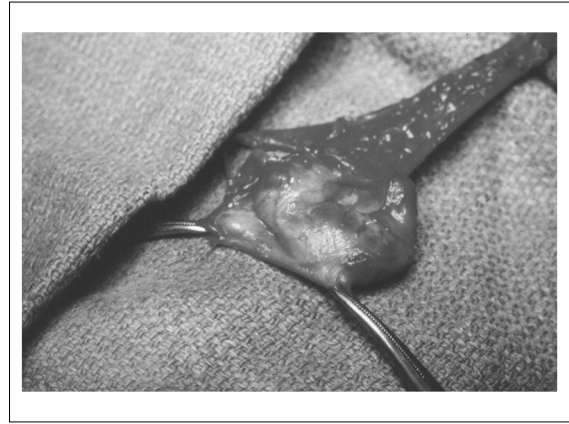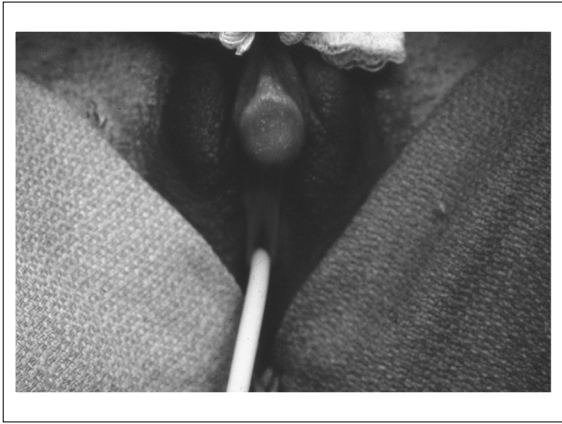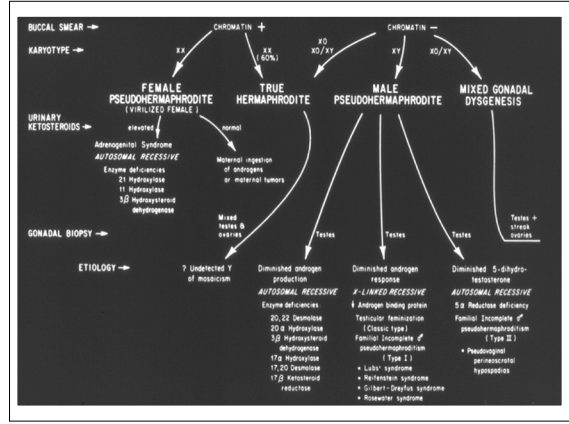
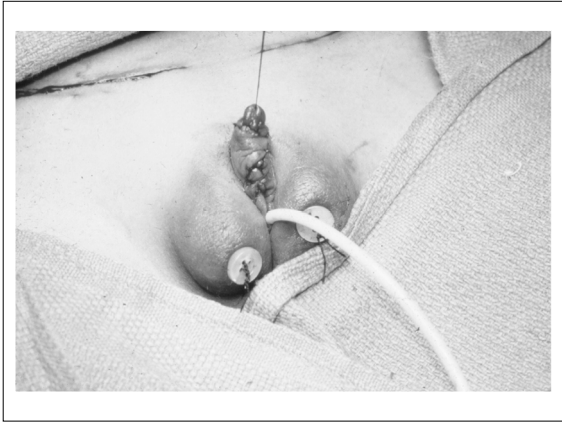
- 46 XX - Virilized
- The Most Common Cause of Ambiguous Genitalia (AGS)
- DX
  - Karyotype
  - Biochemical Markers
  - No Surgery Necessary

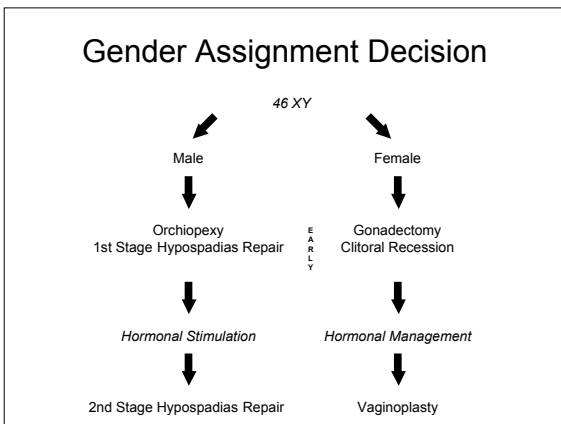
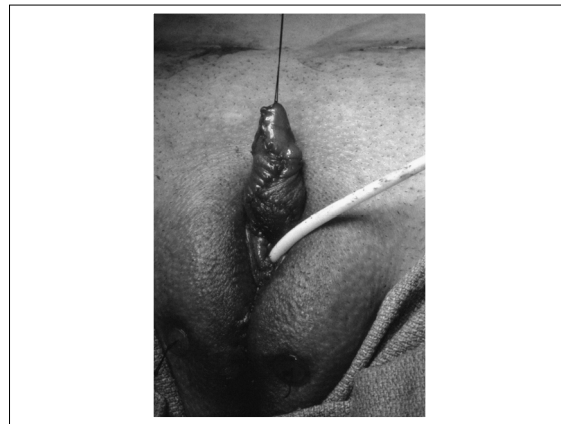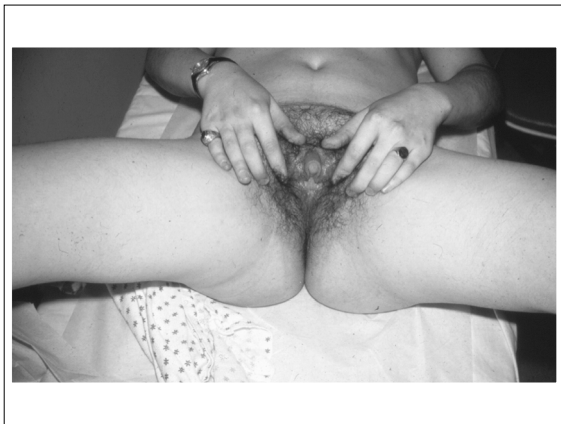
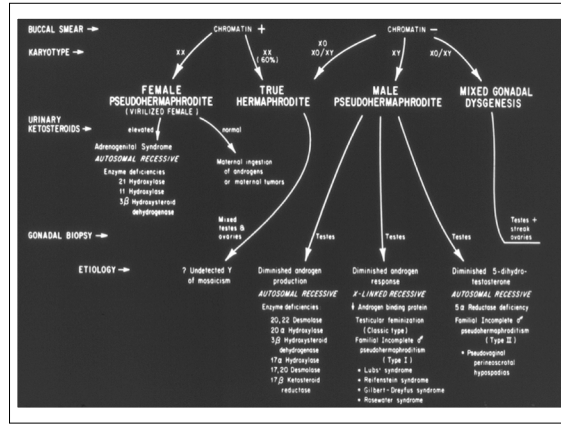
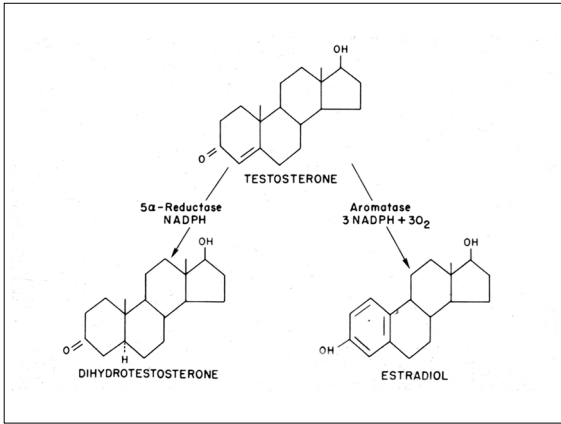




- ### Male Pseudohermaphrodite
- XY Individual
    - Poorly Virilized
    - Diminished Androgen Production
    - Diminished Androgen Response (Spectrum)
    - Diminished DHT







**Gender Assignment Decision**

**Conclusions:**

1. Maintain gonadal sex whenever possible
2. Gonads inappropriate for gender assignment should come out early.
3. Clitoral Recession, Orchiopexy and Hypospadias Repair are best done early.
4. Vaginoplasty can be delayed.
5. Long-term follow-up and management are essential.

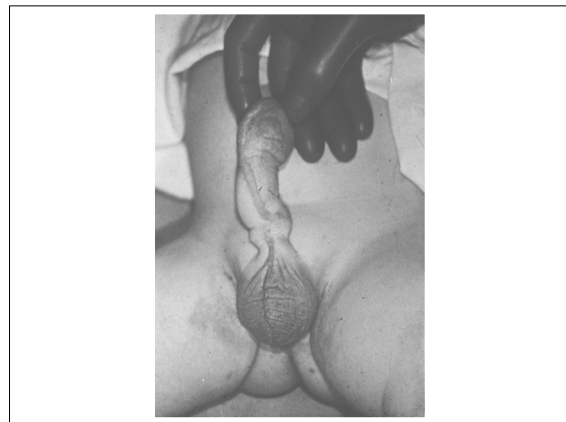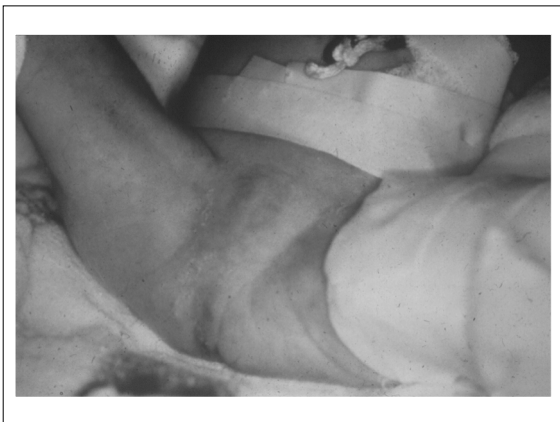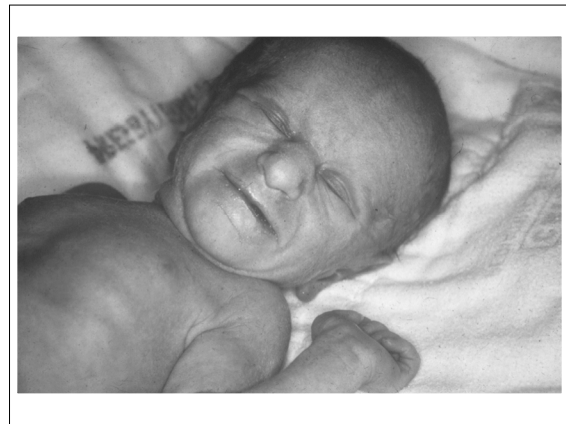

## Treatment

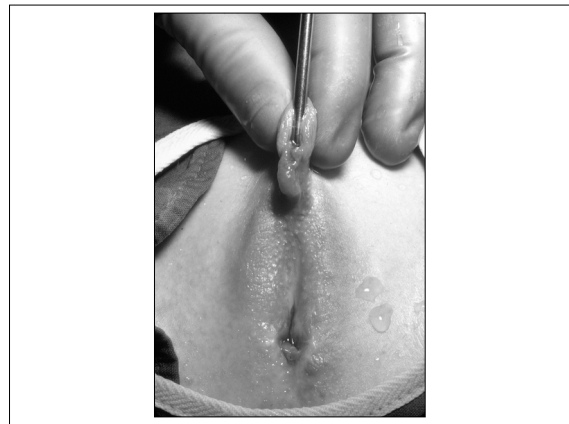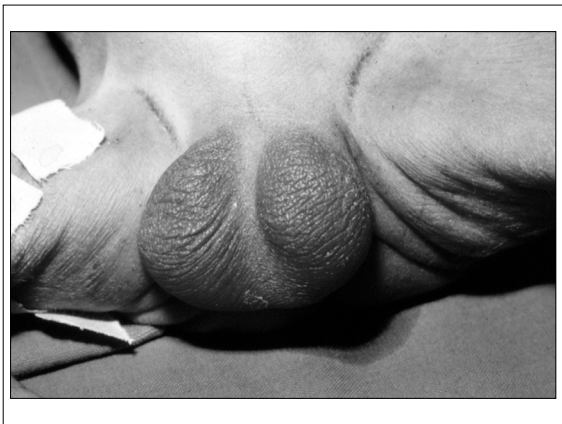
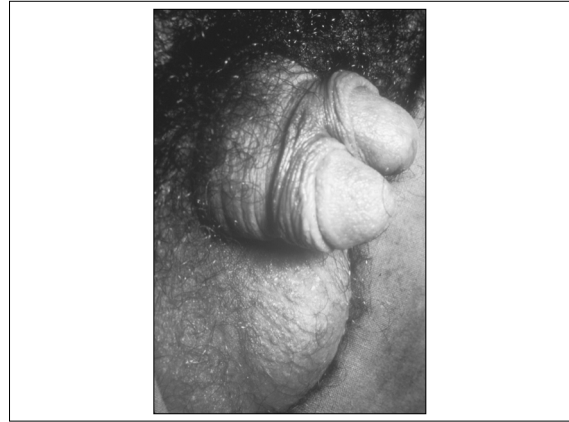
### Early

- Gender Assignment - By Committee
- Steroid Replacement

### Later (if necessary)

- Gonadectomy
- Clitoral Recession
- Vaginoplasty
- Psychotherapy





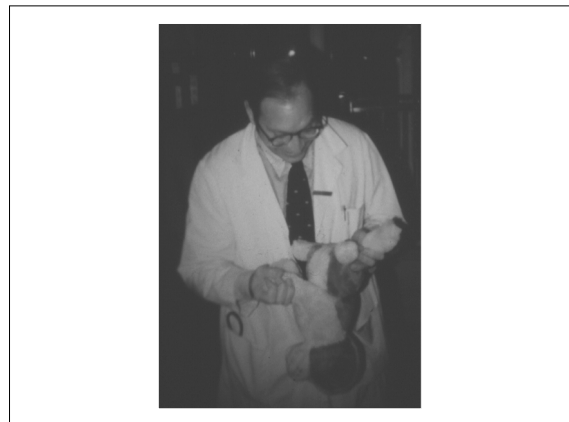**Workup**

**History**

- Maternal Androgen
- Family History

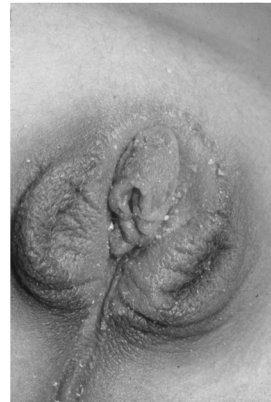**Physical Exam**

- How Many Openings
- Size of the Phallus
- Palpable Gonads
- Presence of a Uterus



Stretched penile length in normal males. Values are expressed in cm.

S.D.	Mean ± S.D.	Mean - 2.5
Newborn, 30 weeks	2.5 ± 0.4	1.5
Newborn, 34 weeks	3.0 ± 0.4	2.0
Newborn, term	3.5 ± 0.4	2.4
0-5 months	3.9 ± 0.8	1.9
6-12 months	4.3 ± 0.8	2.3
1-2 years	4.7 ± 0.8	2.6
2-3 years	5.1 ± 0.9	2.9
3-4 years	5.5 ± 0.9	3.3
4-5 years	5.7 ± 0.9	3.5
5-6 years	6.0 ± 0.9	3.8
6-7 years	6.1 ± 0.9	3.9
7-8 years	6.2 ± 1.0	3.7
8-9 years	6.3 ± 1.0	3.8
9-10 years	6.3 ± 1.0	3.8
10-11 years	6.4 ± 1.1	3.7
Adult	13.3 ± 1.6	9.3



### Workup - Later

- Urethrogram
- Karyotype
- Biochemical Markers
- SRY Gene
- Laparoscopy +/- Gonadal BX

### Surgical Goals

- Sexually Functional
- Cosmetically Acceptable

### Conclusions

- Gender Assignment Is a Medical Emergency
- A Gender Assignment Committee Should Be Utilized
- The Gonadal Sex Should Be Maintained If Possible
- If Gonadal Sex Is Not Maintained, Early Gonadectomy Is Important

