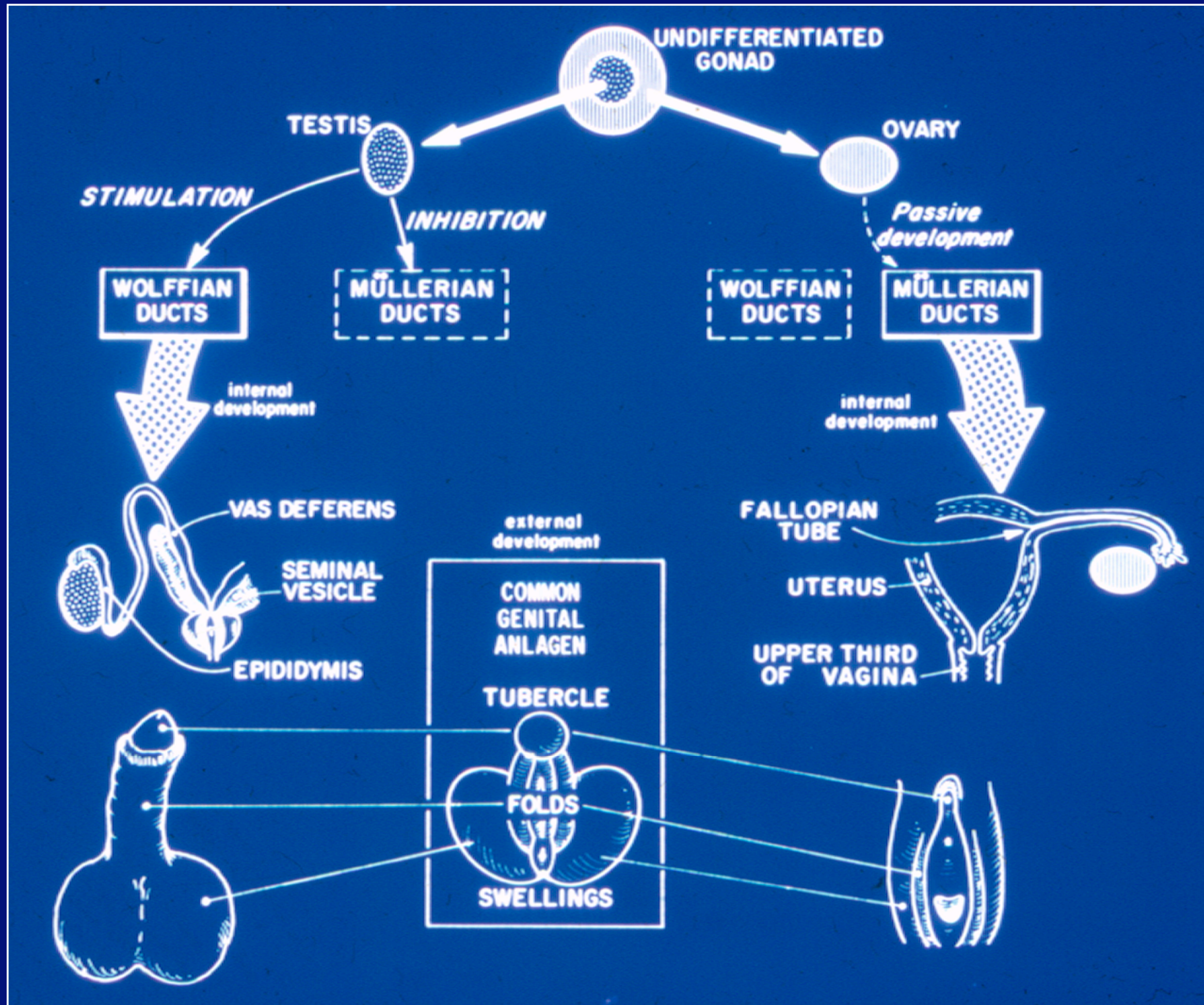
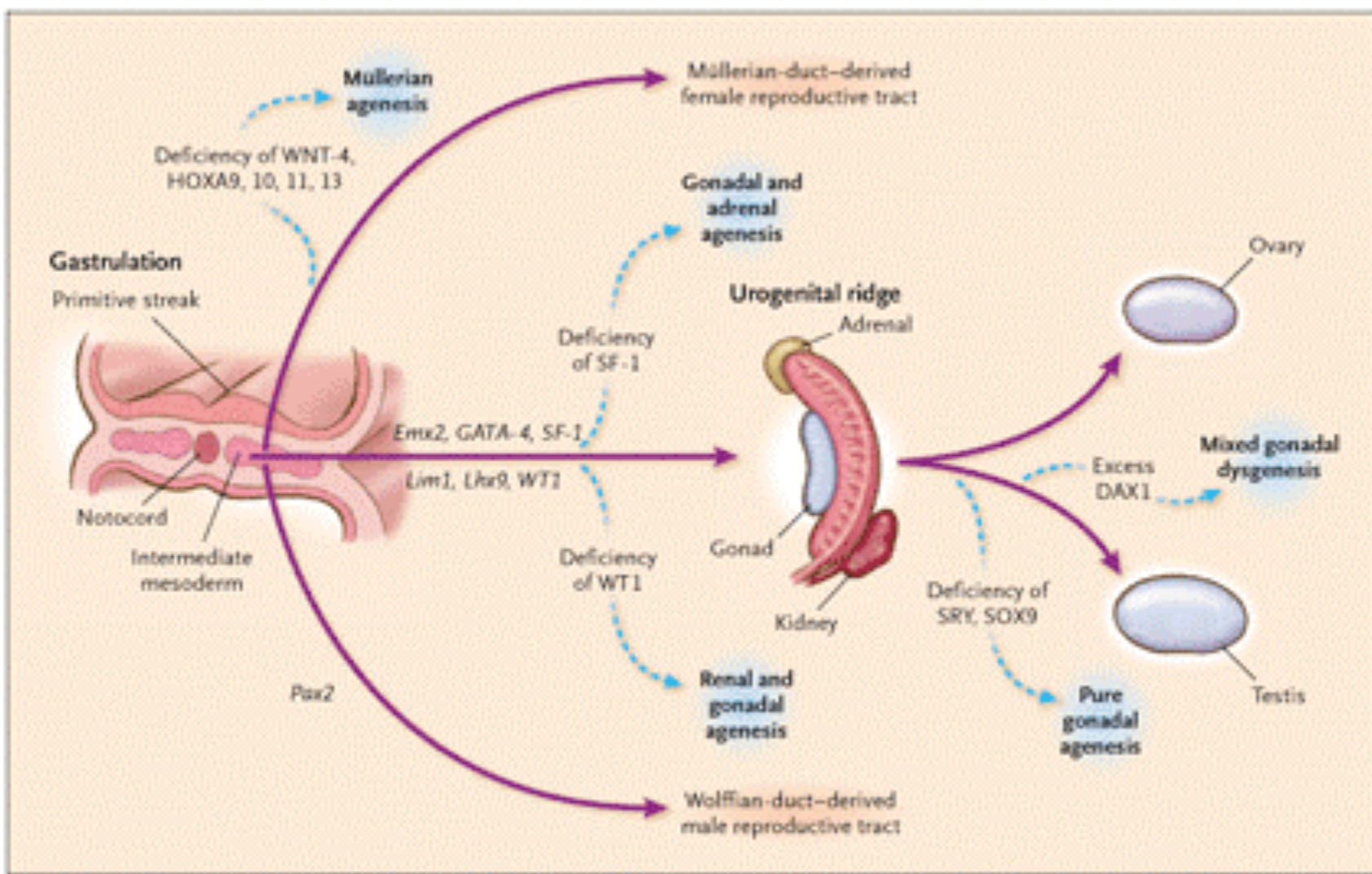
AMBIGUOUS GENITALIA- THE SCIENCE AND THE MYSTERY

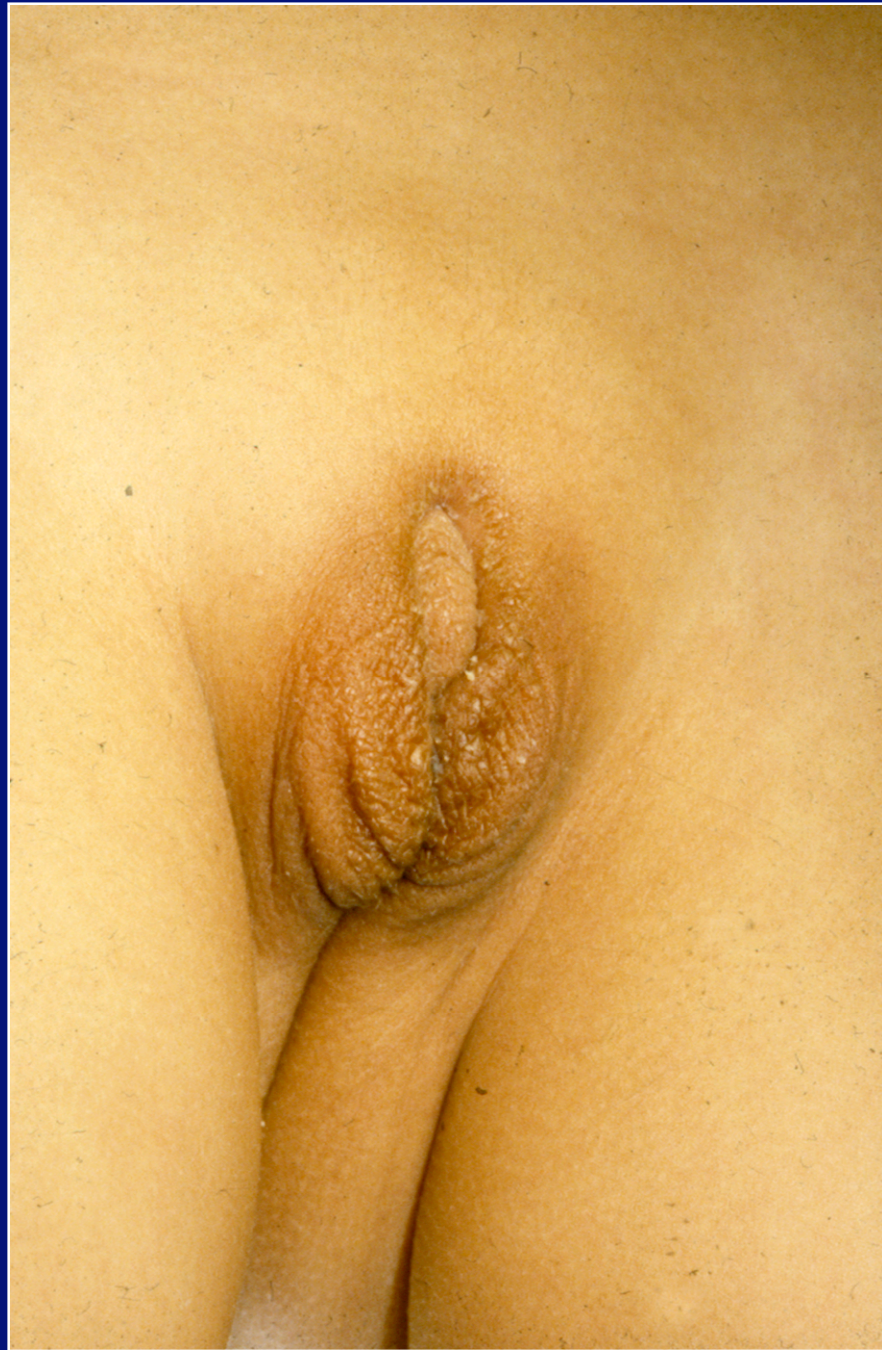Terry W. Hensle M.D.

Given Foundation Professor of Urology

Vice Chairman Department of Urology

Columbia University College of P&S

Sex



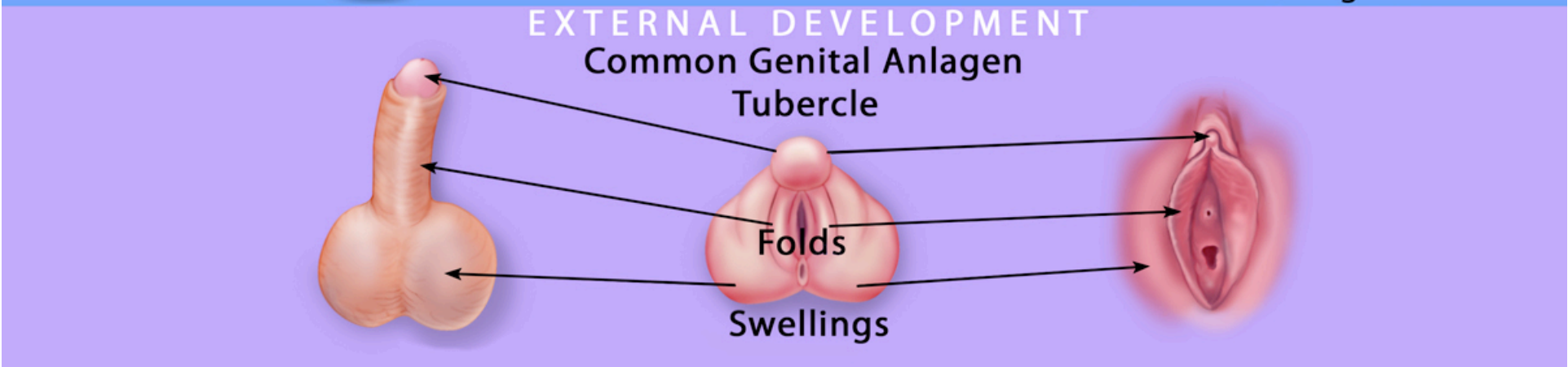
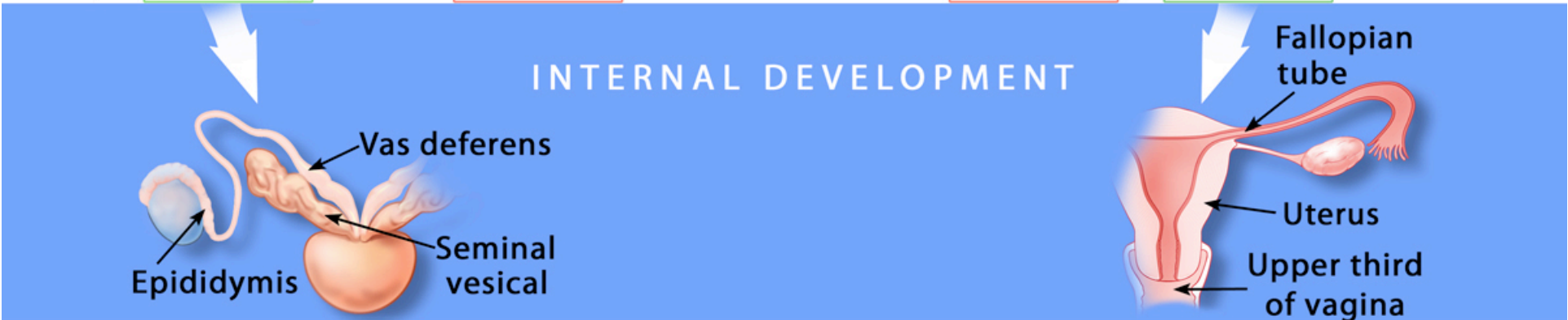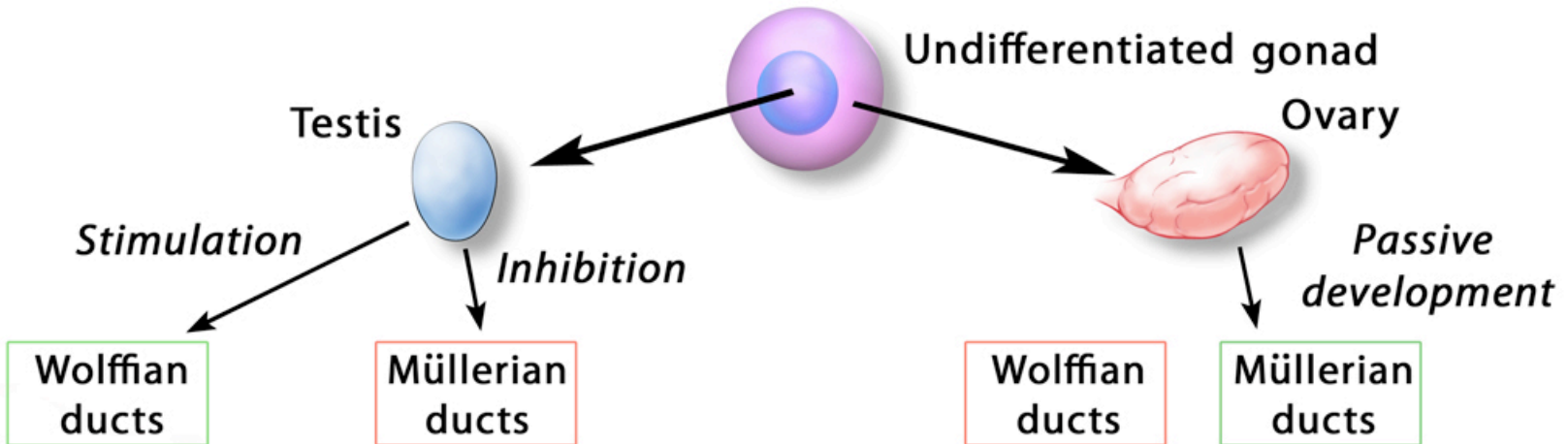
Genetic Sex



Gonadal Sex

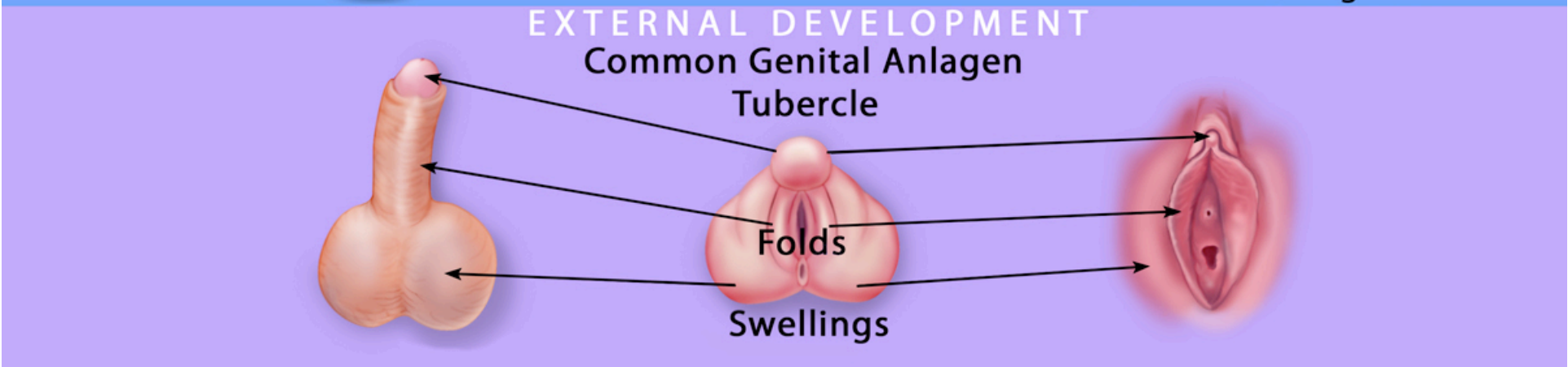
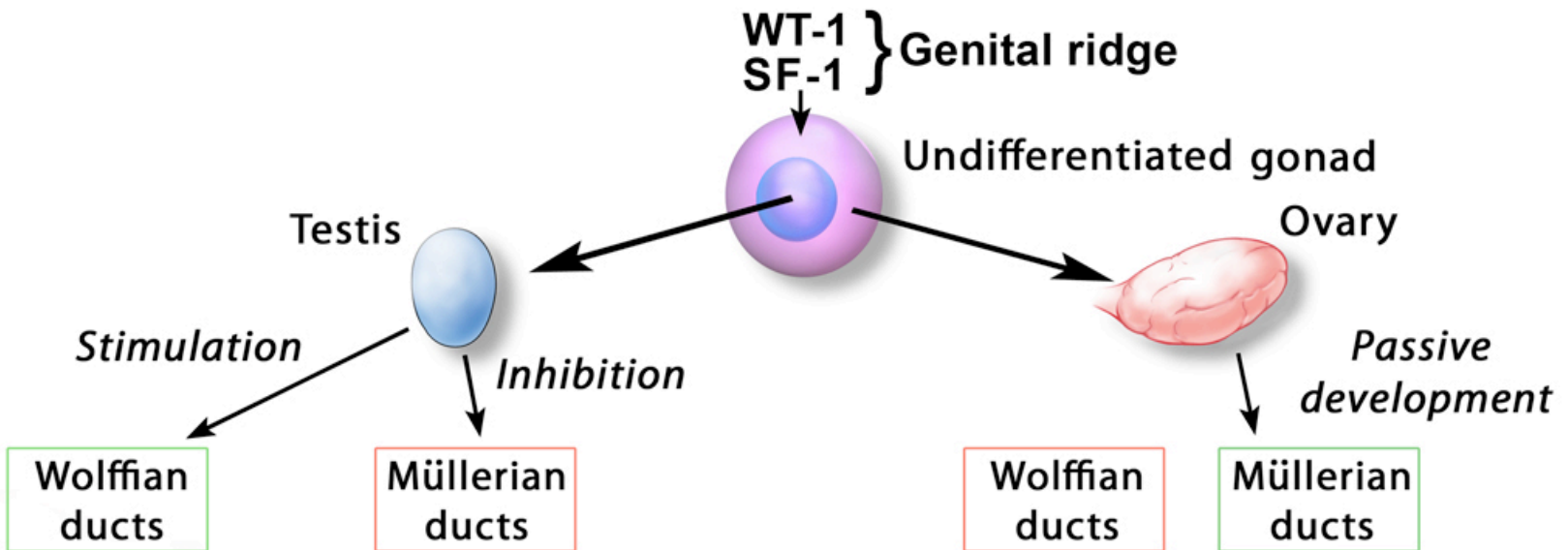


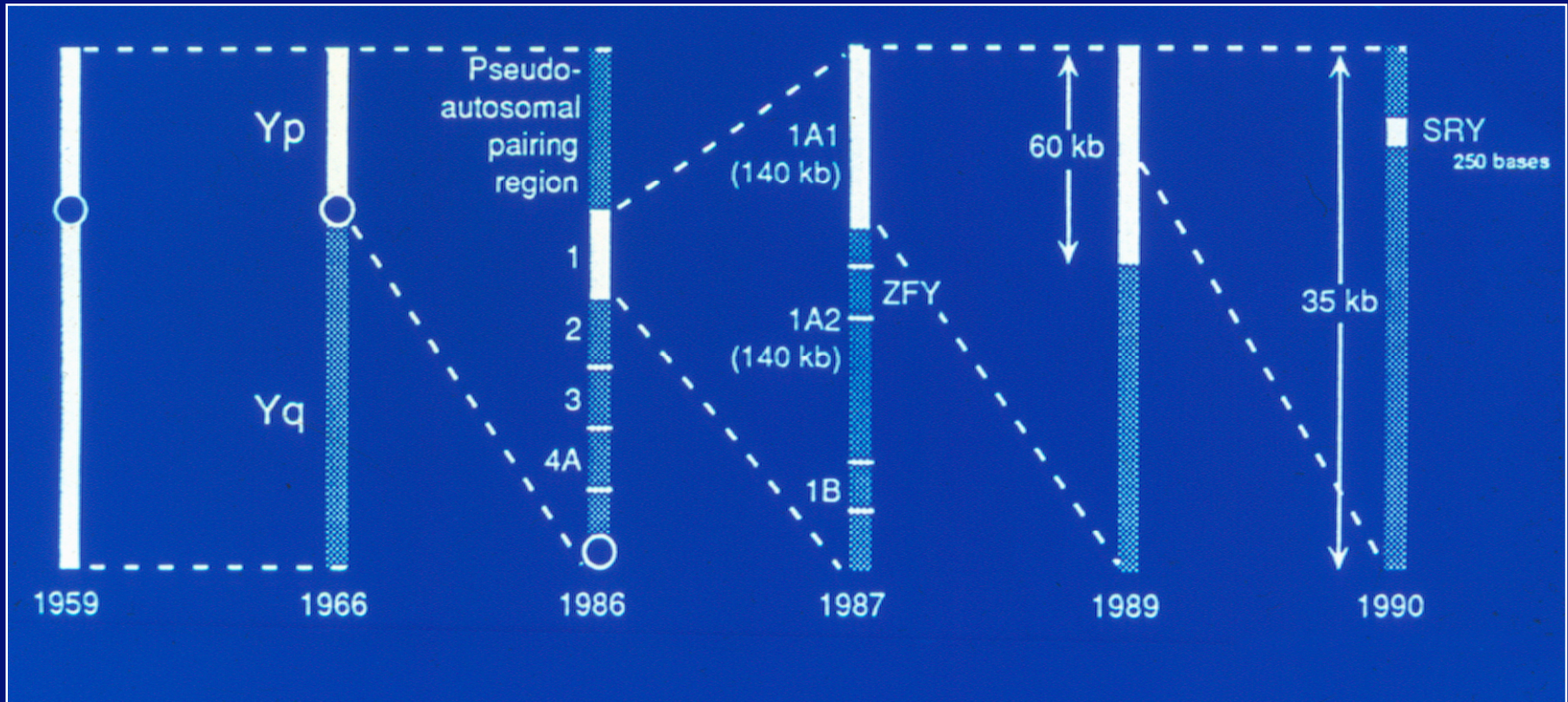
Phenotypic Sex

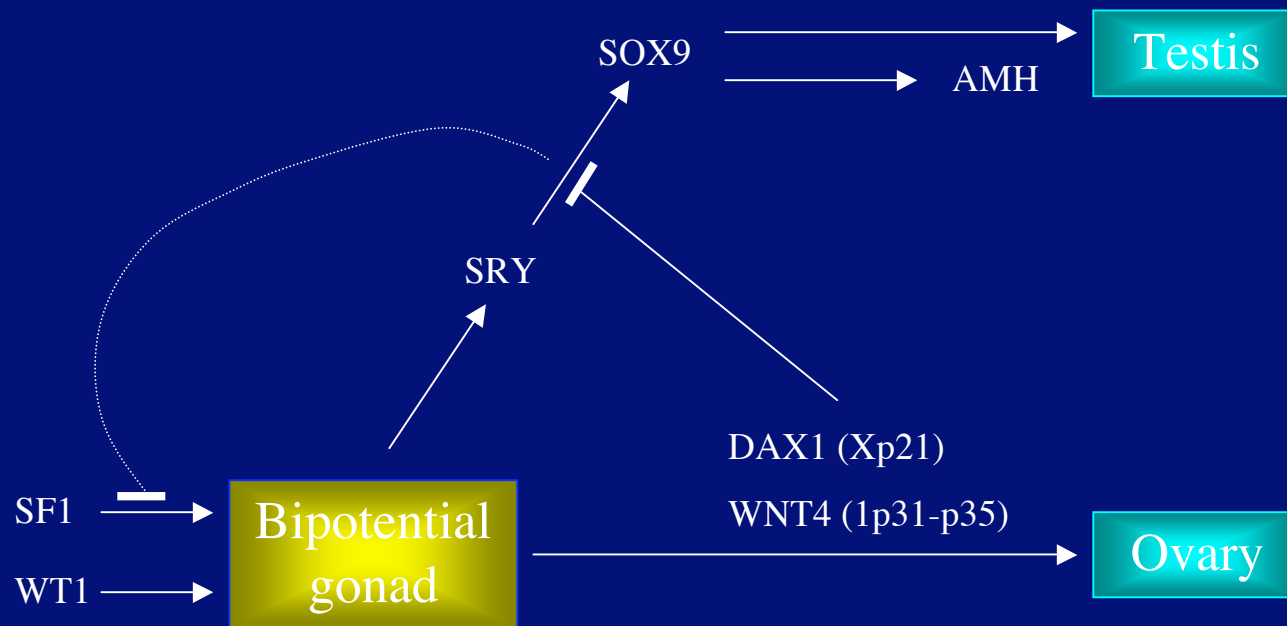


BUT HOW DOES THE UNDIFFERENTIATED GONAD DEVELOP ?

- **WT-1** – is the best characterized transcriptional regulatory factor known to be necessary for development of the bipotential gonad
- **WT-1** – is expressed on 11p13 , and is variably expressed at different time points of embryogenesis, in both kidney and gonad.
- ***It is the Master Switch***







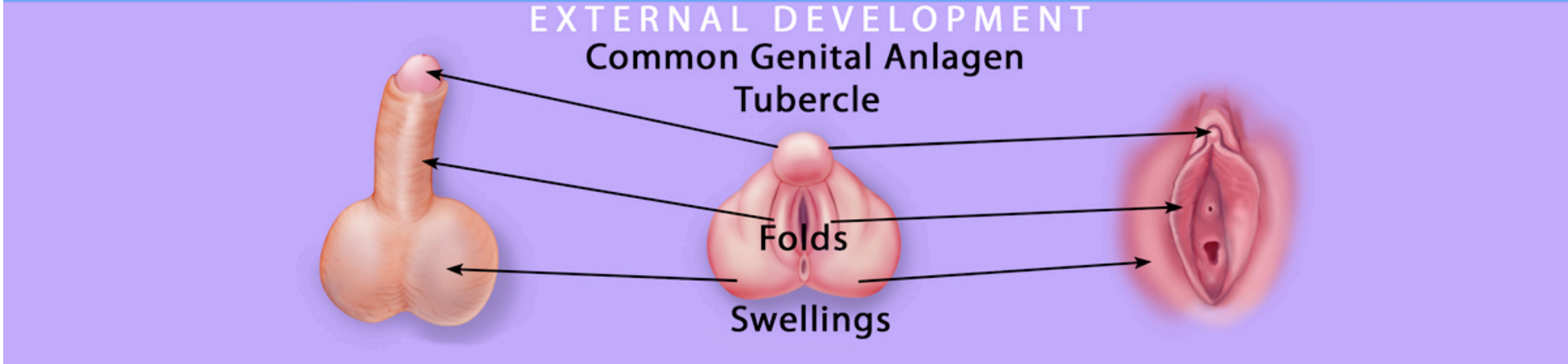
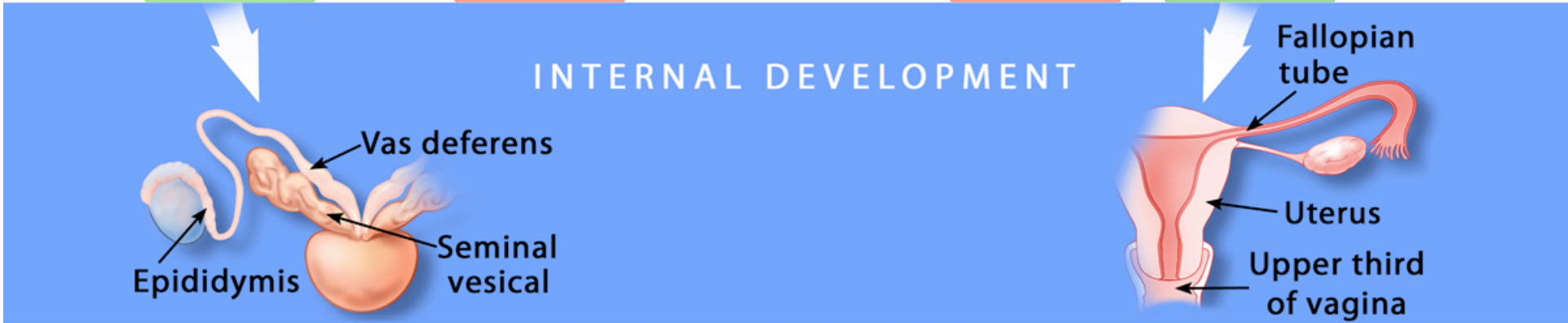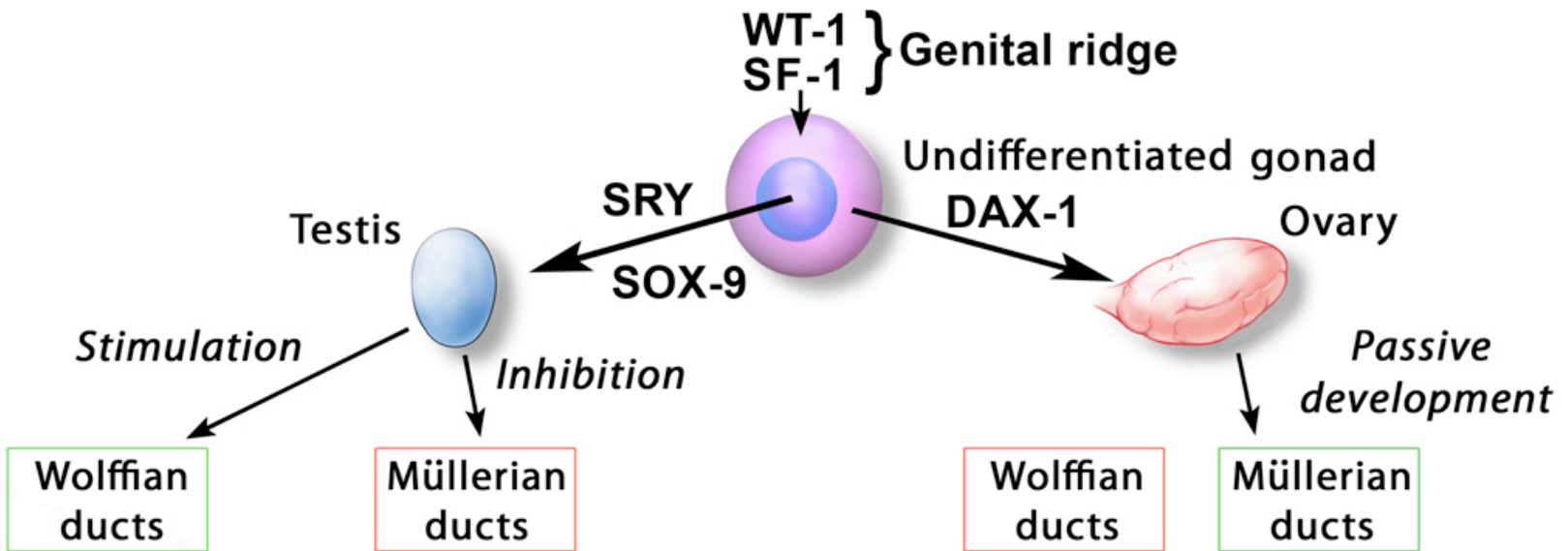
Genetic Sex

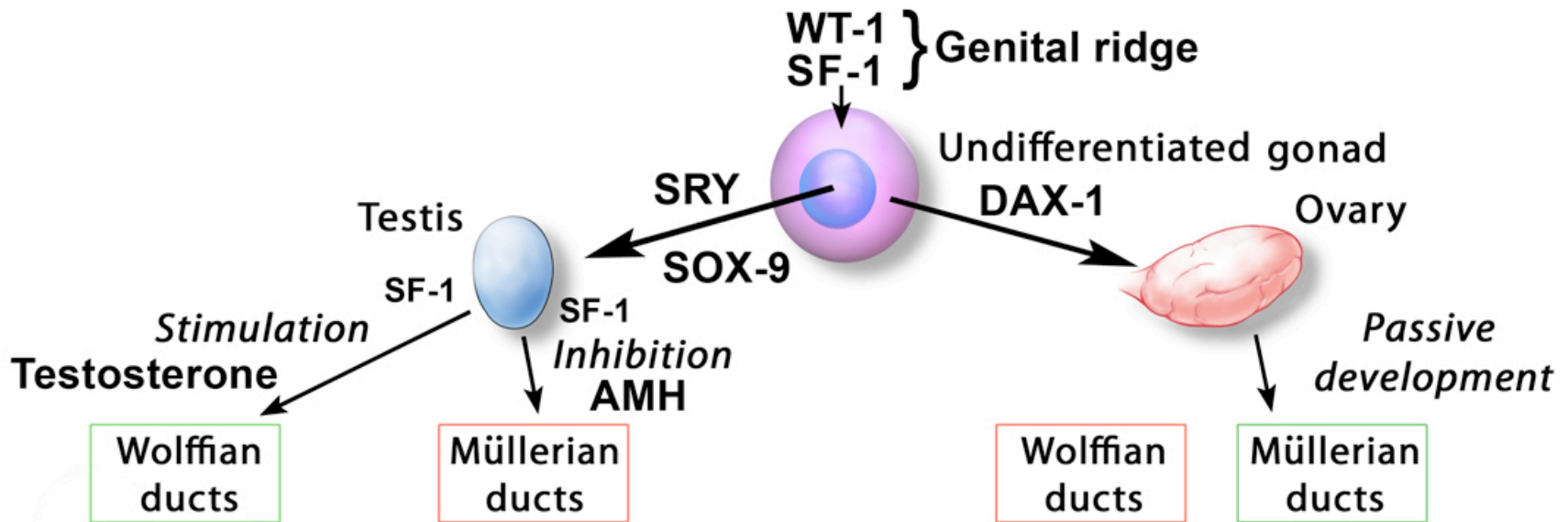


Gonadal Sex

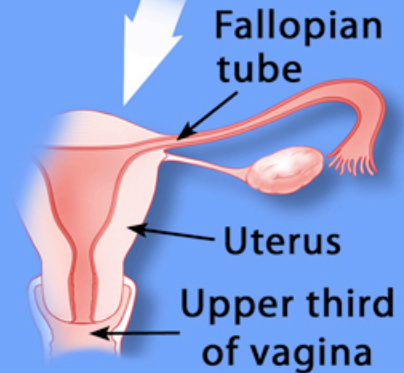
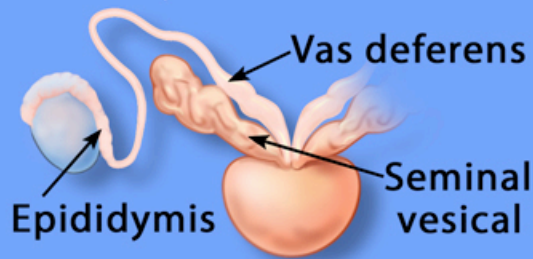


Phenotypic Sex



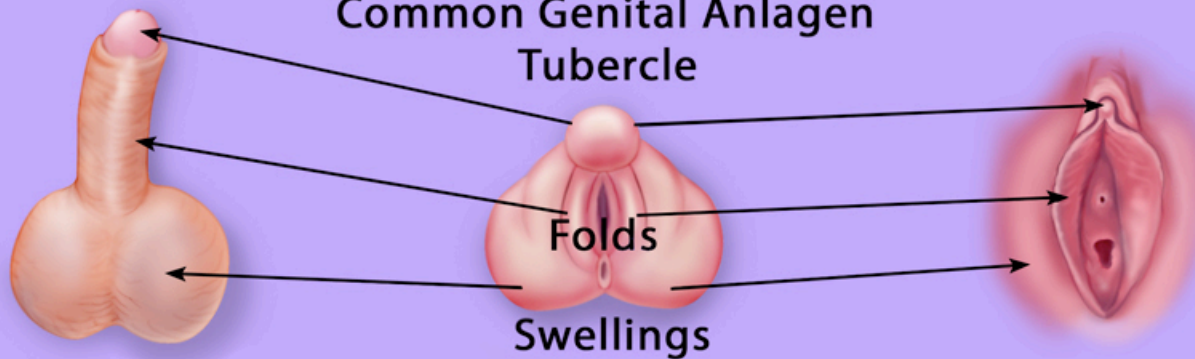


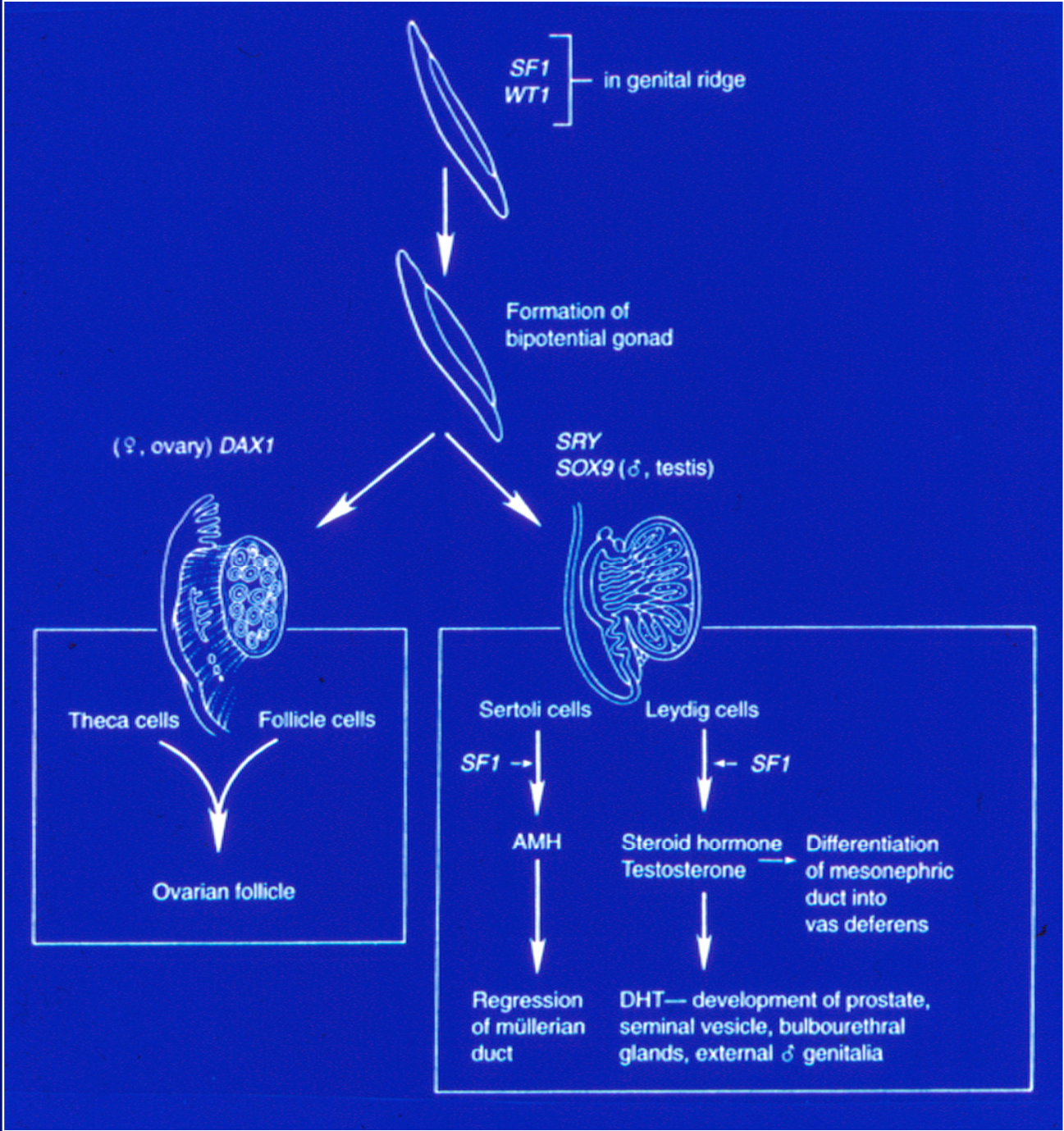
INTERNAL DEVELOPMENT



EXTERNAL DEVELOPMENT

Common Genital Anlagen
 Tubercle





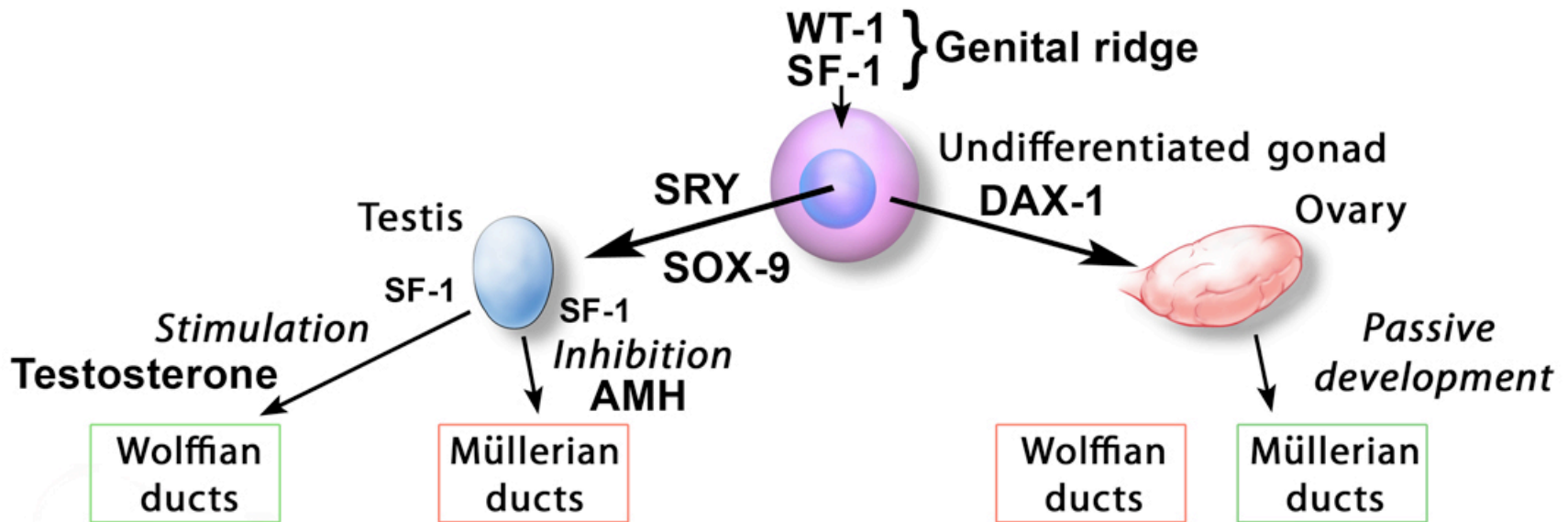
Genetic Sex



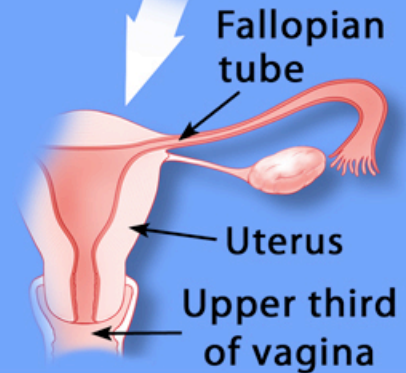
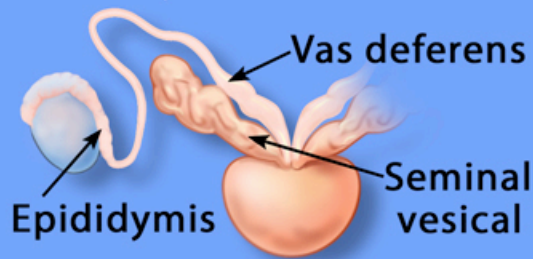
Gonadal Sex



Phenotypic Sex

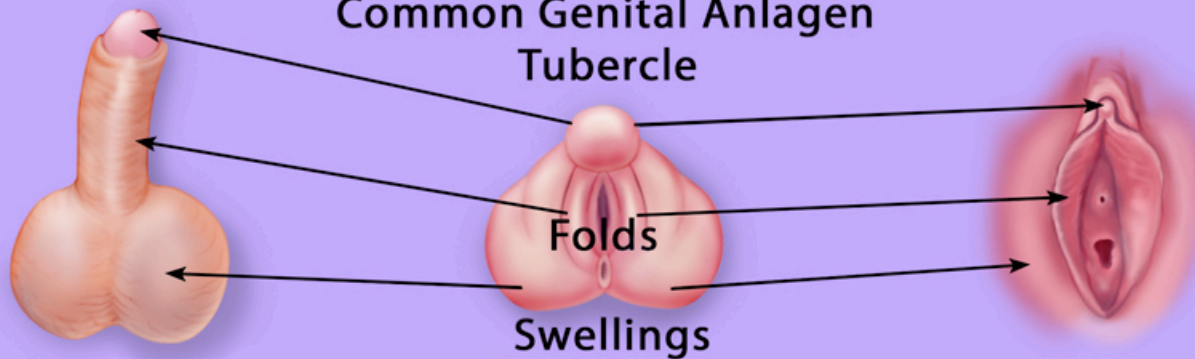


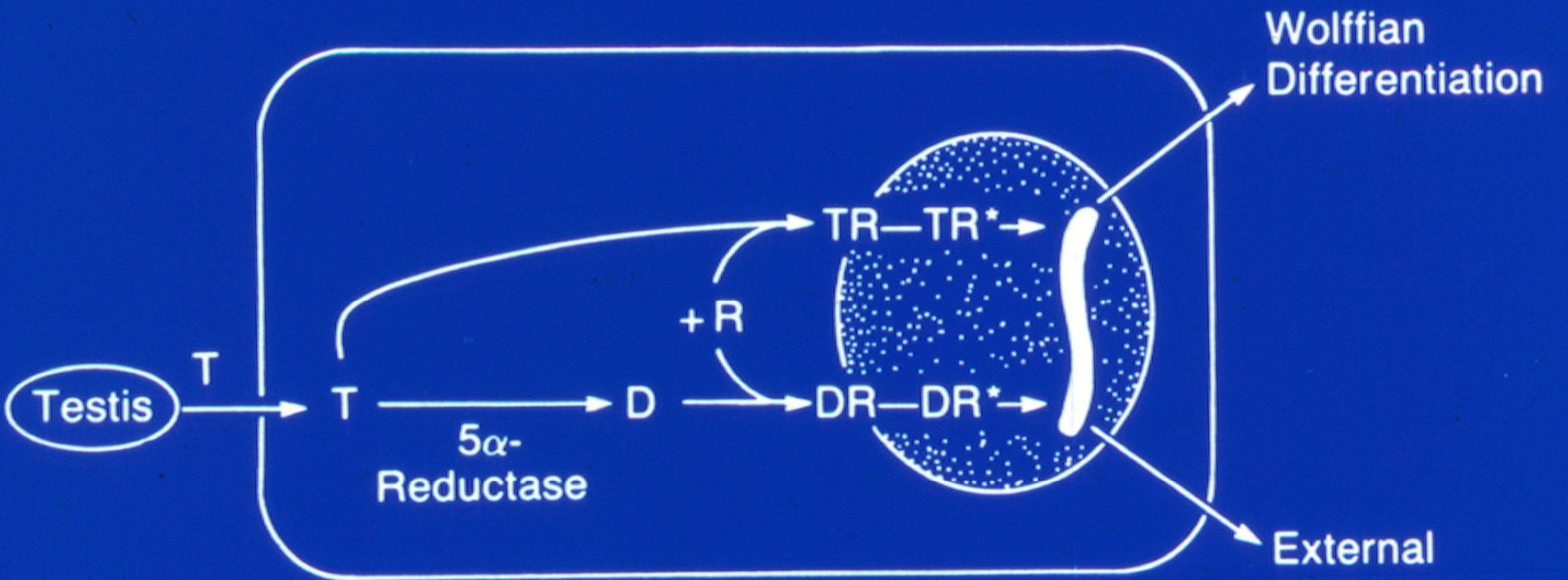
INTERNAL DEVELOPMENT

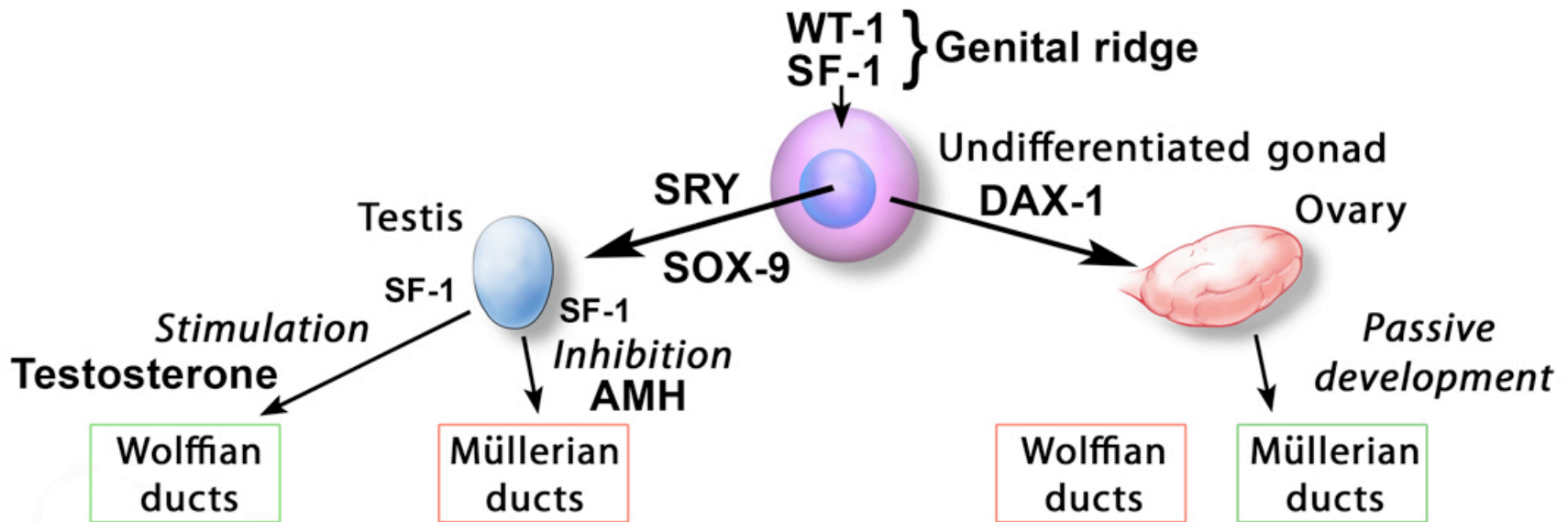


EXTERNAL DEVELOPMENT

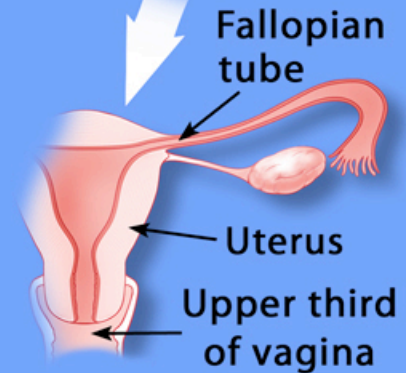
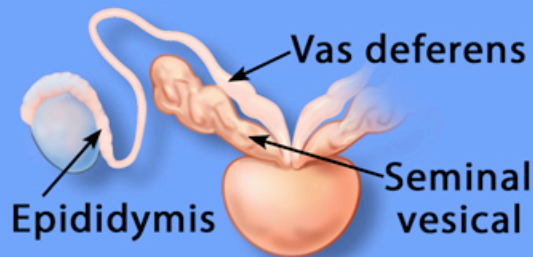
Common Genital Anlagen
 Tubercle





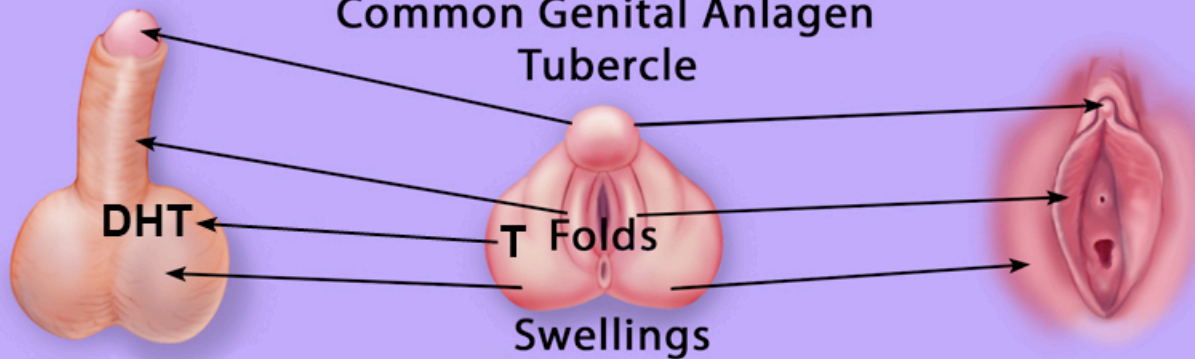


INTERNAL DEVELOPMENT



EXTERNAL DEVELOPMENT

Common Genital Anlagen
 Tubercle



Genetic Control of Male Phenotype

- Y Chromosome
 - ◆ Testicular Differentiation
- X Chromosome
 - ◆ End Organ Receptor
- Autosome
 - ◆ Enzymatic Control of Testosterone Biosynthesis
 - ◆ Conversion of T to DHT
 - ◆ Control of MIS Action

Intersex Questions

- What gene is integral in development of the bipotential gonad from the urogenital ridge?
- What gene is responsible for differentiation of the bipotential gonad into fetal testis?
- What is the major androgen of the fetal testis?
- What is the timing of its action?
- What stimulates fetal testis to produce androgen?
- What is the receptor site in fetal testis?
- What causes differentiation of external genitalia ?
- What gene is responsible for ovarian development?

Intersex - Classification

- True Hermaphrodite
- Mixed Gonadal Dysgenesis
- Female Pseudohermaphrodite
- Male Pseudohermaphrodite

Intersex > Disorders of Sexual Development (DSD)

- True Hermaphrodite
- Mixed Gonadal Dysgenesis
- Female Pseudohermaphrodite
- Male Pseudohermaphrodite
- Ovotesticular DSD
- Dysgenetic DSD
- Ovarian DSD
- Testicular DSD

True Hermaphrodite > *Ovotesticular DSD*

- 60% Look Male
- Most Will Have at Least a Rudimentary Vagina
- Internal Duct Structures Will Correspond to the Gonad on the Ipsilateral Side

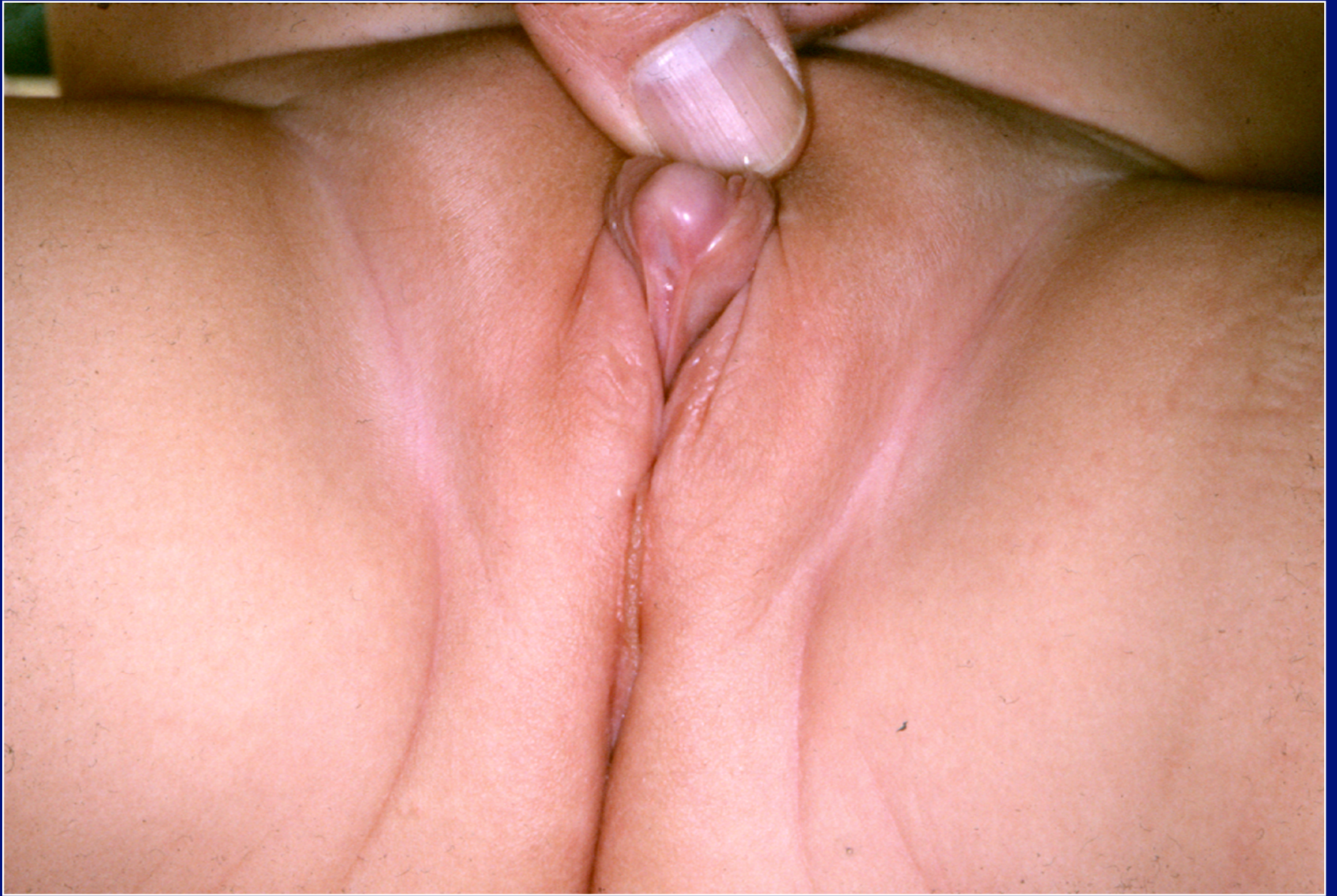PEEL
HERE

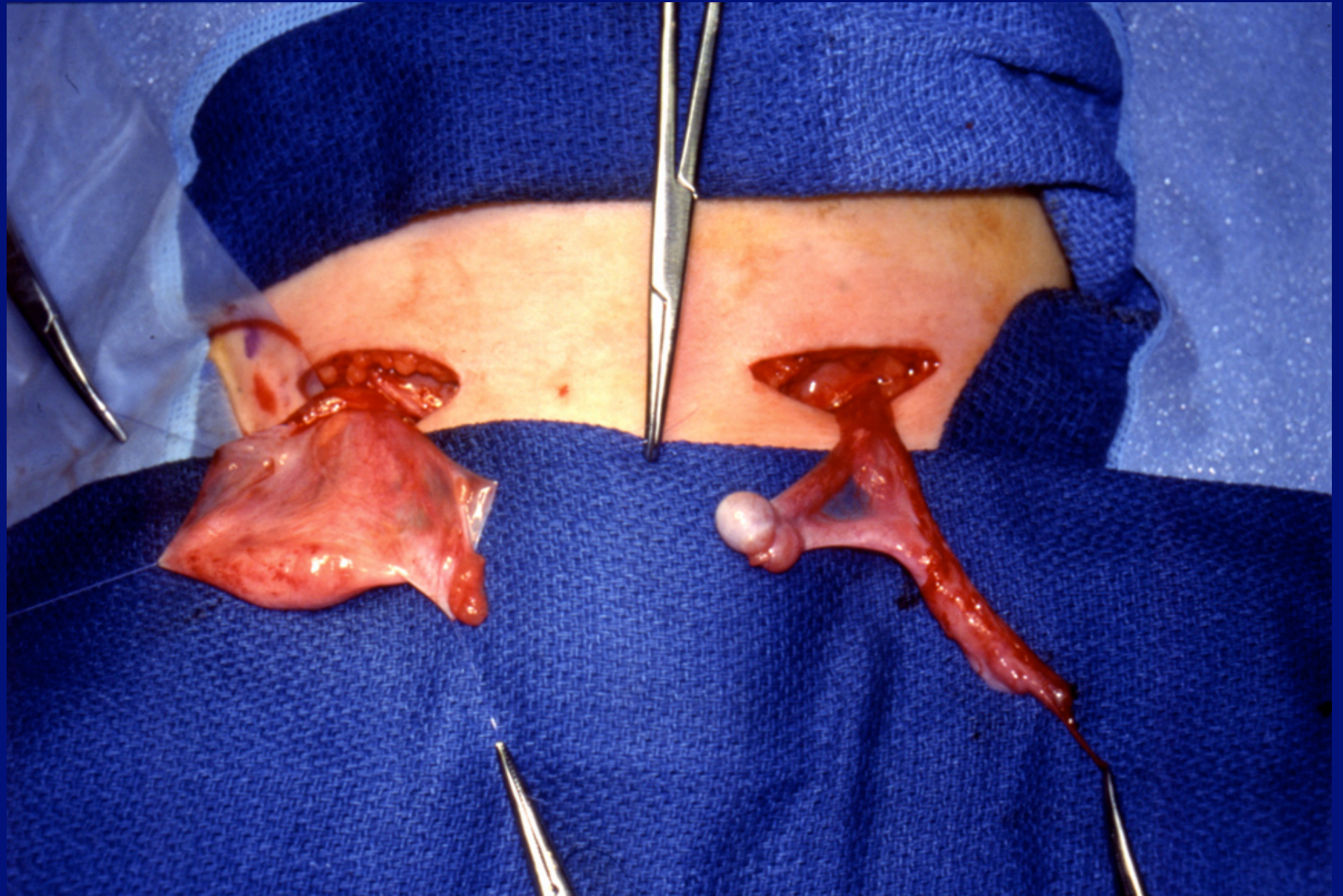
118a

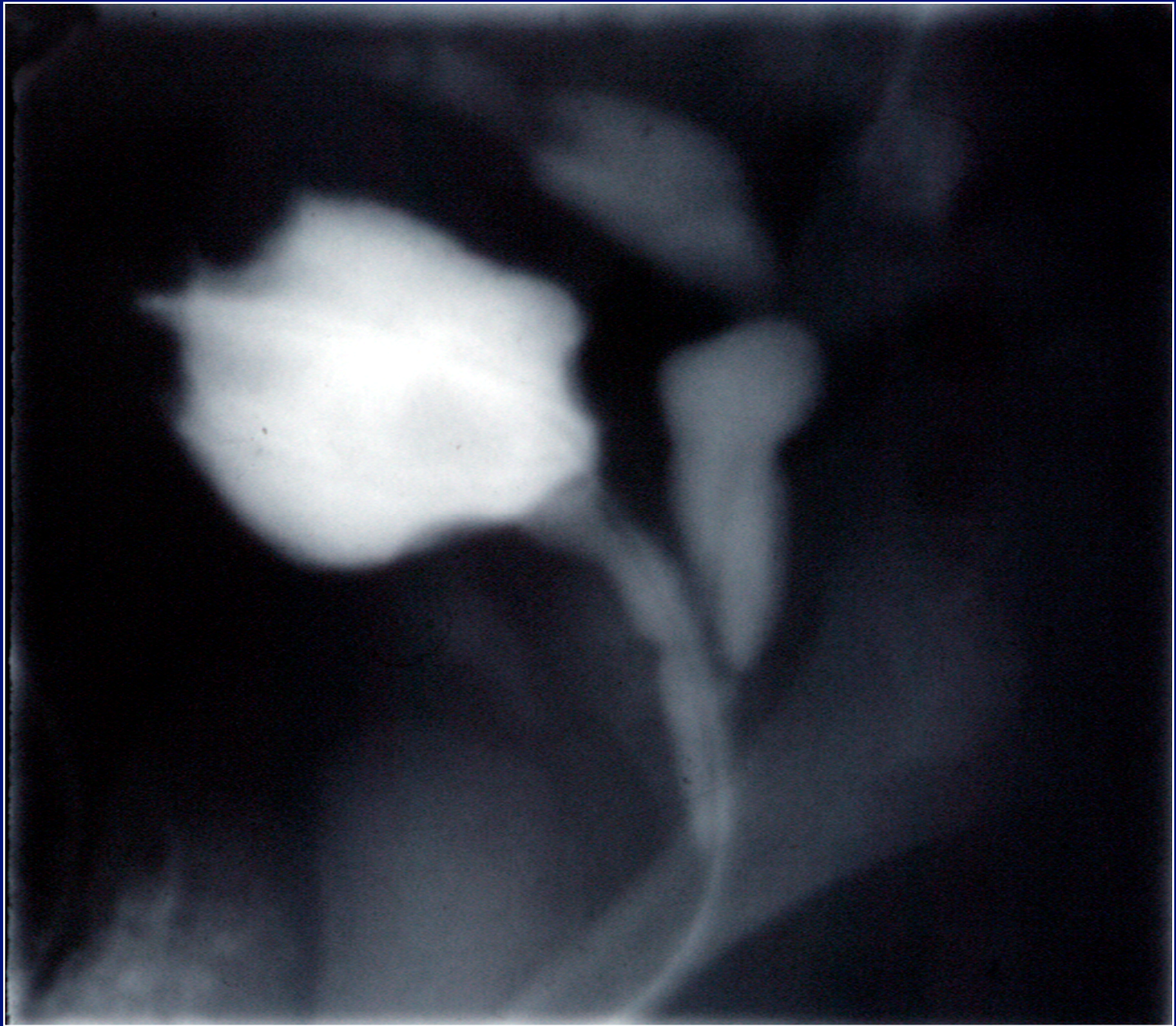GARBAGE PAIL KIDS®



HALF- NELSON

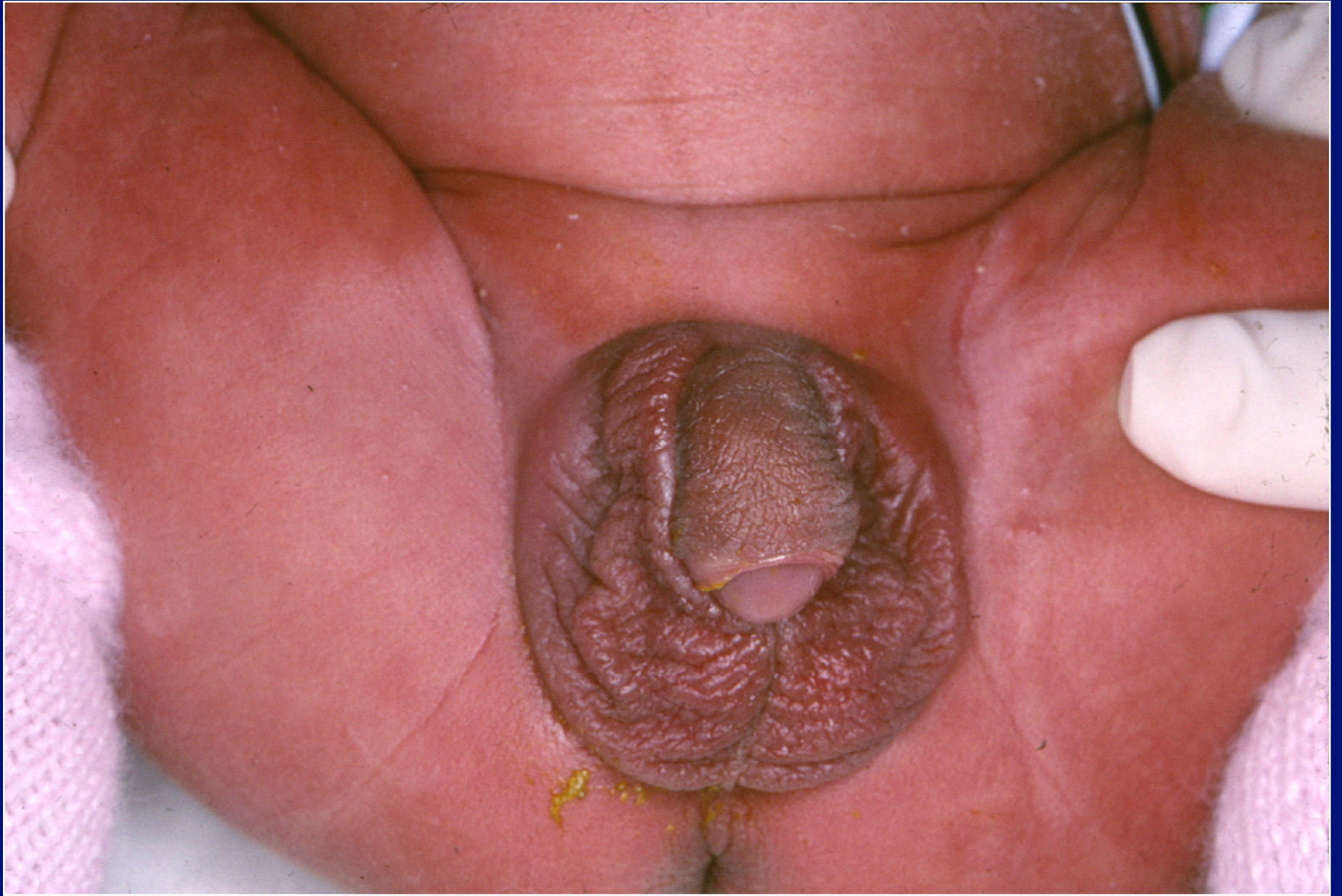


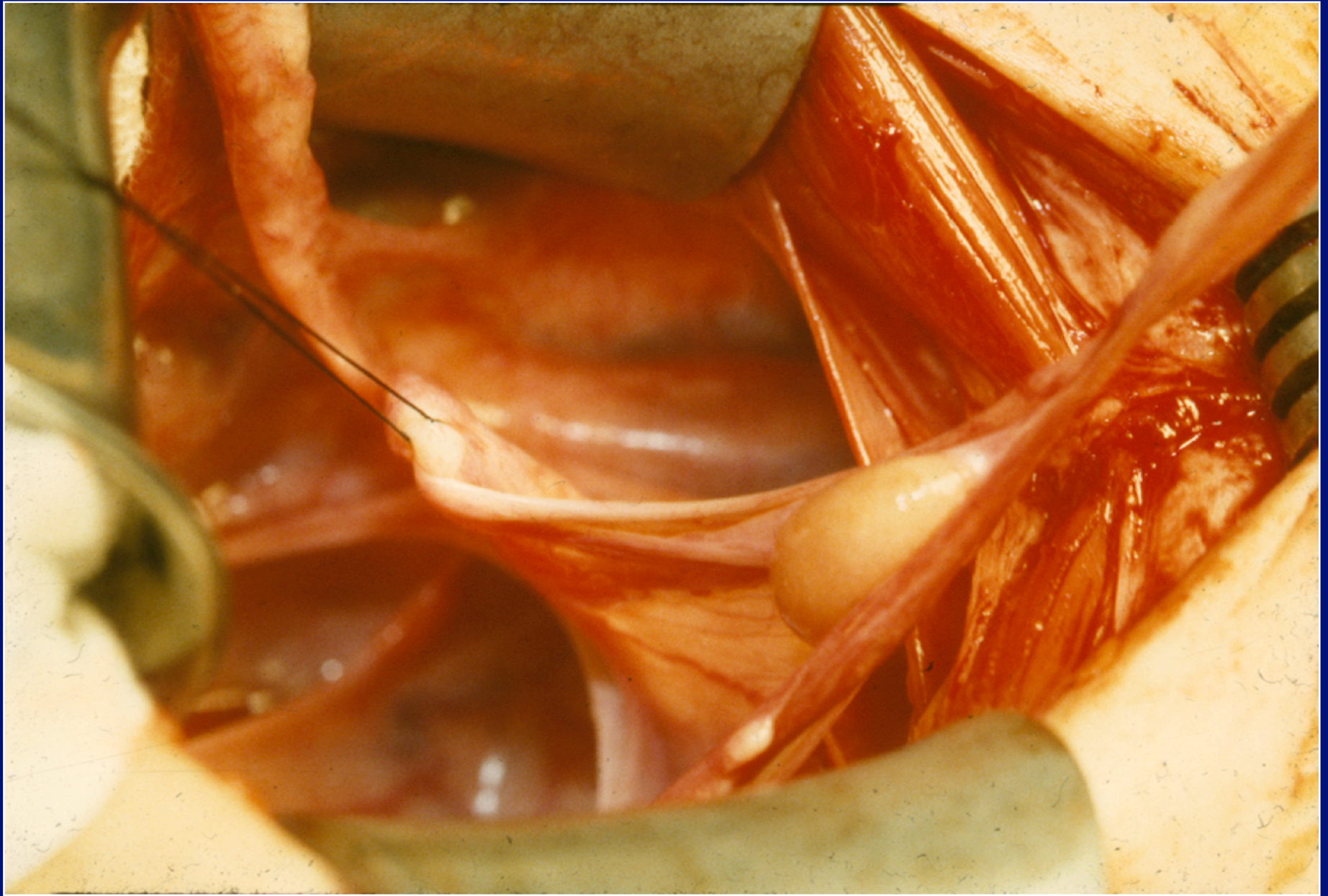


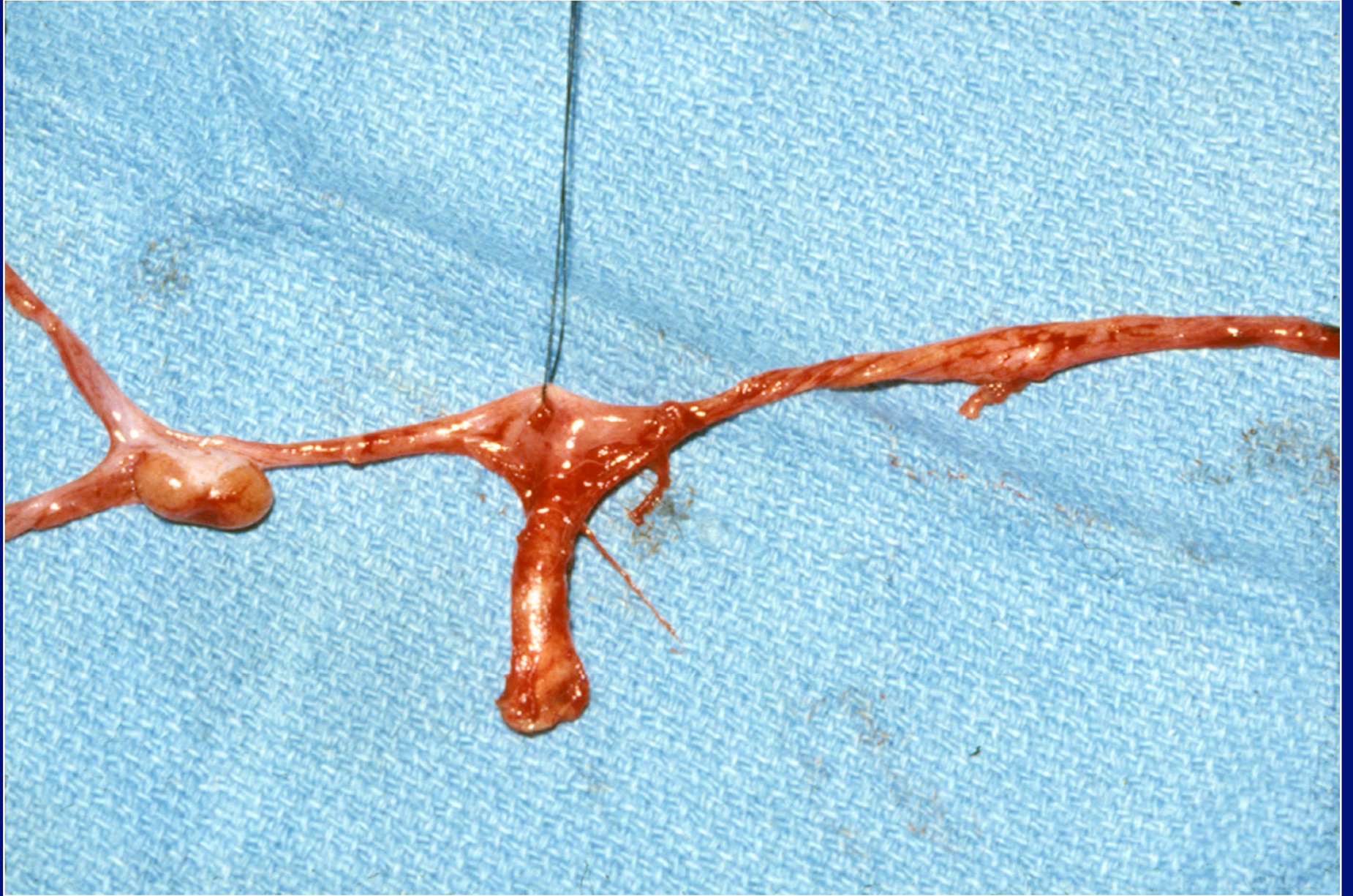Mixed Gonadal Dysgenesis > Dysgenetic DSD

- 45 XO/XY
- Streak+Testis (OVO)
- Poorly Virilized
- Sterile Male
- Short Stature
- High Incidence of Testis Tumor







Gender Assignment Decision

45-46 XO/XY

Male

Female

Orchiopexy
Orchiectomy
1st Stage Hypospadias Repair

E
A
R
L
Y

Gonadectomy
and
Clitoral Recession

Hormonal Stimulation

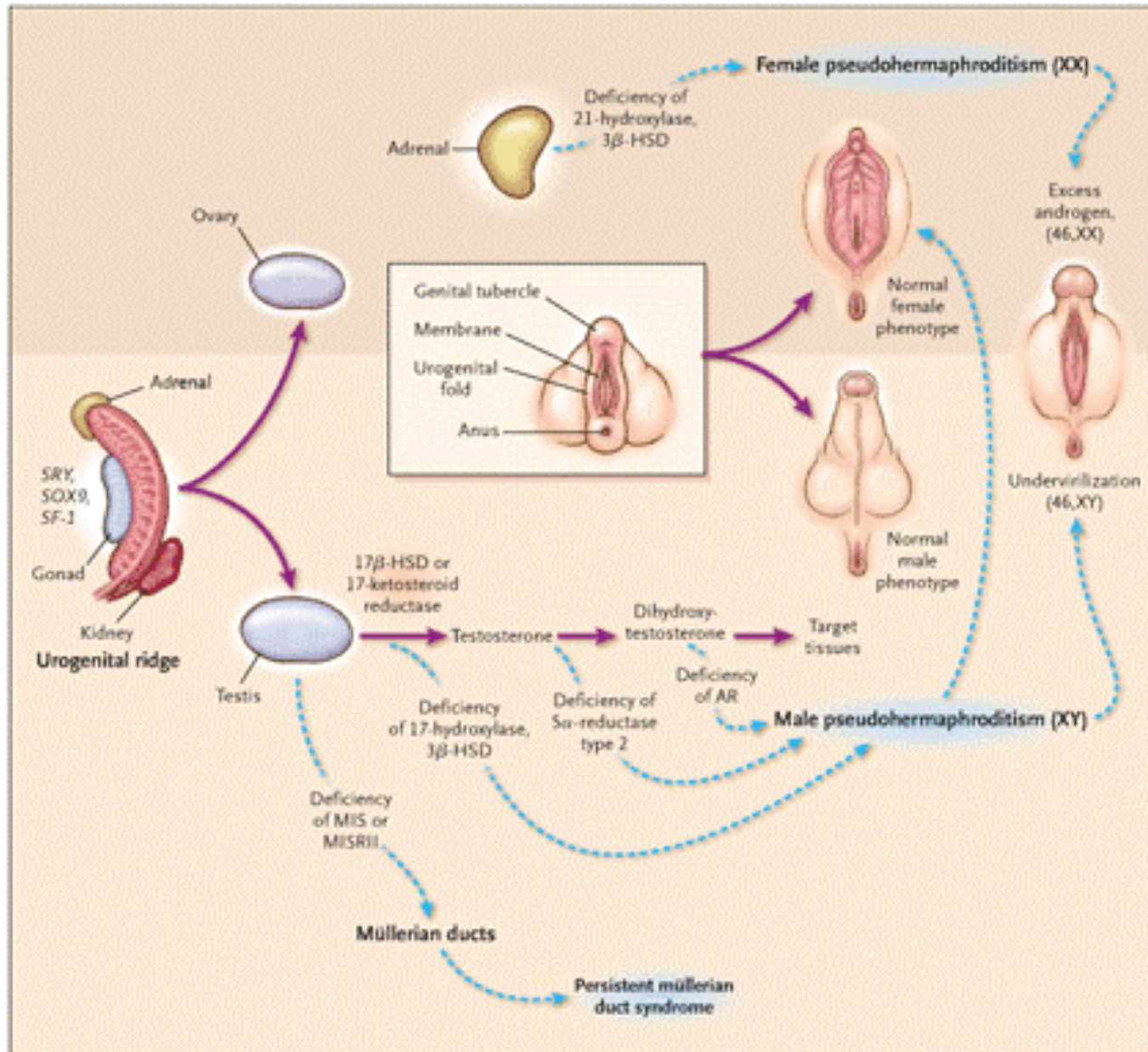
Hormonal Management

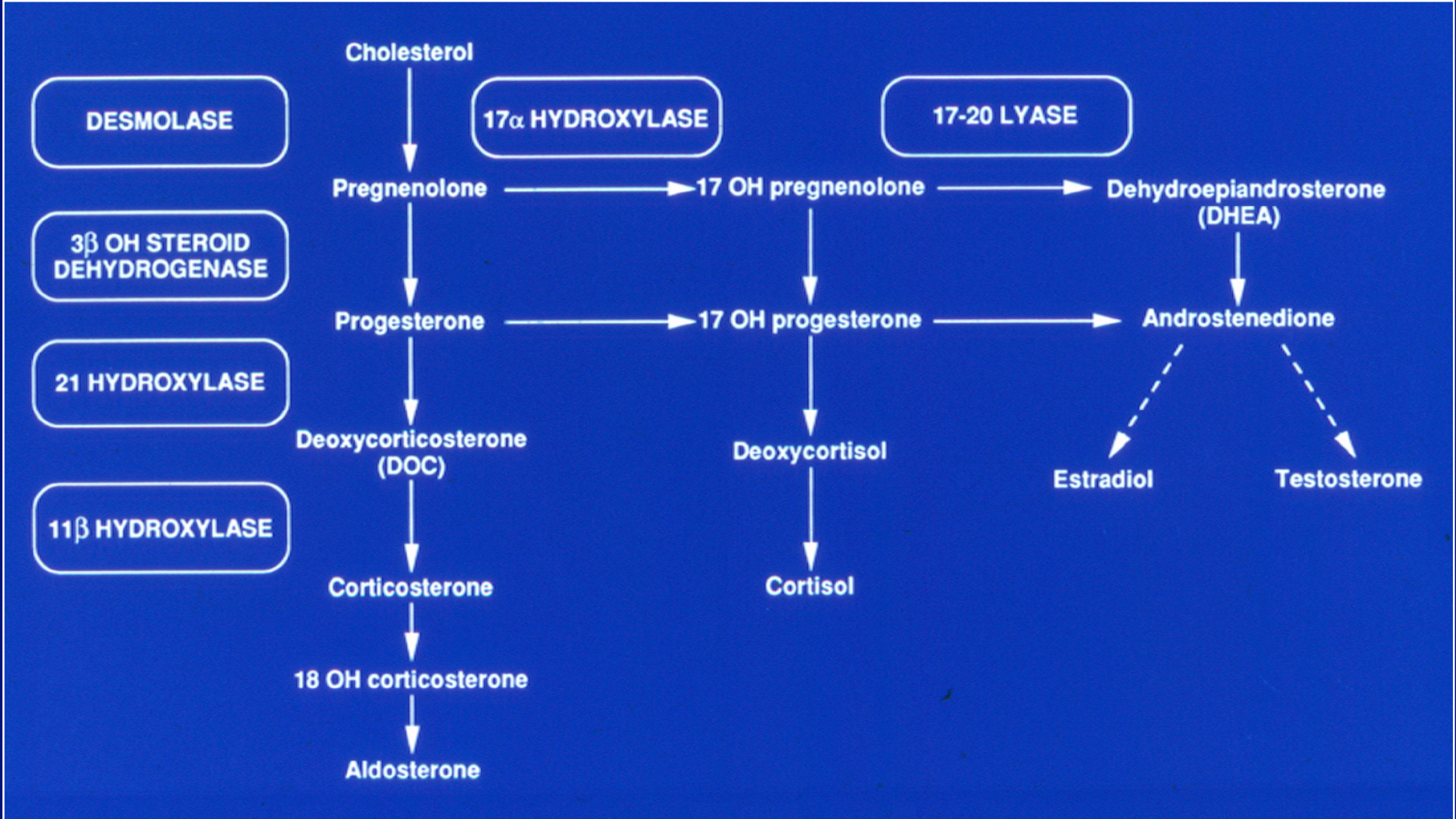
2nd Stage Hypospadias Repair

Vaginoplasty

Female Pseudohermaphrodite > Ovarian DSD

- 46 XX - Virilized
- The Most Common Cause of Ambiguous Genitalia (AGS)
- DX
 - ◆ Karyotype
 - ◆ Biochemical Markers
 - ◆ No Surgery Necessary





Normal ♀

I

II

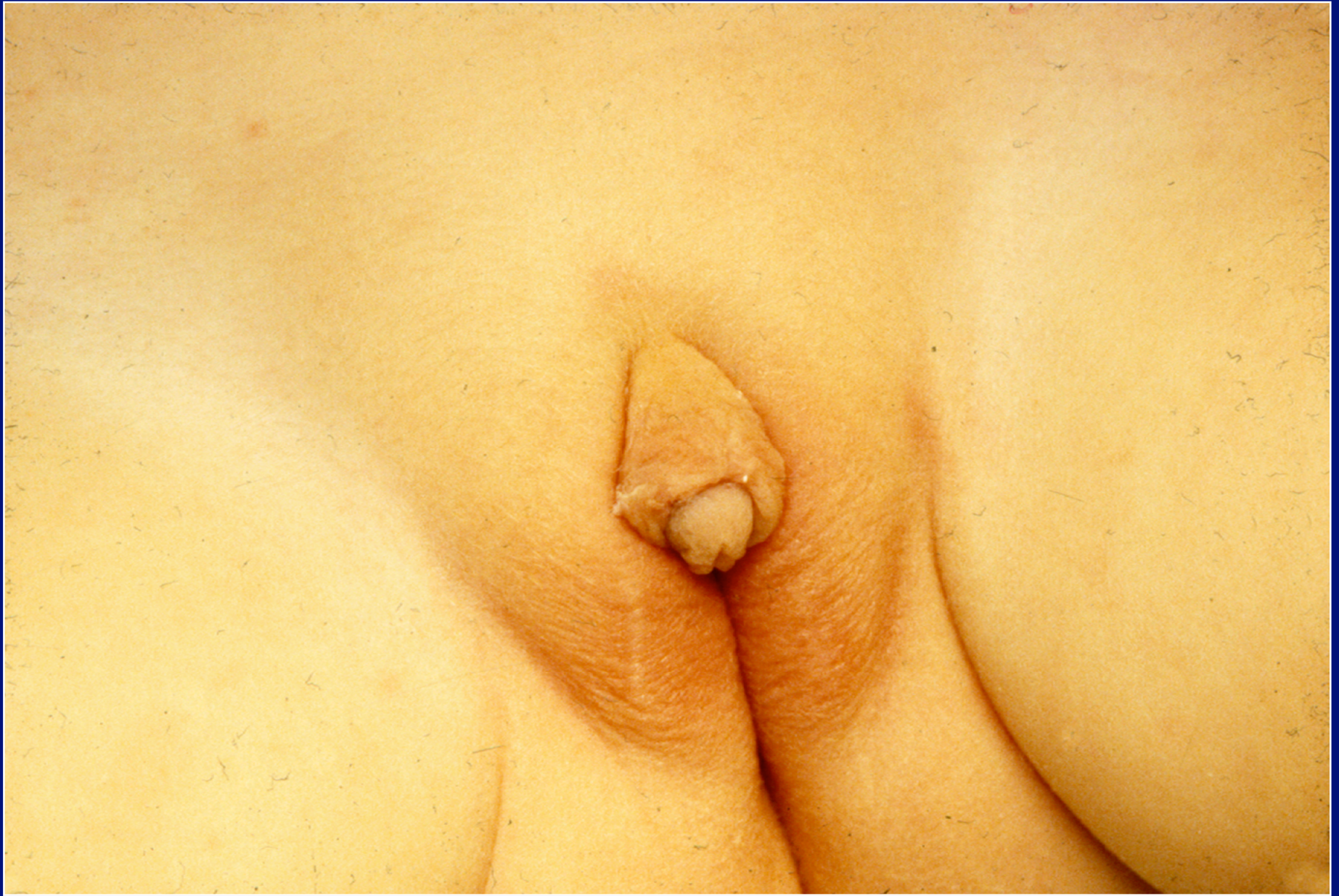III

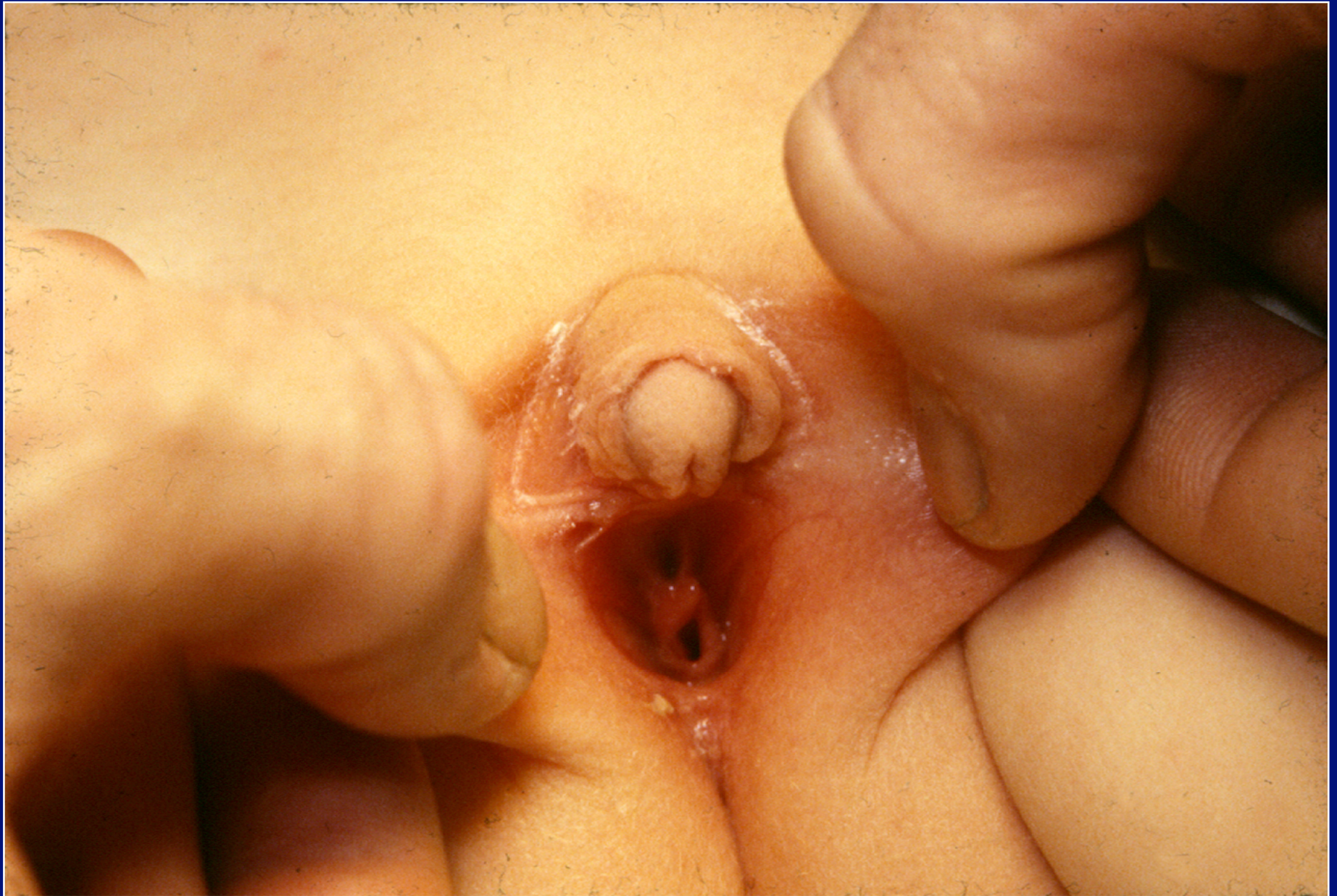IV

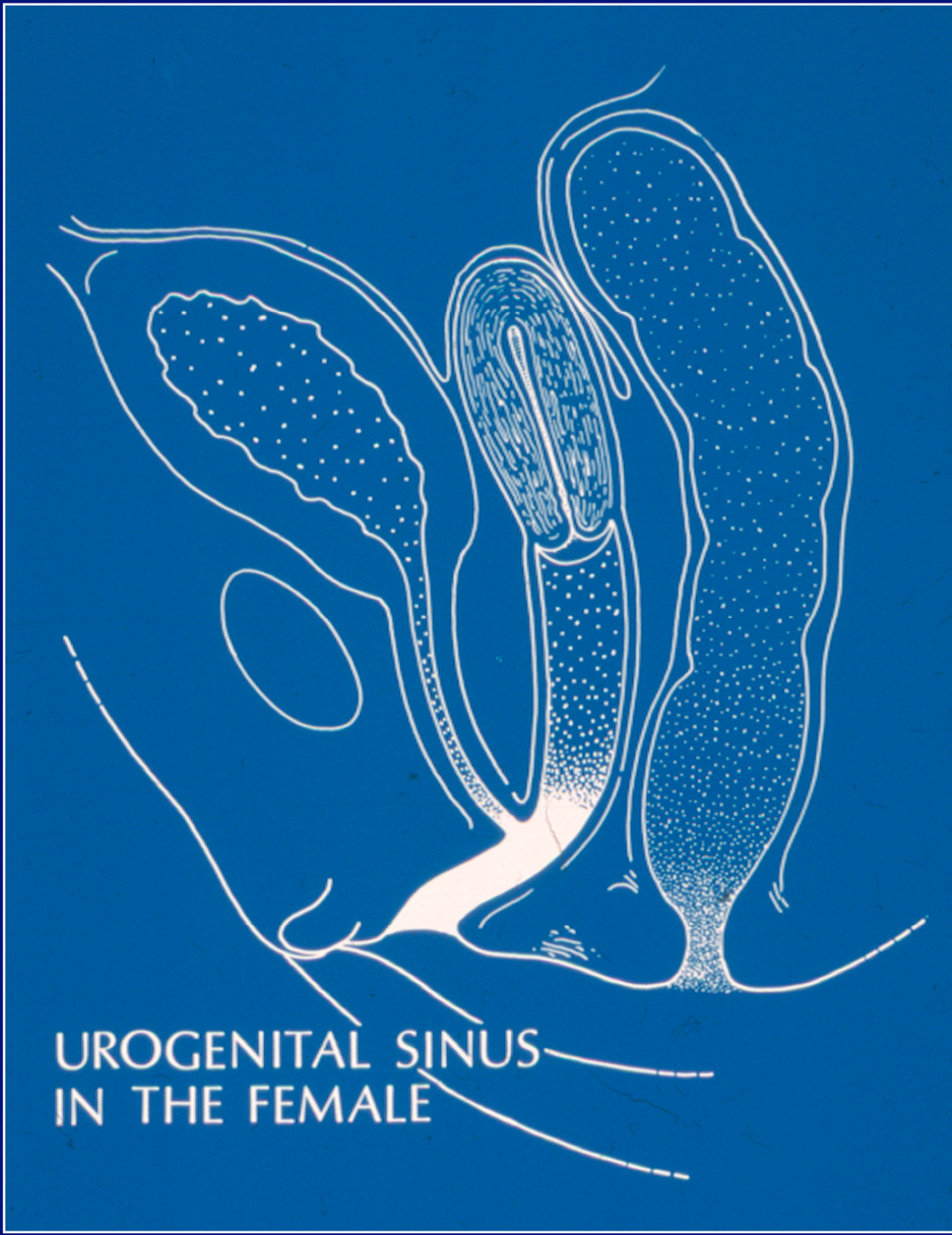
V

Normal ♂

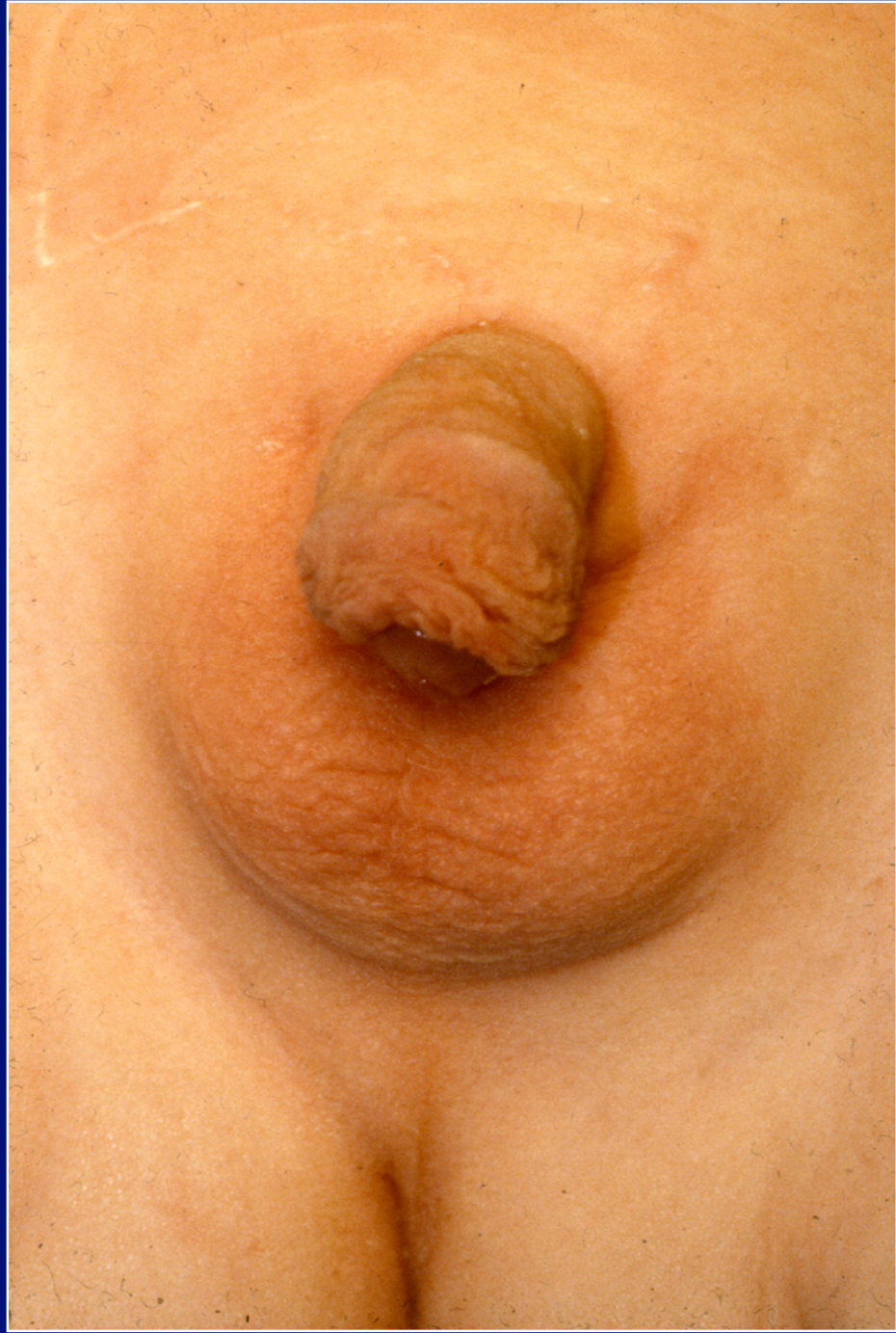

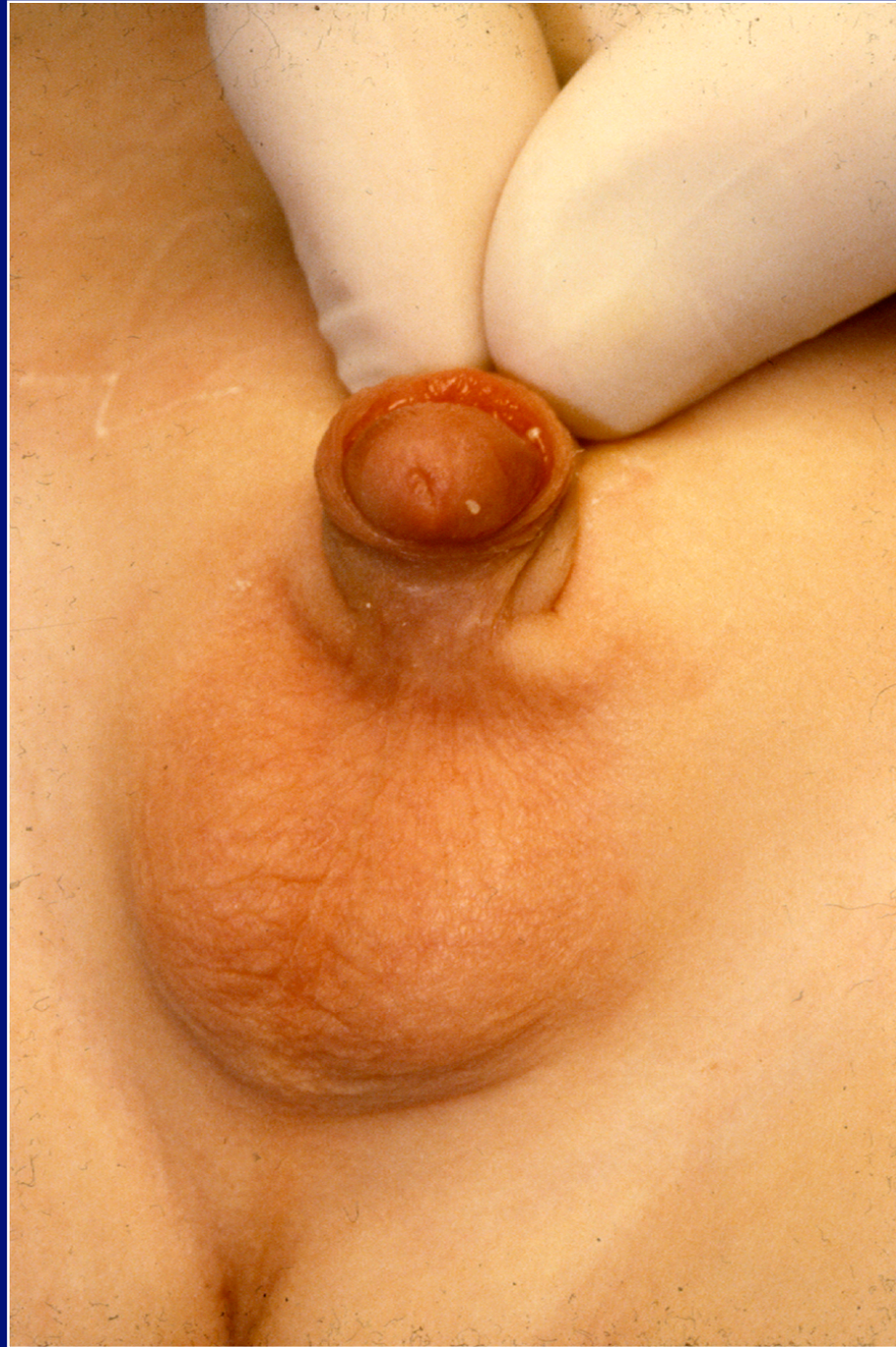


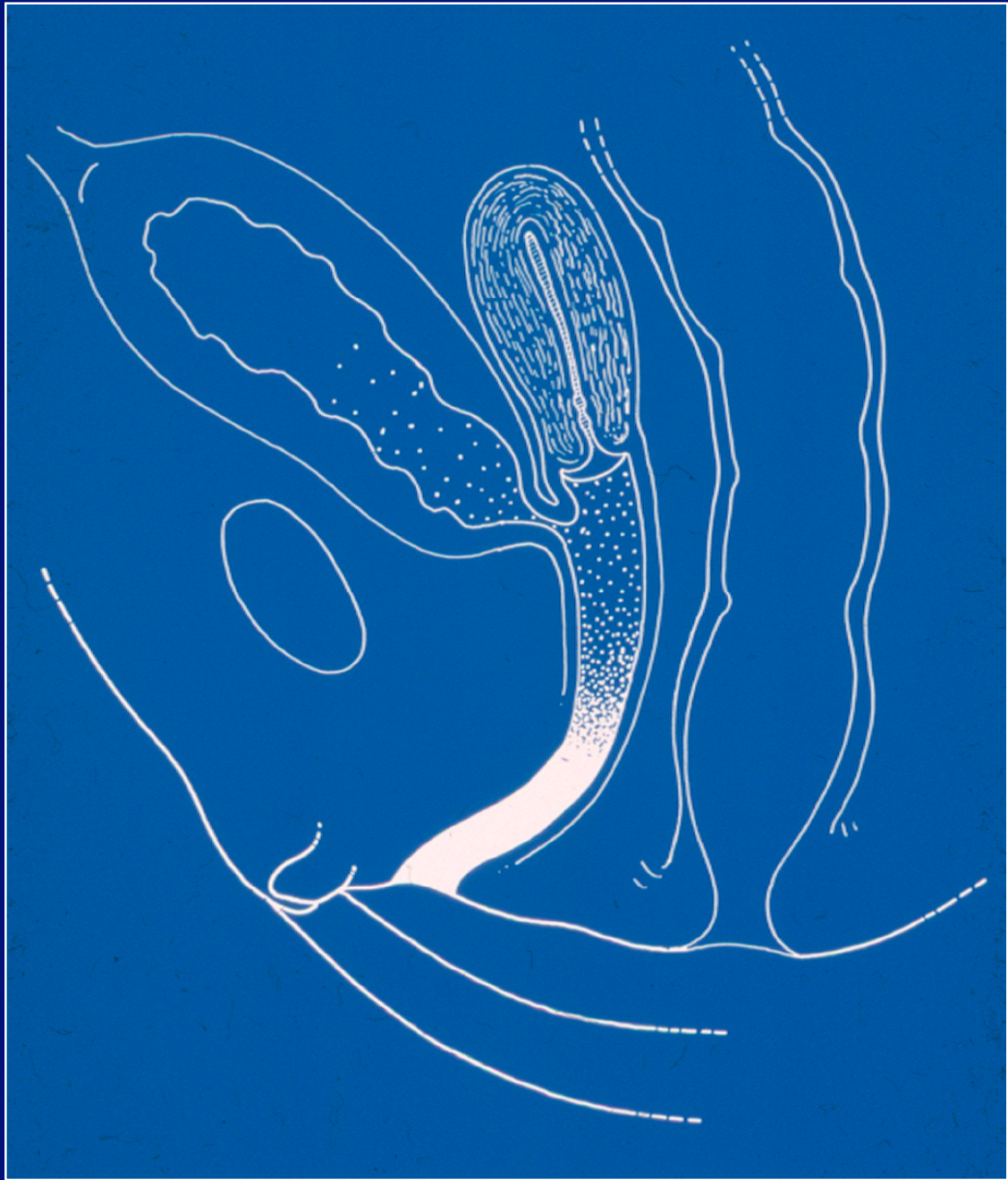




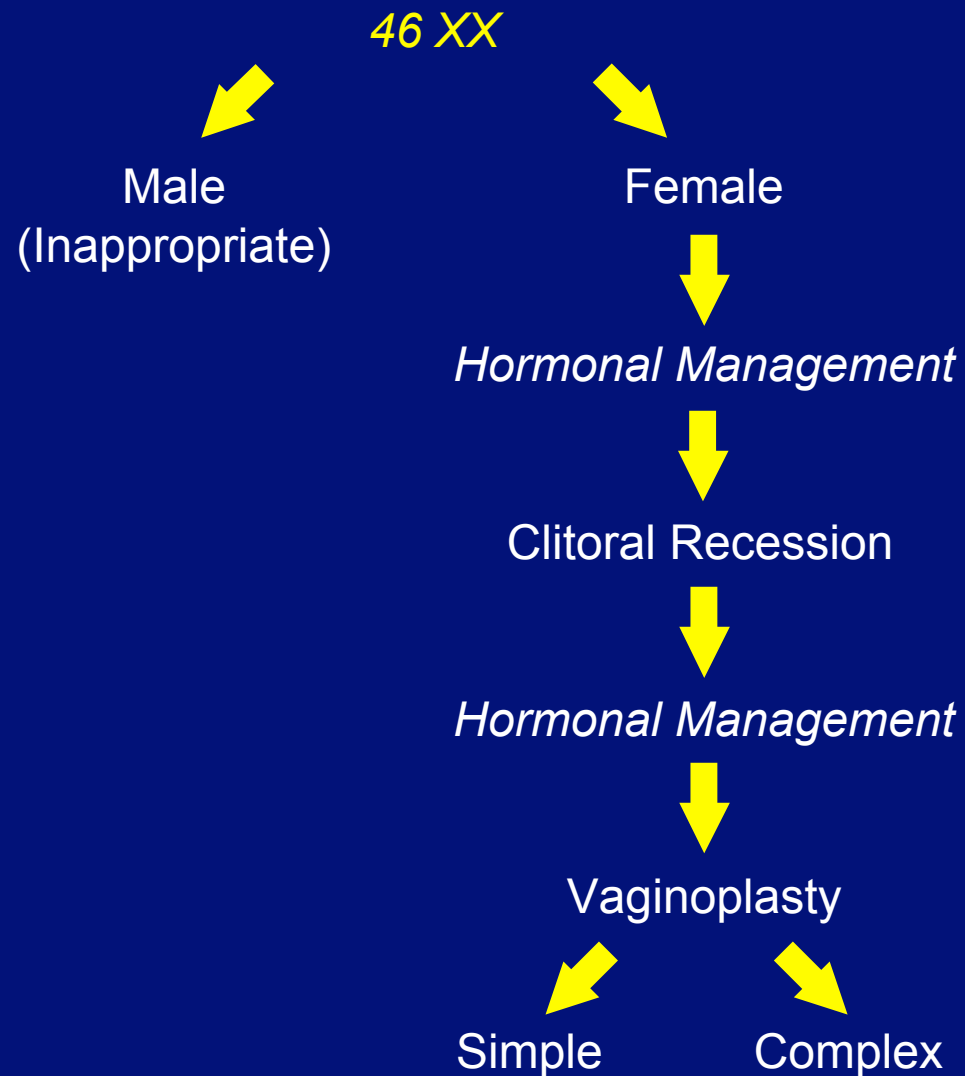
UROGENITAL SINUS
IN THE FEMALE





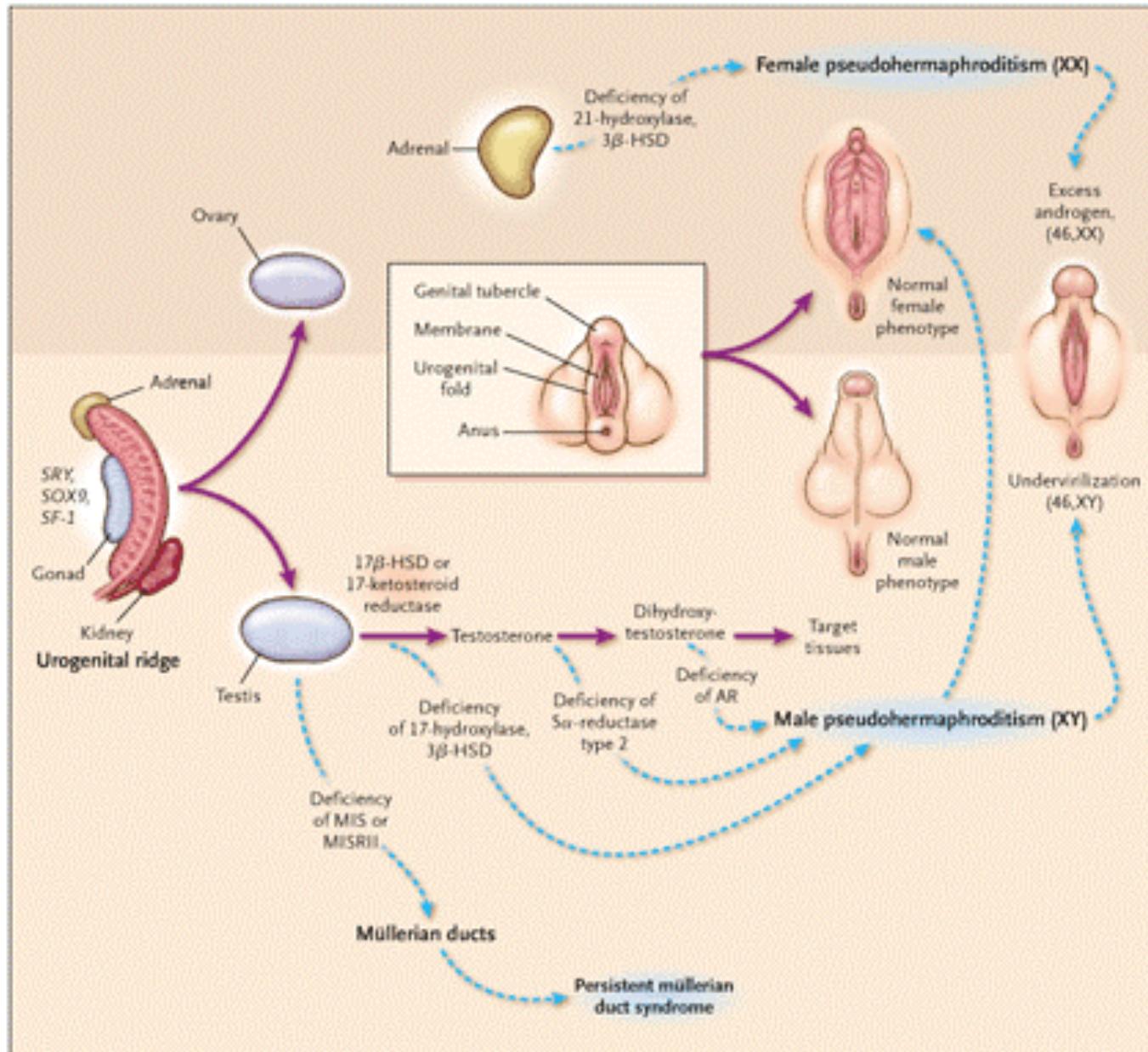


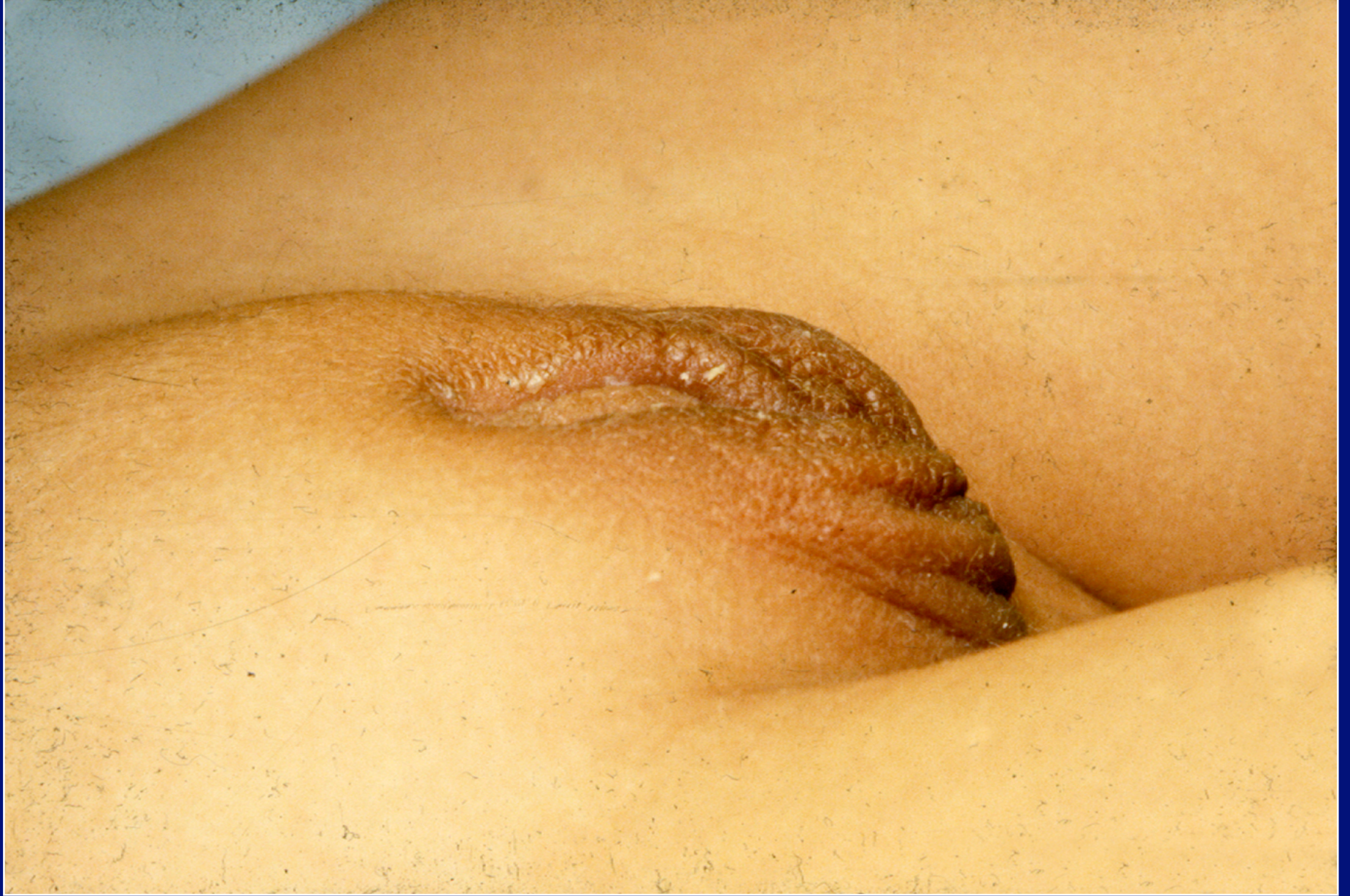Gender Assignment Decision

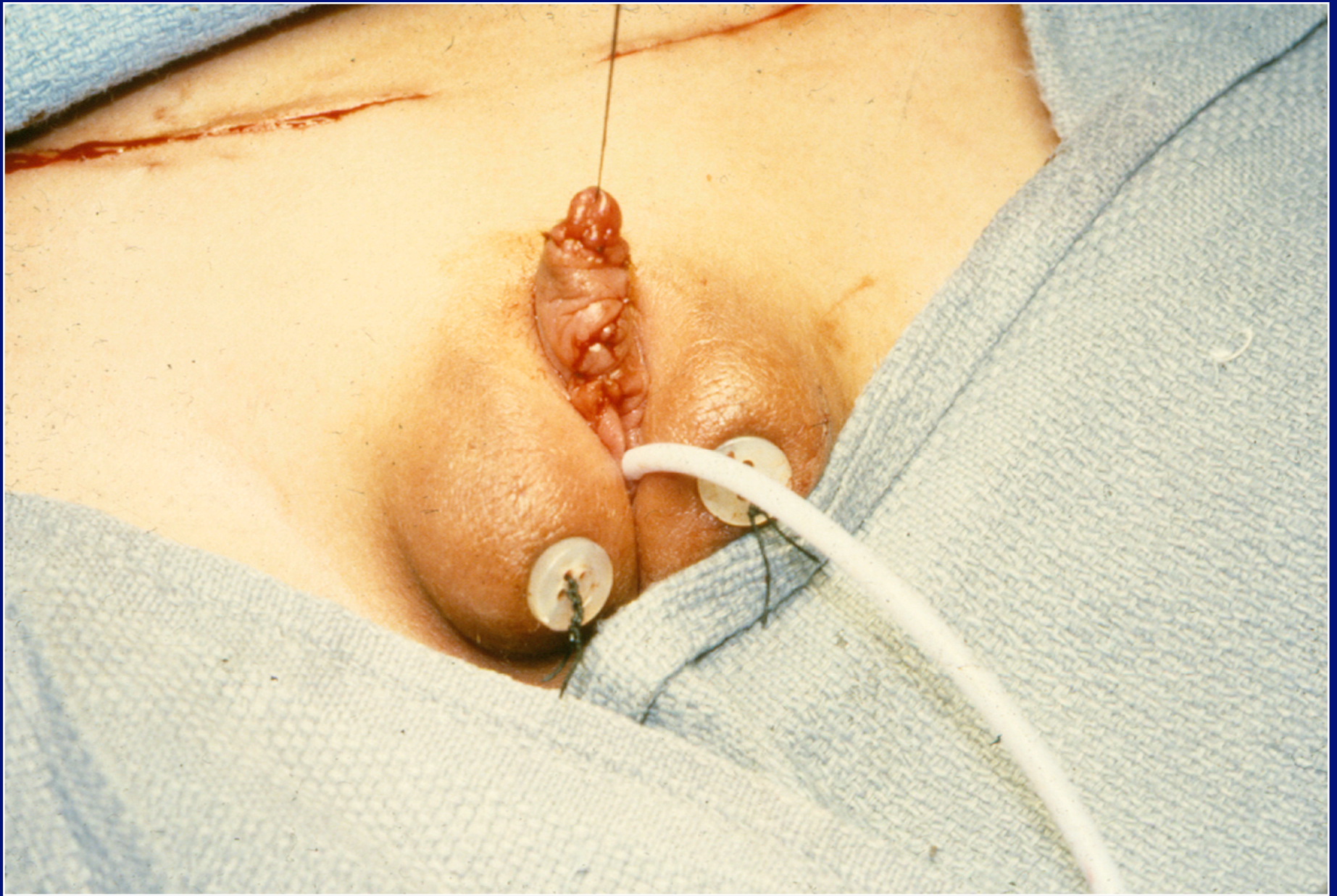


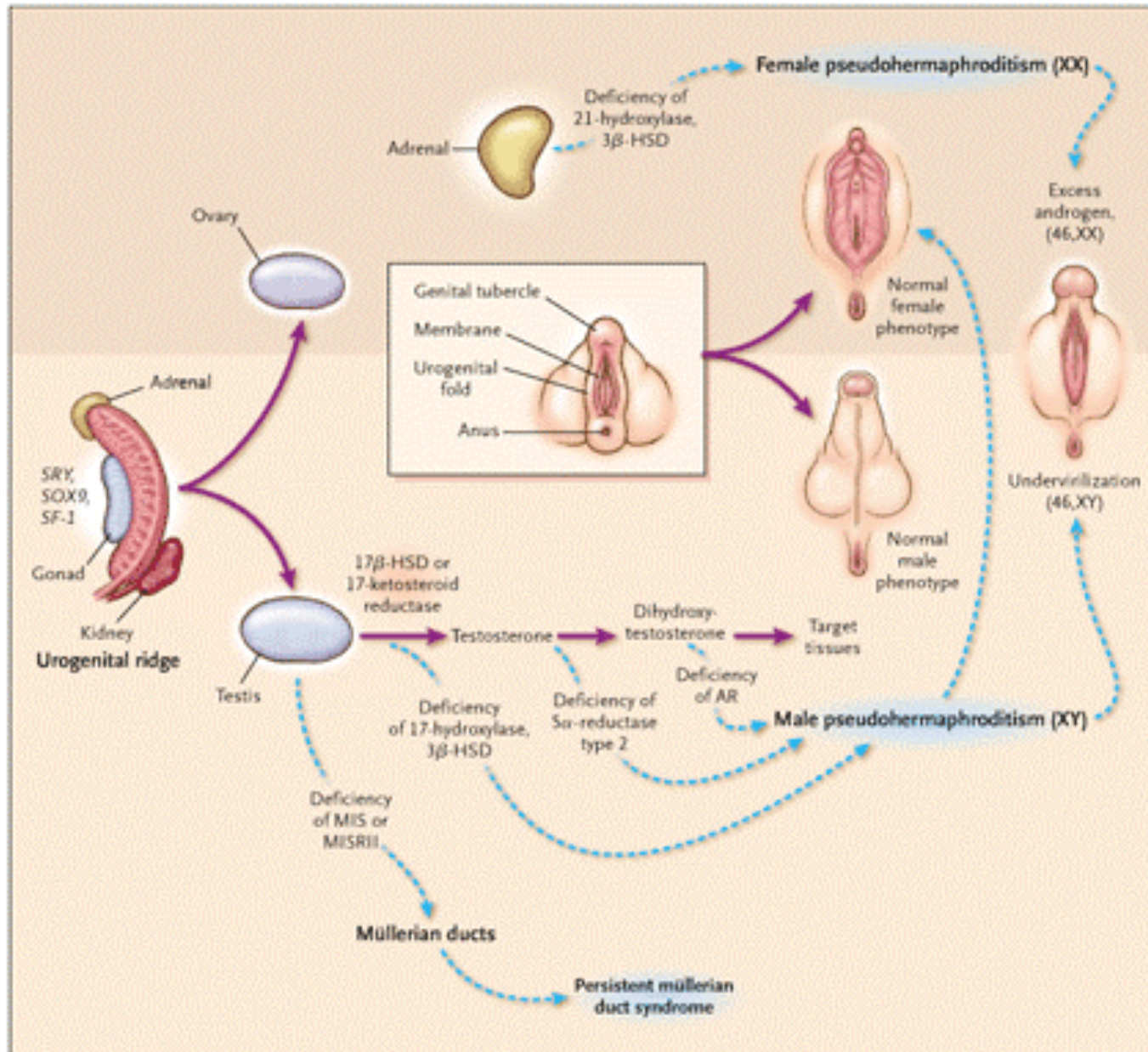
Male Pseudohermaphrodite > Testicular DSD

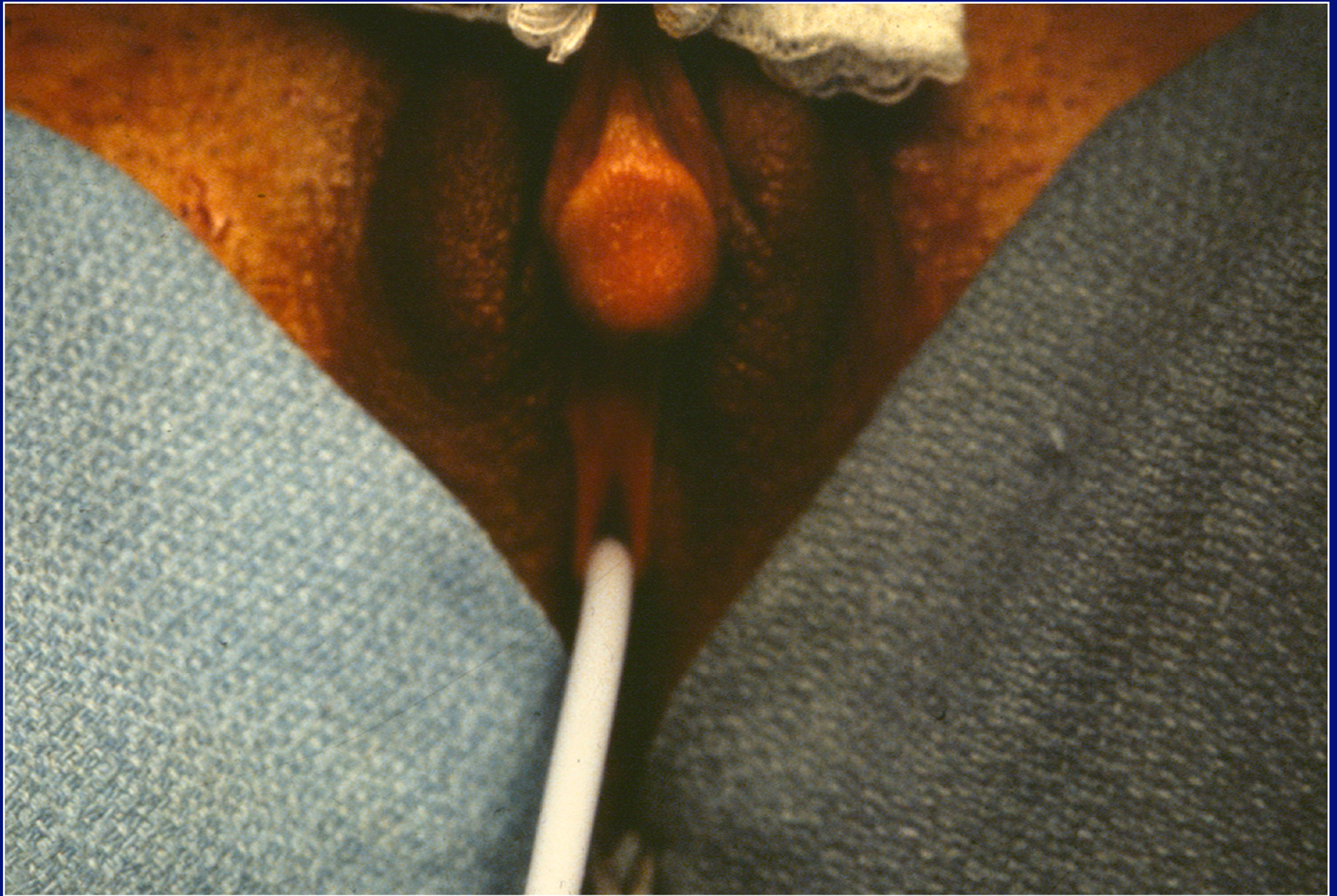- XY Individual - Poorly Virilized
 - ◆ Diminished Androgen Production
 - ◆ Diminished Androgen Response (Spectrum)
 - ◆ Diminished DHT

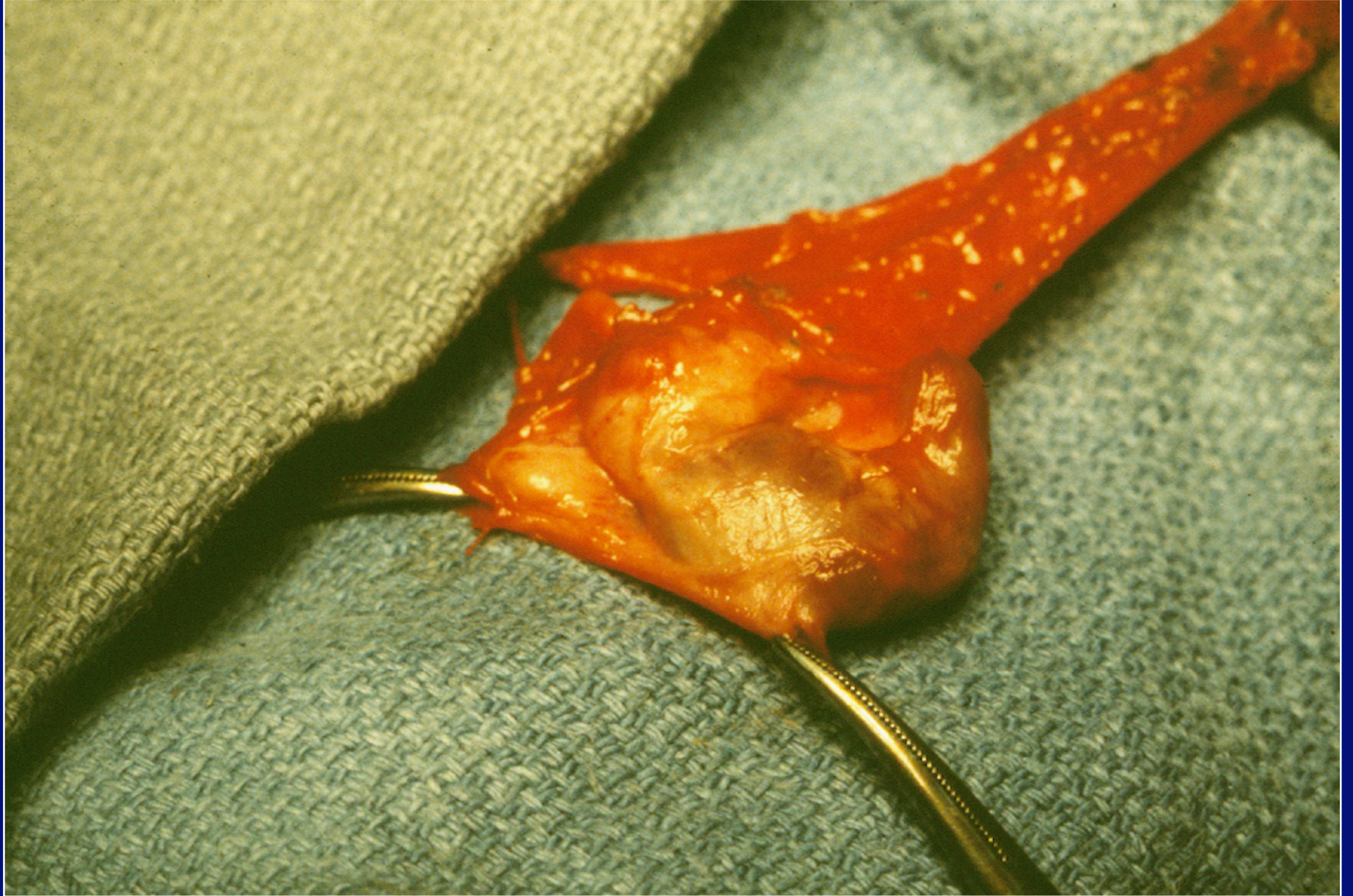


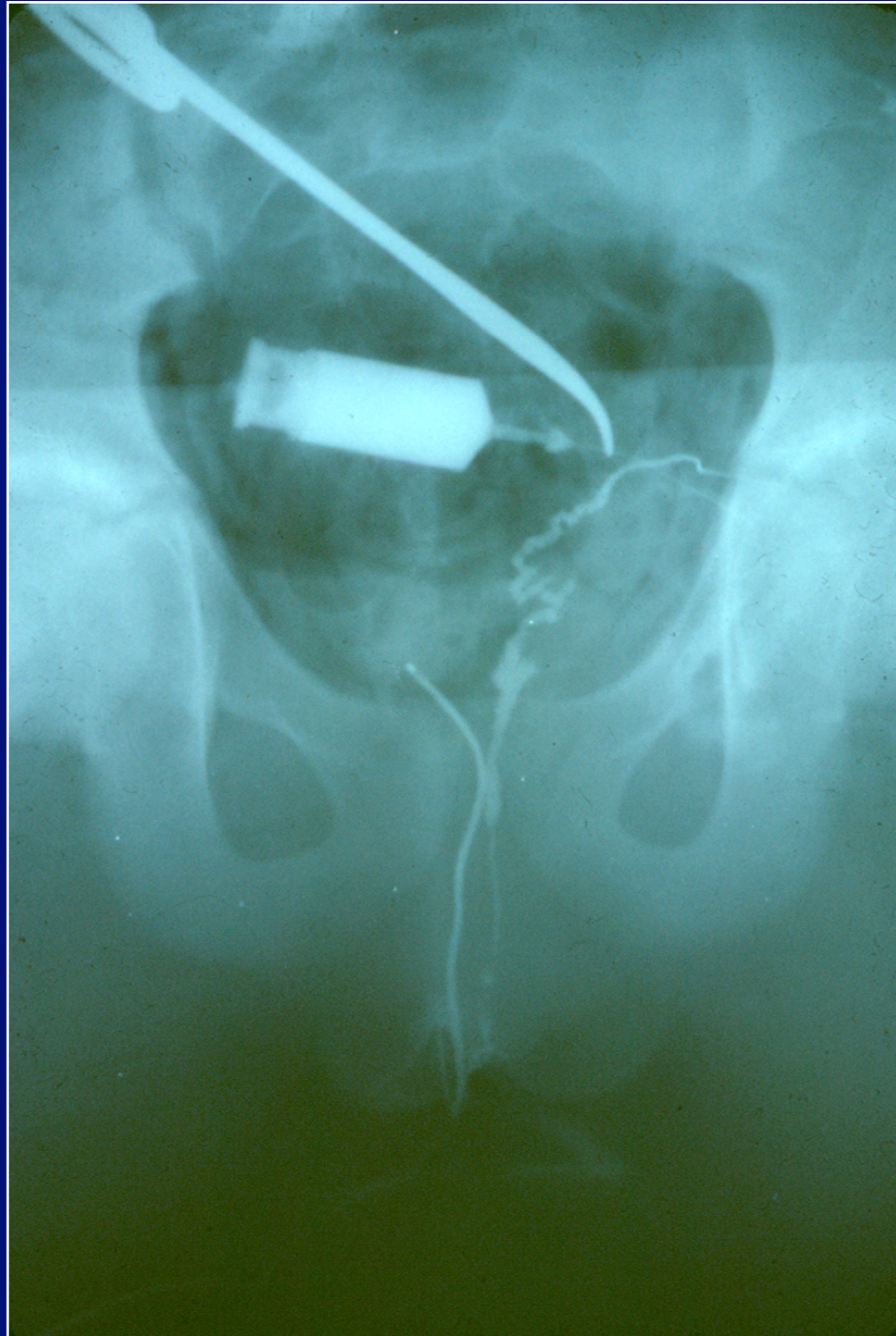


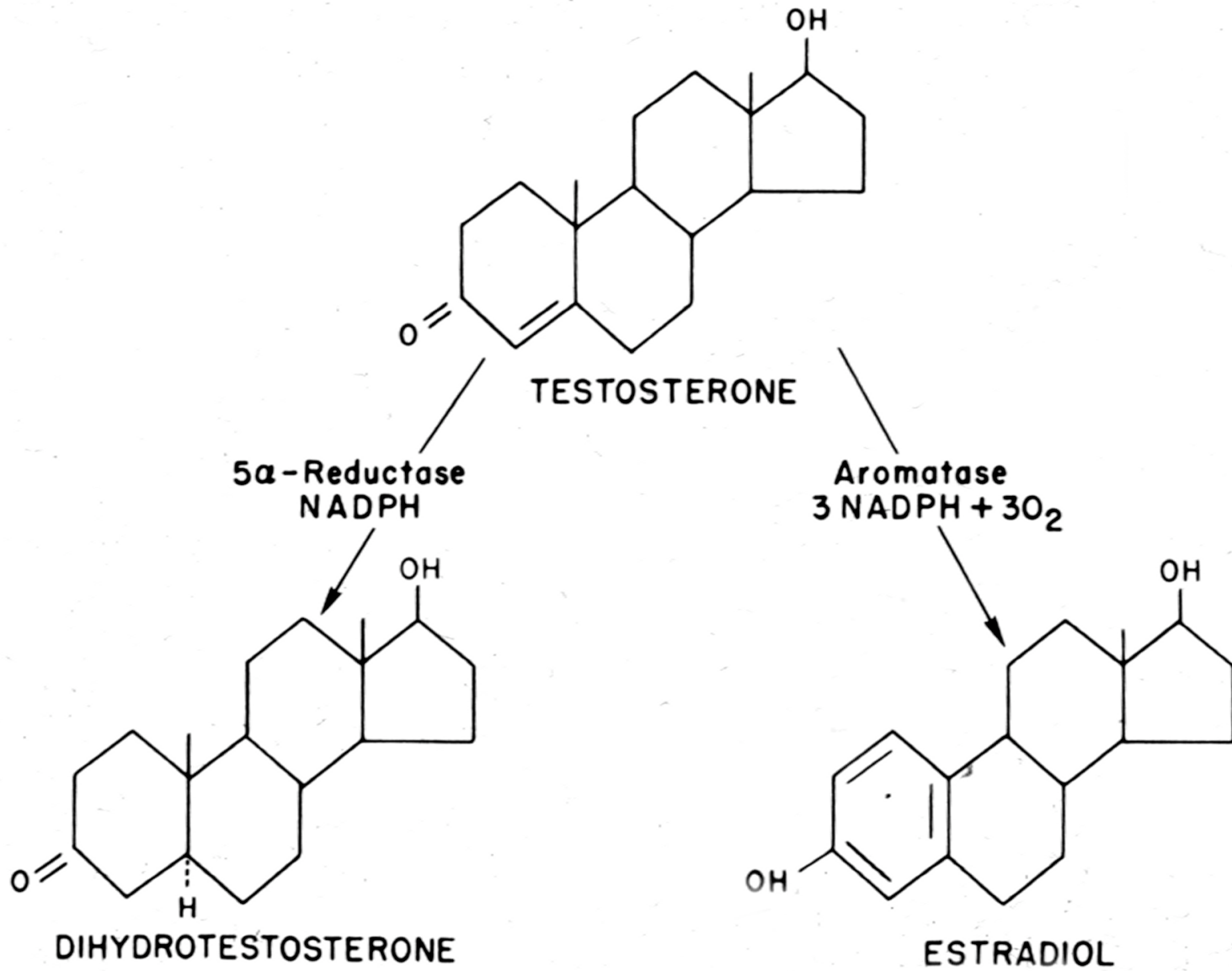


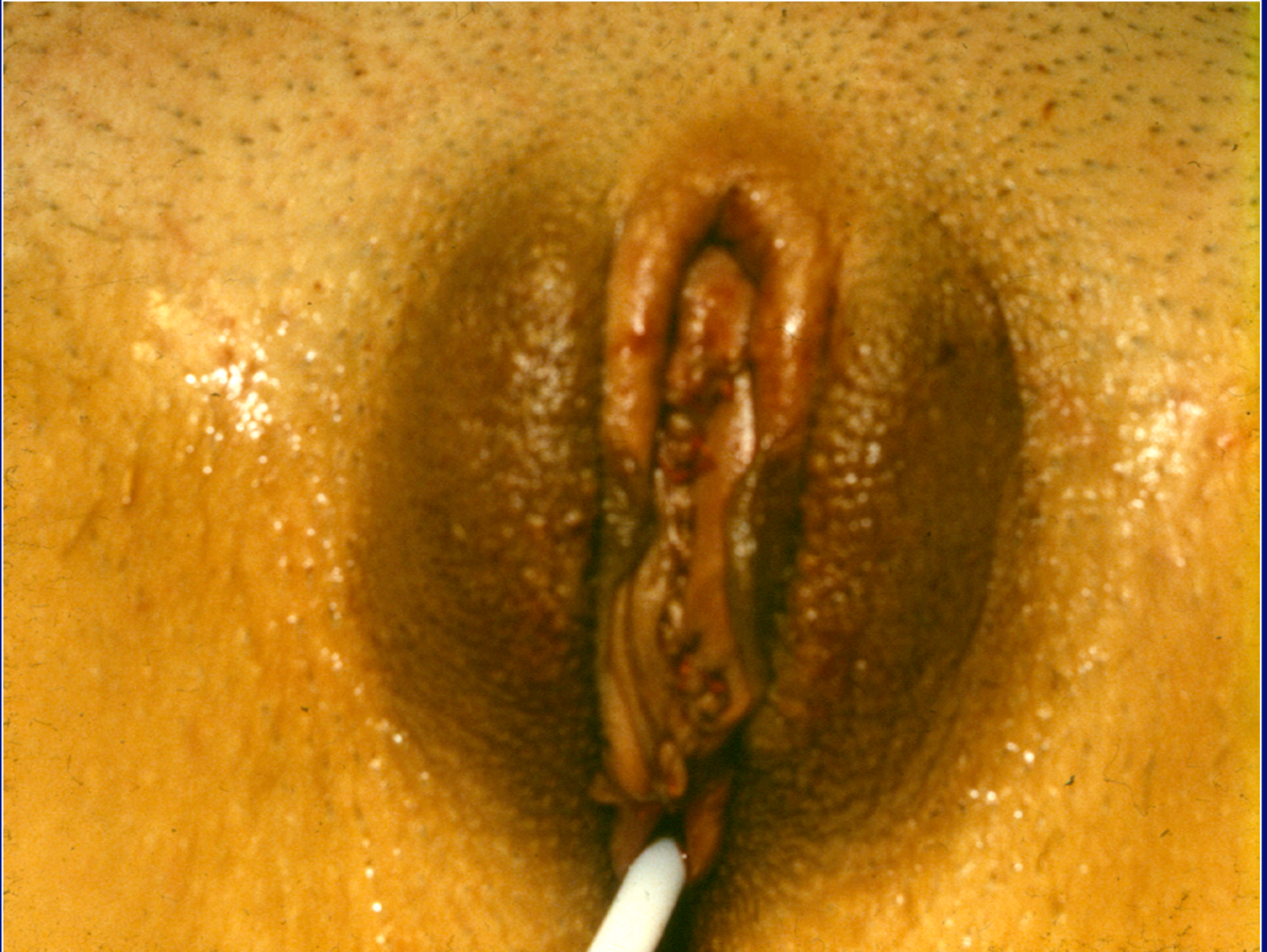

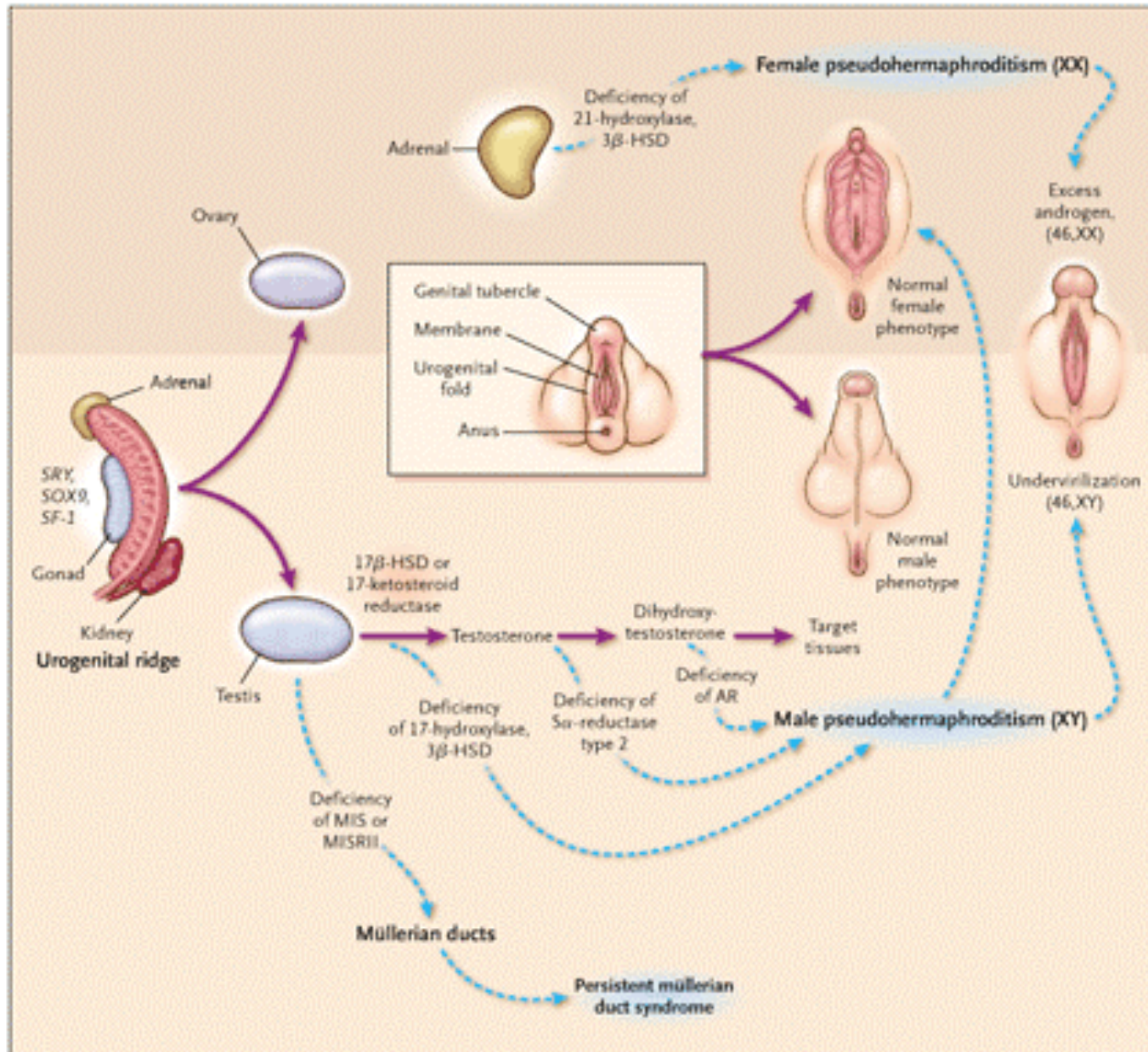





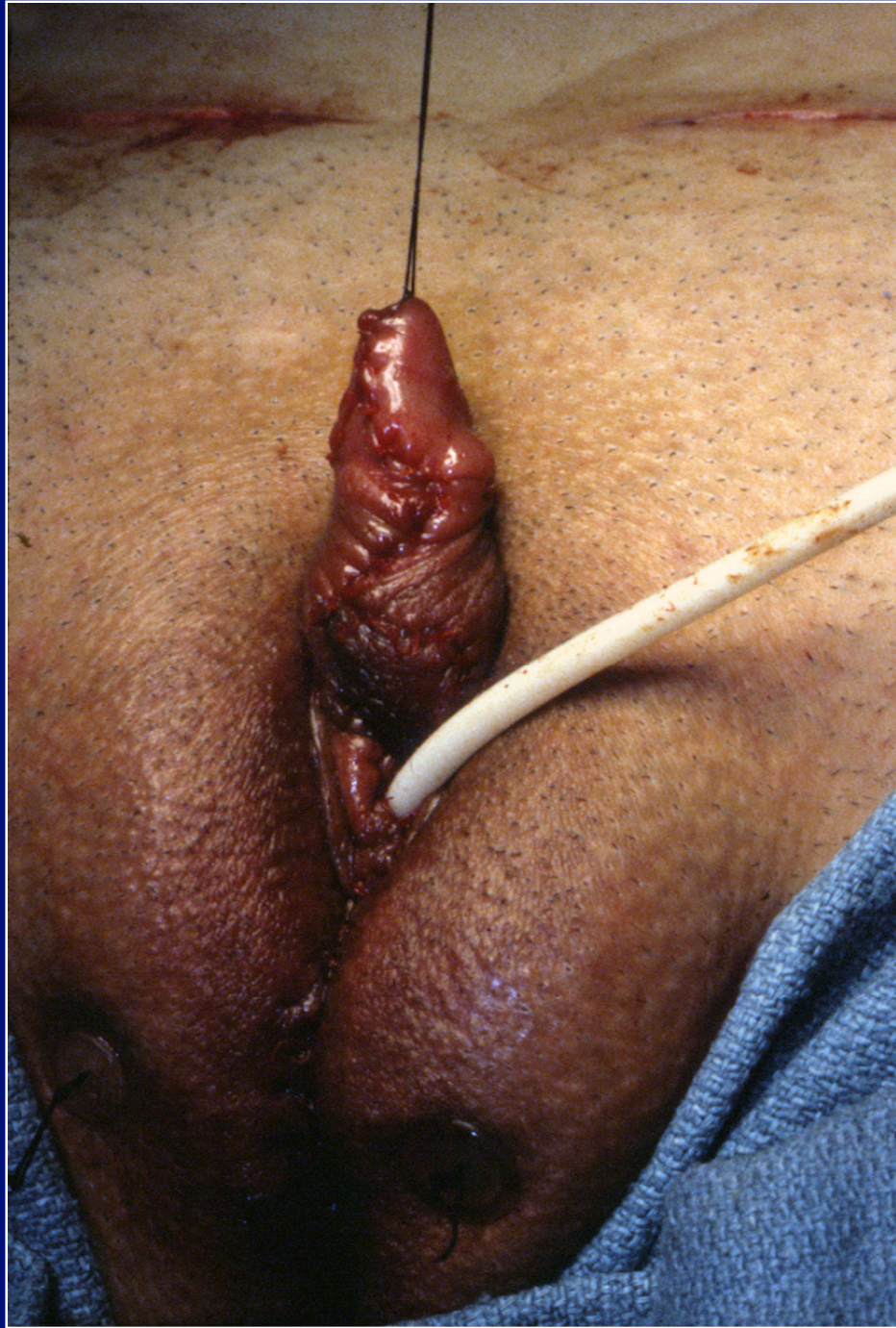


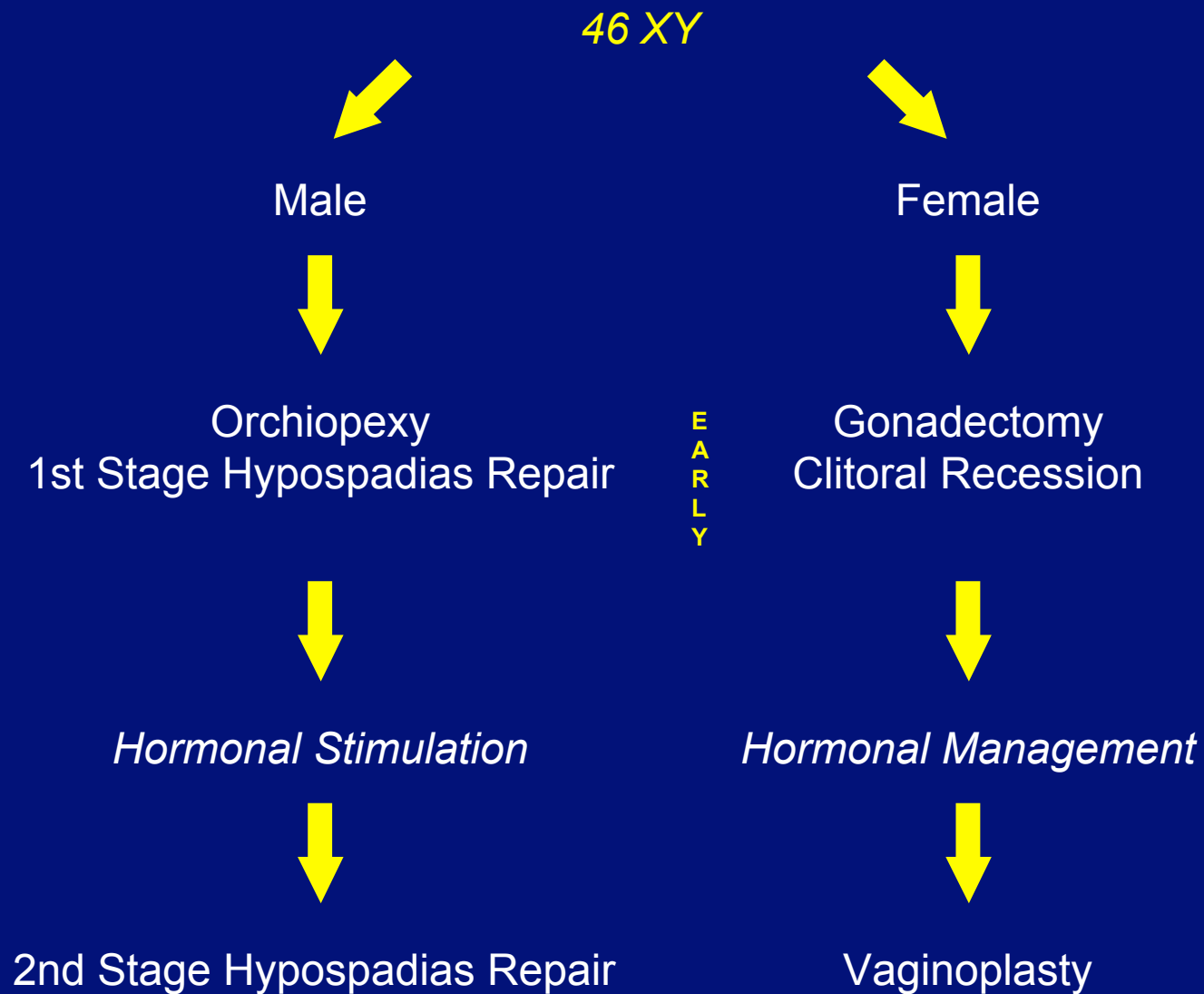








Gender Assignment Decision



Gender Assignment Decision

Conclusions:

1. Maintain gonadal sex whenever possible
2. Gonads inappropriate for gender assignment should come out early.
3. Orchiectomy and Hypospadias Repair are best done early.
4. Clitoral Recession and Vaginoplasty can be delayed.
5. Long-term follow-up and management are essential.

Treatment

Very Early

- Gender Assignment - By Committee
- Steroid Replacement

Early (if necessary)

- Gonadectomy
- Clitoral Recession
- Vaginoplasty/ genitoplasty
- Psycho-endocrine support (family/patient)

© 1978 MEDICAL ECONOMICS COMPANY



**"For the last time, Junior, Mrs. Burda doesn't
want a sex change!"**

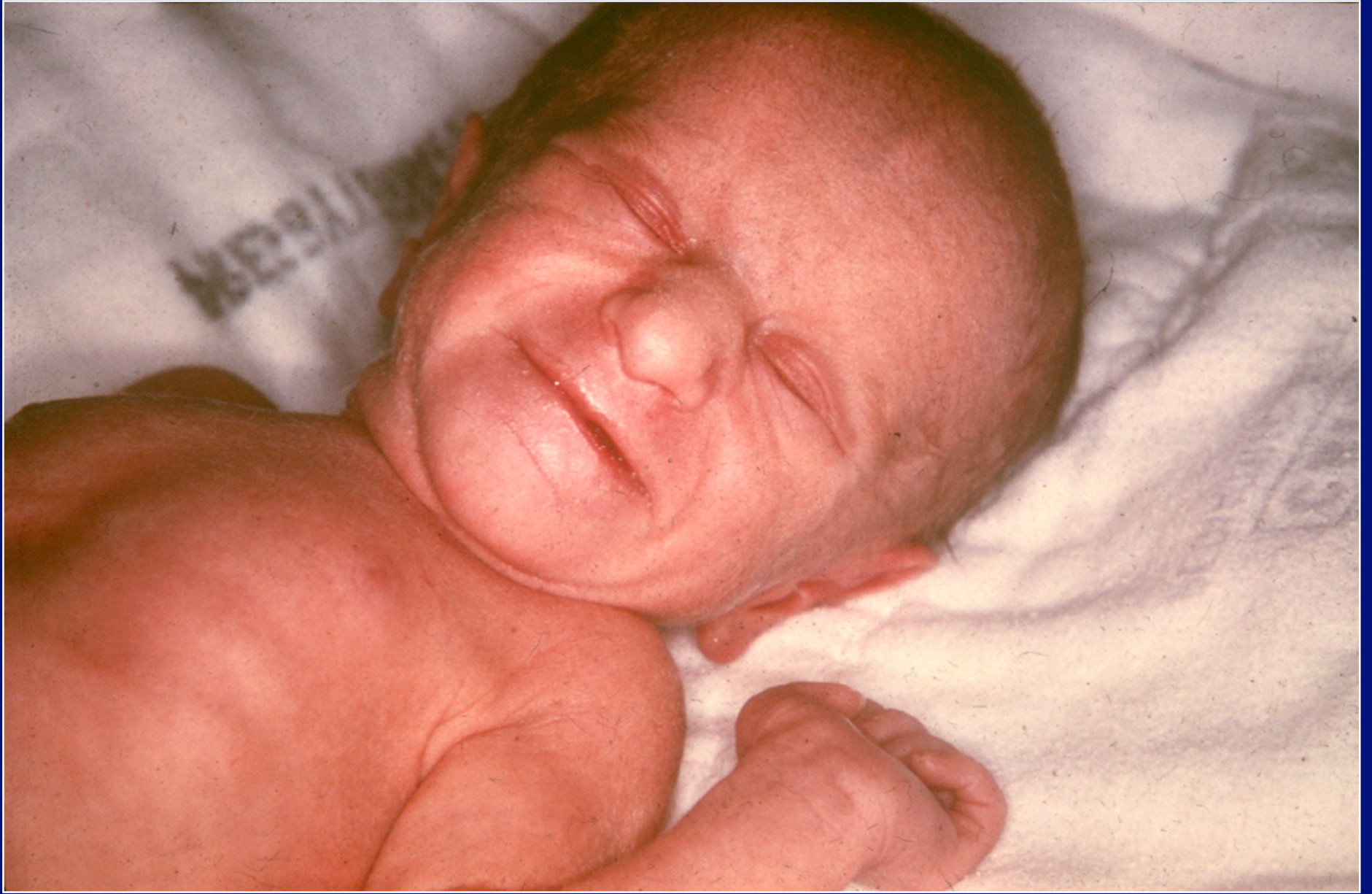[] [] [] [] 9 5 [] [] 8 5 [] [] 9 2

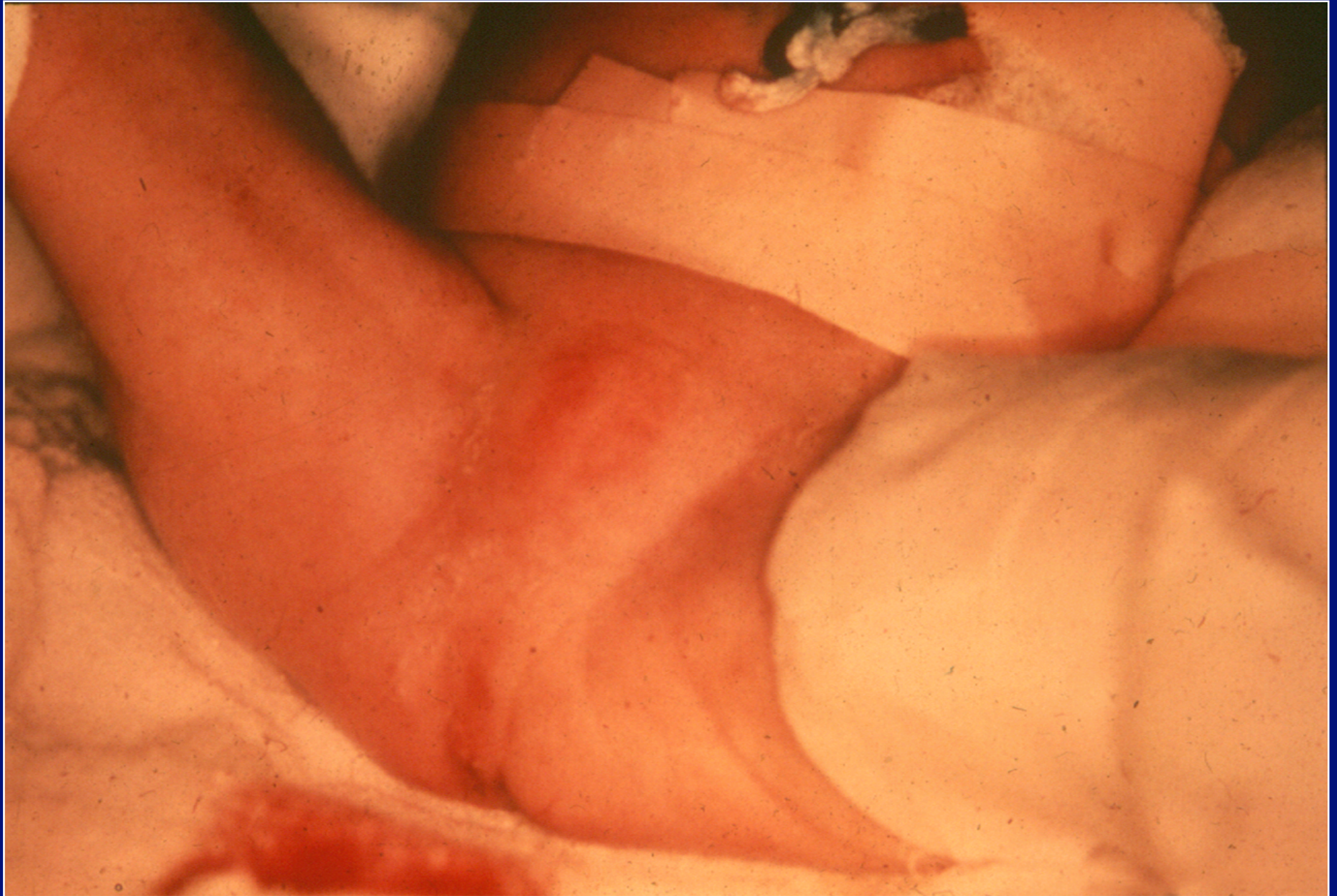
~~Keay, Baby Boy~~ GIRL

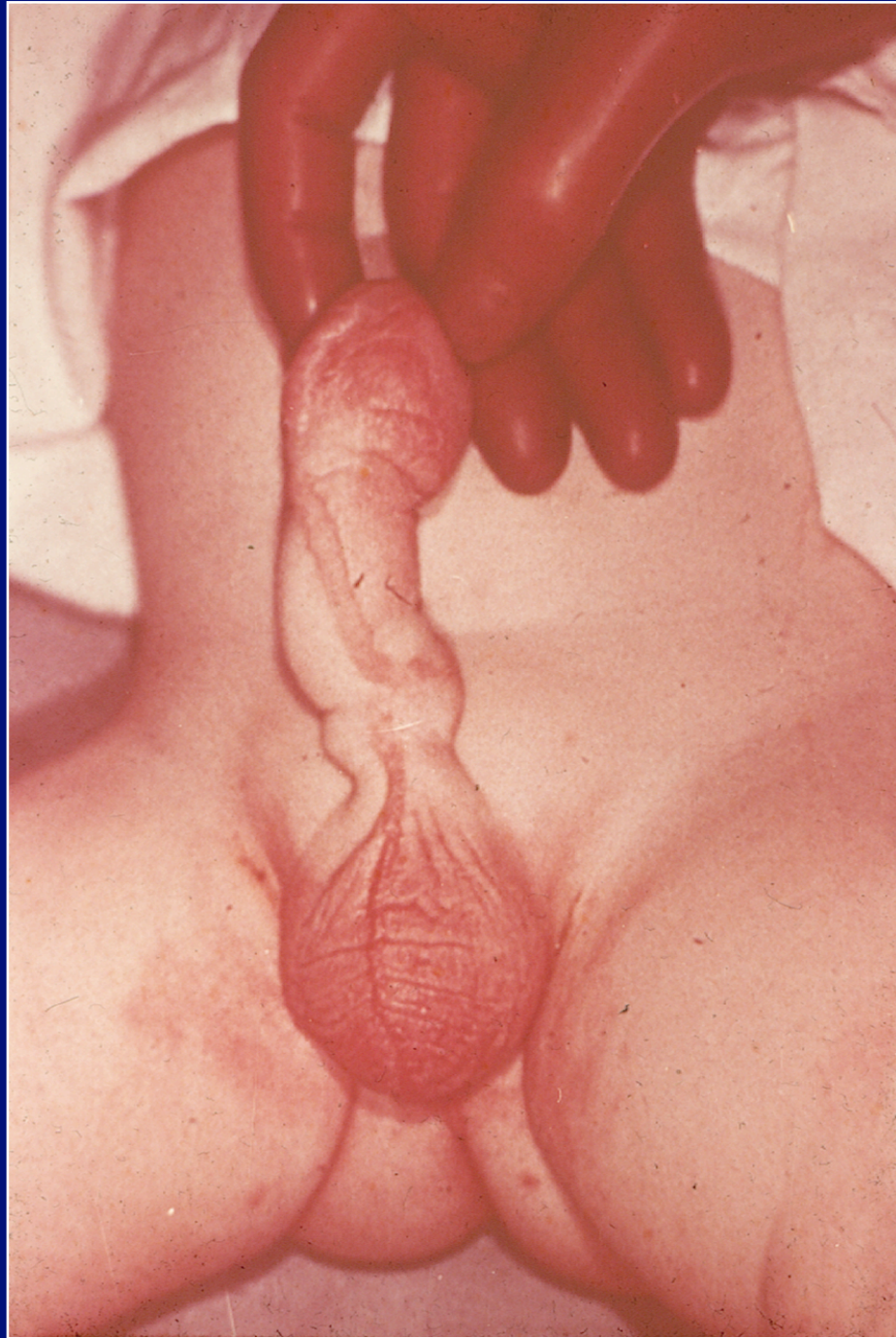CAL CENTER
ERSEY 07601

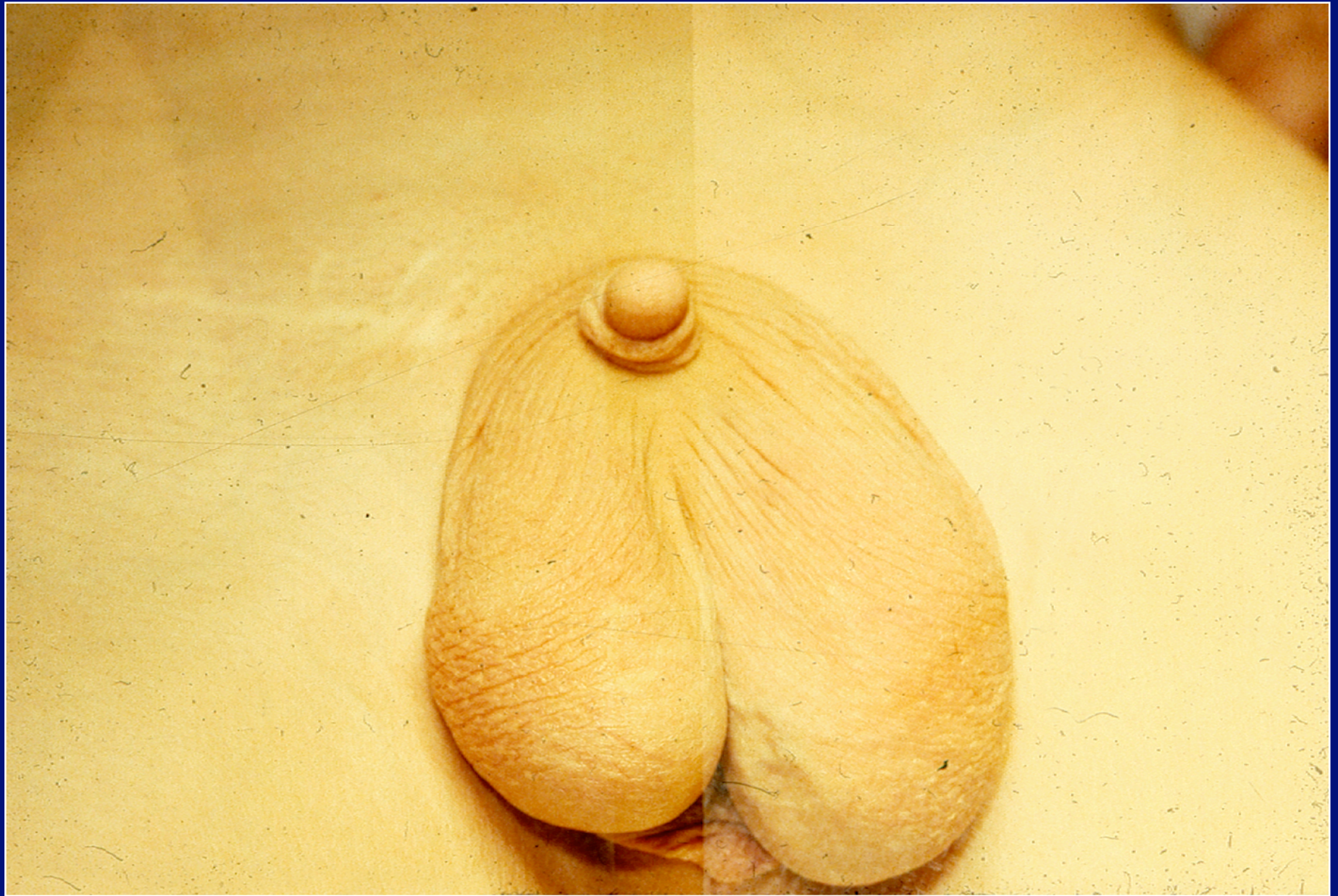
Some originals in LF.

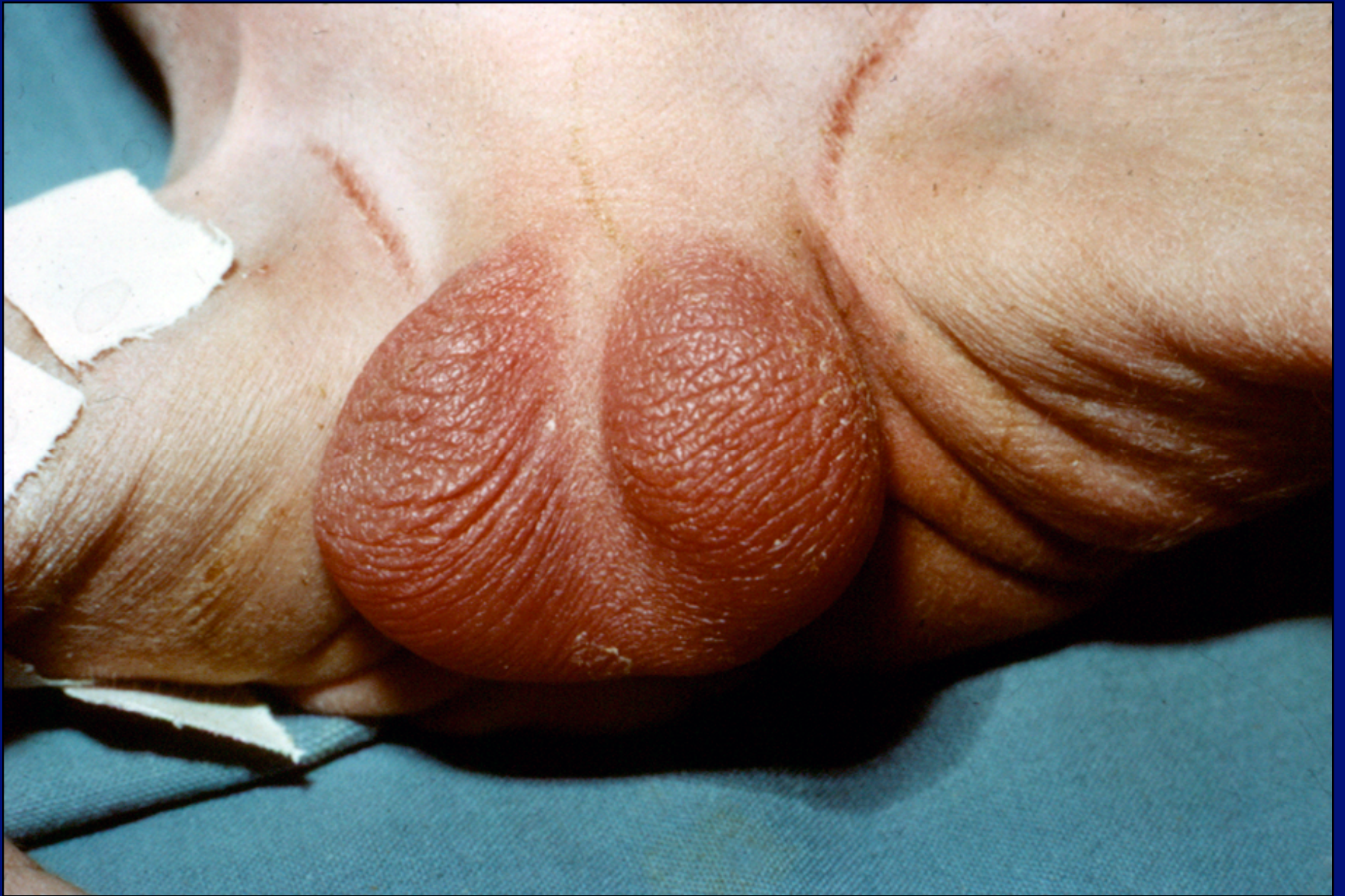OR	REMARKS	DOB
	Repeat - by uterus ultrasound	
	original sinus - bladder	

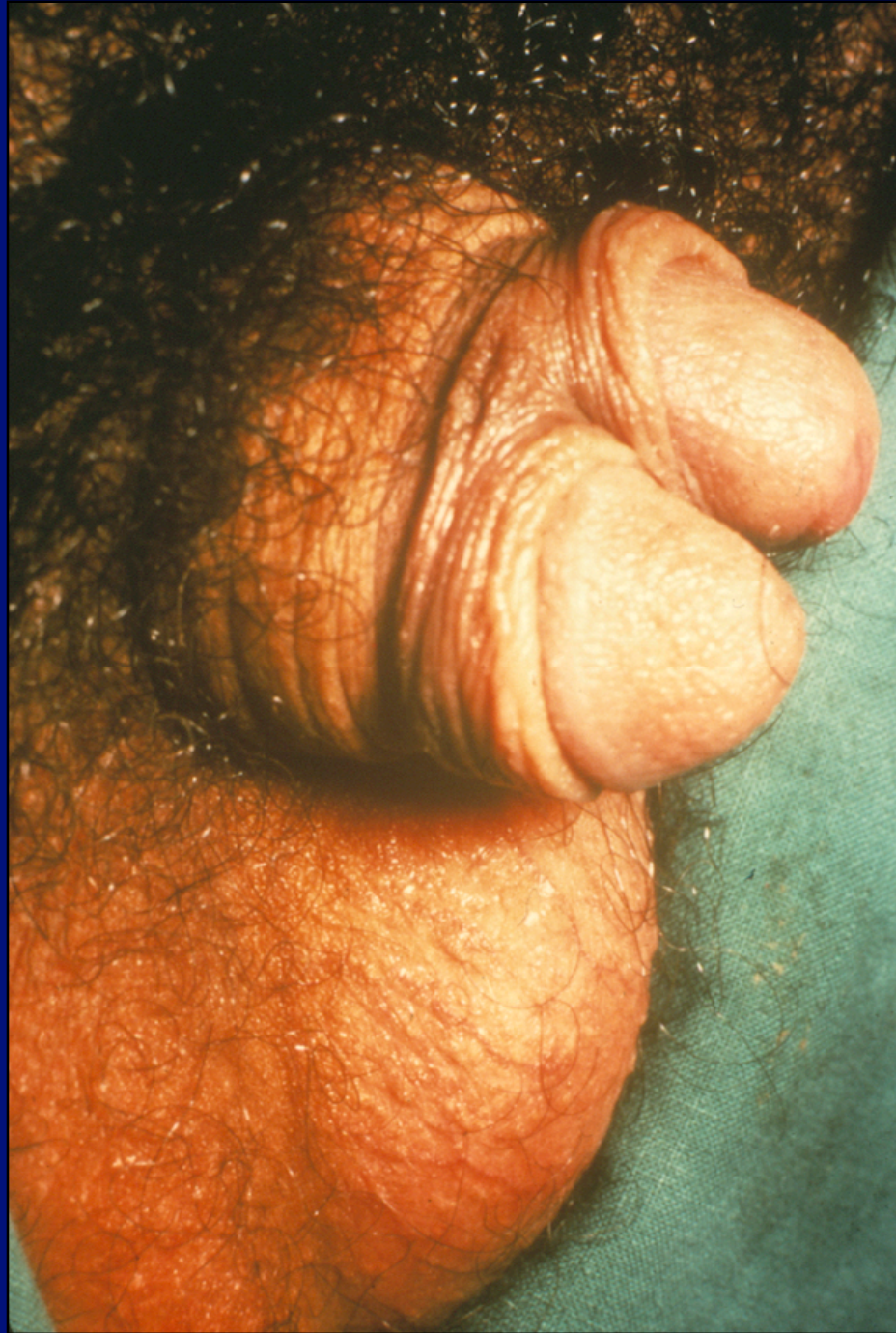


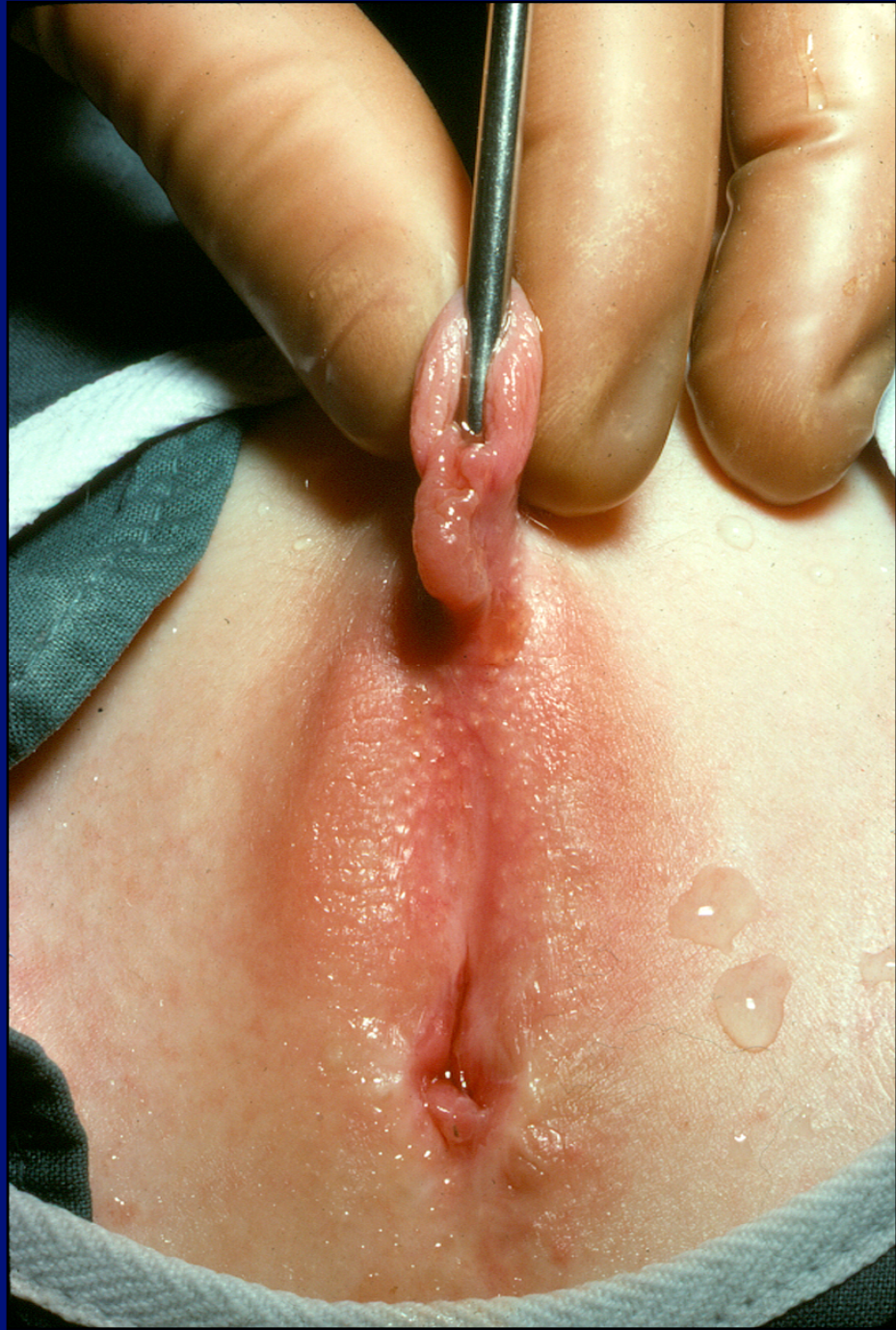










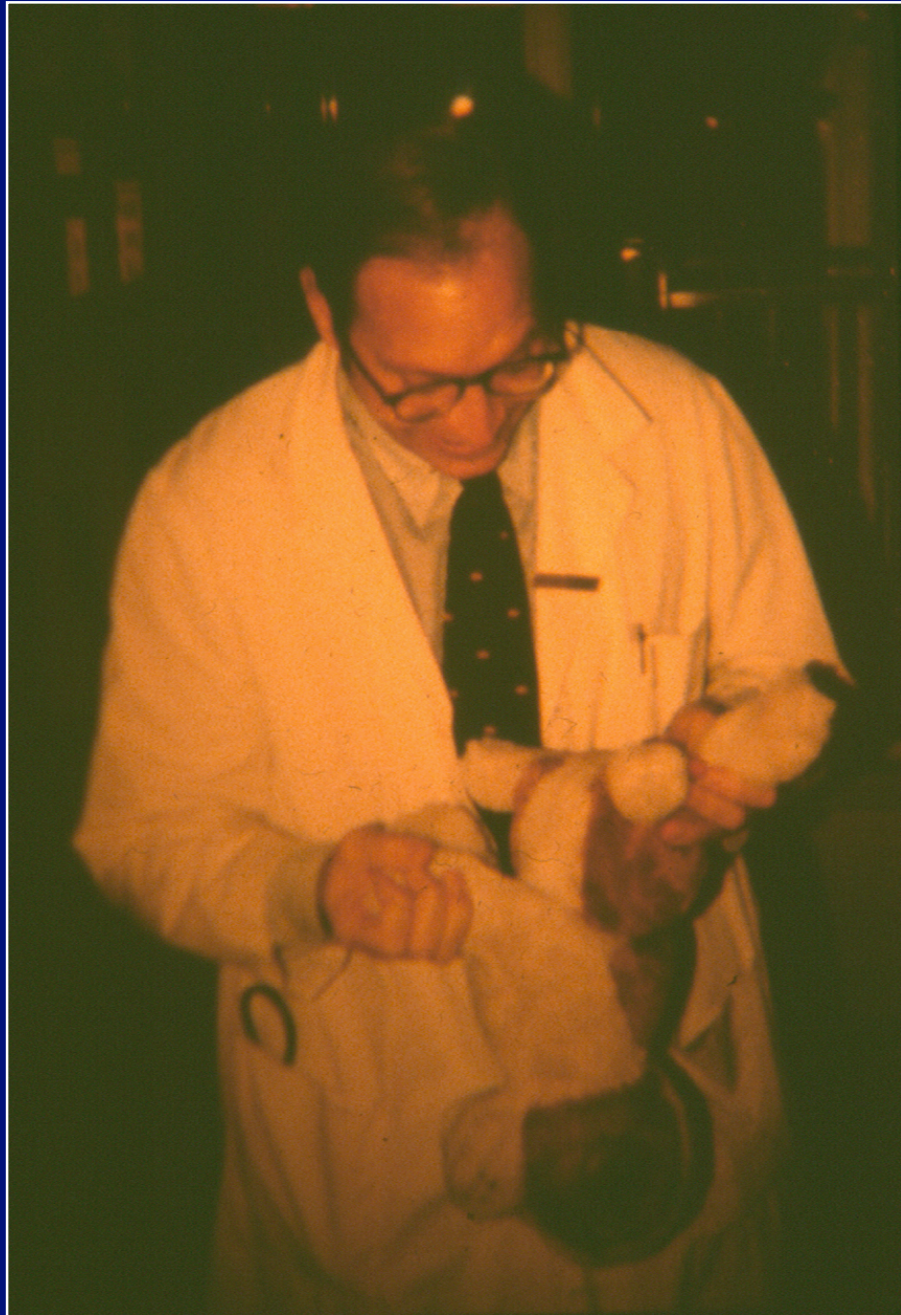
Workup-Initial

History

- Maternal Androgen
- Family History

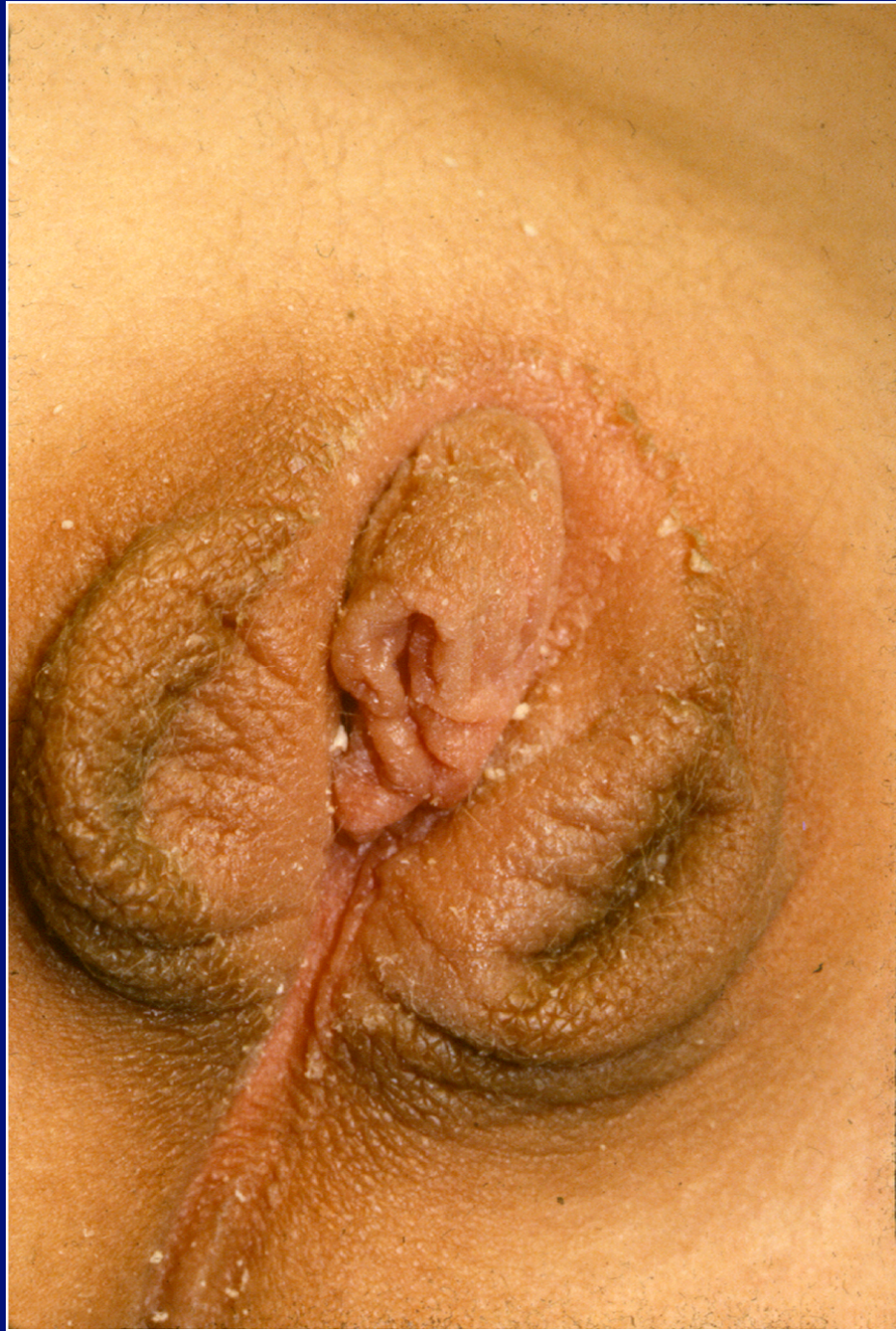Physical Exam

- How Many Openings
- Size of the Phallus
- Palpable Gonads
- Presence of a Uterus



Stretched penile length in normal males. Expressed in *cm.*

S.D.	Mean \pm S.D.	Mean - 2.5
Newborn, 30 weeks	2.5 \pm 0.4	1.5
Newborn, 34 weeks	3.0 \pm 0.4	2.0
Newborn, term	3.5 \pm 0.4	2.4
0-5 months	3.9 \pm 0.8	1.9
6-12 months	4.3 \pm 0.8	2.3
1-2 years	4.7 \pm 0.8	2.6
2-3 years	5.1 \pm 0.9	2.9
3-4 years	5.5 \pm 0.9	3.3
4-5 years	5.7 \pm 0.9	3.5
5-6 years	6.0 \pm 0.9	3.8
6-7 years	6.1 \pm 0.9	3.9
7-8 years	6.2 \pm 1.0	3.7
8-9 years	6.3 \pm 1.0	3.8
9-10 years	6.3 \pm 1.0	3.8
10-11 years	6.4 \pm 1.1	3.7
Adult	13.3 \pm 1.6	9.3



Workup - Early

- Karyotype
- Biochemical Markers
- *SRY Gene*

LATER

- Genitogram
- Laparoscopy +/- Gonadal BX

Surgical Goals

- Sexually Functional
- Cosmetically Acceptable

Conclusions

- Gender Assignment Is a Medical Emergency
- A Multidisciplinary Gender Assignment Committee Should be Utilized
- The Gonadal Sex Should Be Maintained whenever Possible
- If Gonadal Sex Is Not Maintained, Early Gonadectomy Is Important



There is a difference