

## Teratology

Wendy Chung, MD PhD

### Mrs. B

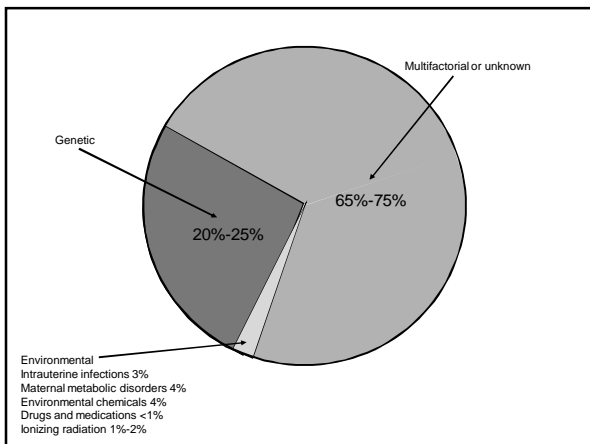
- 30 year old woman comes to you because her 20 week prenatal ultrasound showed a hole in the heart
- Patient and her husband have many questions:
  - What caused this birth defect?
  - Was it caused by the glass of wine she had before she found out she was pregnant?
  - Will there be other problems for this child?
  - If they have other children, what is the risk of recurrence?

## Teratology

- The study of abnormal development in embryos and the causes of congenital malformations or birth defects

## Birth Defects

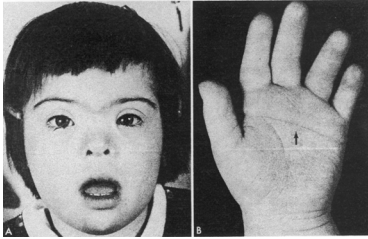
- Observed in 3% of newborns
- Observed in another 3% of children later
- Account for 20% of perinatal deaths
- May or may not be outwardly visible
- Etiology: genetic and environmental



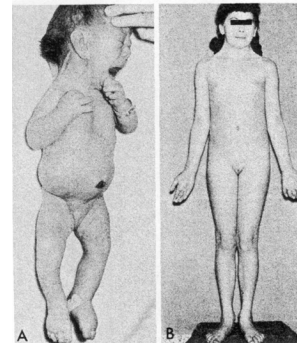
## Major and Minor Anomalies

- Major anomalies: life/health threatening
- Minor anomalies: cosmetic
  - May be seen in 14% of newborns
- The greater the number of minor anomalies, the greater the likelihood of a major anomaly
- Certain minor anomalies suggest specific major anomalies

### Down Syndrome



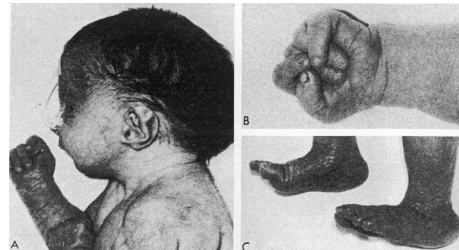
### Turner Syndrome



### Trisomy 13

- Midline defects (cleft lip and cleft palate)
- Central nervous system malformations
- Micro-ophthalmia
- Congenital heart disease
- Poor growth

### Trisomy 18



### Mrs. B

- Extensive ultrasound examination does not identify other major anomalies
- Can minor anomalies be excluded?
- An amniocentesis is performed and is normal
- Are genetic etiologies excluded?

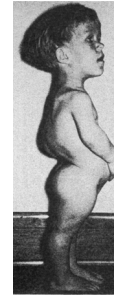### Inborn Errors of Metabolism Causing Birth Defects

- Smith Lemli Opitz
- Congenital disorders of glycosylation
- Fatty acid oxidation disorders

### Single genes cause developmental disorders

- PAX6: aniridia
- NEUROD1: pancreatic agenesis
- TTF1: thyroid agenesis
- NKX2.5: congenital heart disease
- ZIC3: holoprosencephaly
- Doublecortin: lissencephaly

### Achondroplasia-FGFR3



### Teratogens

- A chemical, infectious agent, physical condition, or deficiency that, on fetal exposure, can alter fetal morphology or subsequent function
- Teratogenicity depends upon the ability of the agent to cross the placenta
- The embryo is most susceptible to teratogenic agents during periods of rapid differentiation

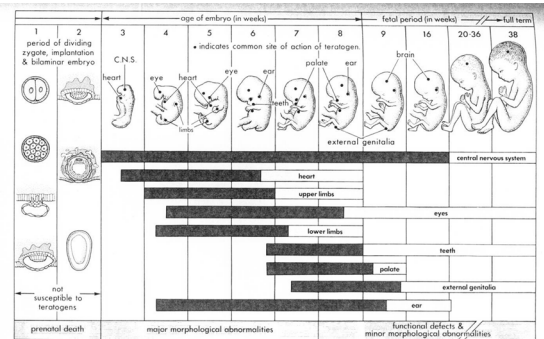


Figure 8-14 Schematic illustration of the critical periods in human development. During the first two weeks of development, the embryo is usually not susceptible to teratogens. During these pro-differentiation stages, a substance either damages all or most of the cells of the embryo, resulting in its death, or damages only a few cells, allowing the embryo to recover without developing defects. Red denotes highly sensitive periods; yellow indicates stages that are less sensitive to teratogens. Severe mental retardation may result from the exposure of the embryo/foetus to certain teratogenic agents, e.g., high levels of radiation during the 8- to 16-week period.

Tissue	Malformation	Defect	Timing of Cause	Additional Information
Central nervous system	Holoprosencephaly	Prochordal mesoderm	22 days	Associated facial defects
	Anencephaly	Closure of anterior neural tube	26 days	Subsequent degeneration of forebrain
Face	Meningocele	Closure in portion of posterior neural tube	28 days	80% lumbosacral
	Cleft lip	Closure of lip	36 days	42% associated with cleft palate
	Branchial sinus or cyst	Regulation of branchial cleft	8 weeks	Protrudes and along line anterior to sternohyoid muscle
Neck	Robin sequence	Early mandibular hypoplasia	9 weeks	Unfused posterior cleft palate
	Cleft maxillary palate	Fusion of maxillary palatal shelves	10 weeks	
Abdomen	Esophageal atresia and tracheoesophageal fistula	Lateral migration of foregut into trachea and foregut	30 days	
	Posterior neural crest dysplasia	Lymphohematogenous communication	40 days	Common in SC
	Rectal atresia with fistula	Lateral separation of distal foregut from all other gut	6 weeks	Tumor syndrome
Circulatory system	Diaphragmatic hernia	Closure of pleuroperitoneal canal	6 weeks	
	Duodenal atresia	Recanalization of duodenum	7-8 weeks	
	Malrotation of gut	Rotation of intestinal loops so that cecum lies to right	10 weeks	Associated necrotizing or jejunal mesenteric infarctions
Embryonic system	Omphalocele	Return of midgut from ventral sac to abdomen	10 weeks	
	Neckal diverticulum	Obstruction of esophageal duct	10 weeks	May contain gastric or pancreatic tissue
	Extension of bladder	Migration of urogenital mesoderm	30 days	Associated malformation and neural tube defects
Genitourinary system	Urethral obstruction sequence	Usually vesicourethral valves	9 weeks	Also common in males
	Bicruciate uterus	Fusion of lower portion of müllerian ducts	10 weeks	
Heart	Hypoplasia	Fusion of ventral folds; folds merge	12 weeks	
	Cryptorchidism	Descent of testicle into scrotum	7-9 months	
	in-transposition of great vessels	Directional development of bulbus cordis septum	34 days	
Limb	Ventricular septal defect	Closure of ventricular septum	6 weeks	
	Patent ductus arteriosus	Closure of ductus arteriosus	6-10 months	
Limb	Aphasia of radius	Growth of radial bone	38 days	Often accompanied by other defects of radial side of distal limb
	Severe syndactyly	Separation of digital rays	6 weeks	

### How are agents determined to be teratogenic ?

- Anecdotal data in humans
- Data from animal studies
- For many drugs there are no definitive data, so we recommend avoiding the use of any medications possible during early pregnancy

### Effect of Exposure Depends on Timing

- All or none effect early
- Effect of organogenesis during embryonic development
- Effect on size and function during fetal development

Teratogens	Congenital Malformations
Androgenic Agents Ethinisterone Norethisterone Testosterone	Varying degrees of masculinization of female fetuses; ambiguous external genitalia caused by labial fusion and clitoral hypertrophy.
Drugs and Chemicals Alcohol	<i>Fetal alcohol syndrome</i> : intrauterine growth retardation (IUGR); mental retardation; microcephaly; ocular anomalies; joint abnormalities; short palpebral fissures.
Aminopterin	Wide range of skeletal defects; IUGR; malformations of the central nervous system, notably meroencephaly (a large part of the brain is absent).
Busulfan	Stunted growth; skeletal abnormalities; corneal opacities; cleft palate; hypoplasia of various organs.
Phenytoin (Dilantin)	<i>Fetal hydantoin syndrome</i> : IUGR, microcephaly; mental retardation; ridged metopic suture; inner epicanthal folds; eyelid ptosis; broad depressed nasal bridge; phalangial hypoplasia.
Lithium carbonate Methotrexate	Various malformations, usually involving the heart and great vessels. Multiple malformations, especially skeletal, involving the face, skull, limbs, and vertebral column.
Large doses of retinoic acid (Vitamin A)	Facial abnormalities; neural tube defects, such as spina bifida cystica (see Fig. 18-14).
Tetracycline	Stained teeth; hypoplasia of enamel.
Trimethadione	Developmental delay; V-shaped eyebrows; low-set ears; cleft lip and/or palate.
Infectious Agents Cytomegalovirus	Microcephaly; hydrocephaly; microphthalmia; microgyria; mental retardation; cerebral calcifications.
Herpes simplex virus	Microcephaly; microphthalmia; retinal dysplasia.
Rubella virus	Cataracts; glaucoma; chorioretinitis; deafness; microphthalmia; congenital heart defects.
Variella	Skin scarring; muscle atrophy; mental retardation.
Venezuelan equine encephalitis	Cataracts; brain destruction.
<i>Toxoplasma gondii</i>	Microcephaly; mental retardation microphthalmia; hydrocephaly; chorioretinitis; cerebral calcifications.
<i>Treponema pallidum</i>	Hydrocephalus; congenital deafness; mental retardation; abnormal teeth and bones.
High levels of ionizing radiation	Microcephaly; mental retardation; skeletal malformations.

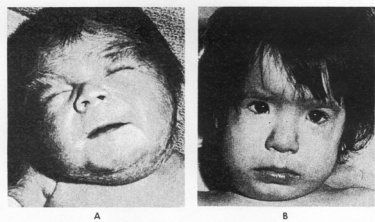
### Nicotine

- IUGR
- Premature delivery
- Neurocognitive development

### Fetal Alcohol Syndrome

- Characteristic facial features
- Congenital heart disease
- Growth deficiency
- Behavioral/neurocognitive deficits

### Fetal Alcohol Syndrome



### Mrs. B

- Do you believe her fetus' congenital heart disease was caused by the glass of wine she drank two weeks after conception?

### Tetracycline

- Yellow/brown teeth
- Decreased bone growth

### Fetal Hydantoin Syndrome

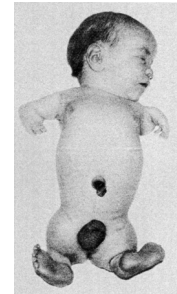
- Caused by the anti-epileptic phenytoin
- Intrauterine growth retardation
- Microcephaly, mental retardation
- Distal phalangeal hypoplasia
- Specific facial features

### Retinoic acid

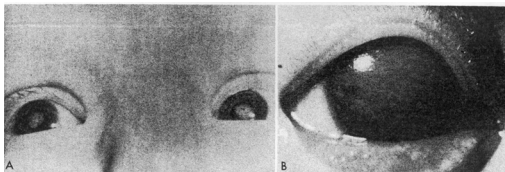
- Extremely teratogenic in the first five weeks of gestation
- Craniofacial dysmorphisms
- Cleft palate
- Thymic aplasia
- Neural tube defects

### Thalidomide Syndrome

- Critical exposure is 24-36 days of gestation
- Limbs
- Ears
- Cardiac
- GU anomalies



### Congenital Rubella (German measles)



Cataracts, congenital heart disease, deafness  
Effects are most severe within the first 6 weeks

### Congenital CMV

- Most common infection
- Spontaneous termination
- Intrauterine growth retardation
- Micromelia
- Chorioretinitis, blindness
- Microcephaly
- Cerebral calcifications, mental retardation
- Hepatosplenomegaly

### Ionizing Radiation

- Affects brain development at 10-18 weeks of gestation at HIGH dose
- No evidence of effect of exposure associated with typical diagnostic studies

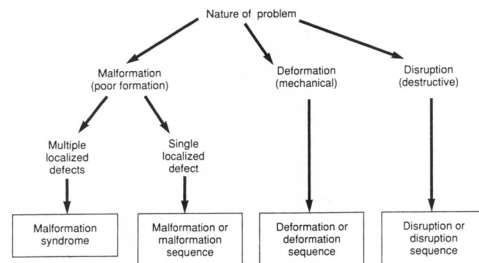
### Maternal Hyperglycemia

- Congenital heart disease
- Renal, gastrointestinal, and central nervous system malformations such as neural tube defects
- Tight glycemic control starting prior to conception is critical

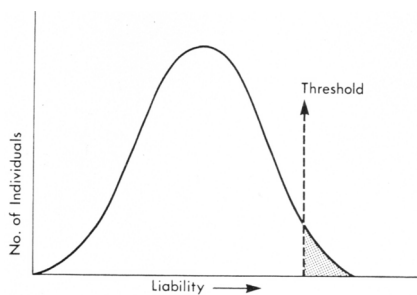
### Babies of Mothers with PKU

- Mental retardation
- Low birth weight
- Congenital heart disease

### Mechanical forces can act as teratogens



### Threshold Effect-Multifactorial



Examples: cleft lip, cleft palate, congenital heart disease, neural tube defects

### Mrs. B

- After birth, the newborn examination is unremarkable
- The baby's congenital heart disease is repaired
- At age three, the child is growing well and has met all his milestones
- What caused his congenital heart disease?
- What is the risk of recurrence for a future sibling?