


# UROGENITAL TRACT

# Female Development

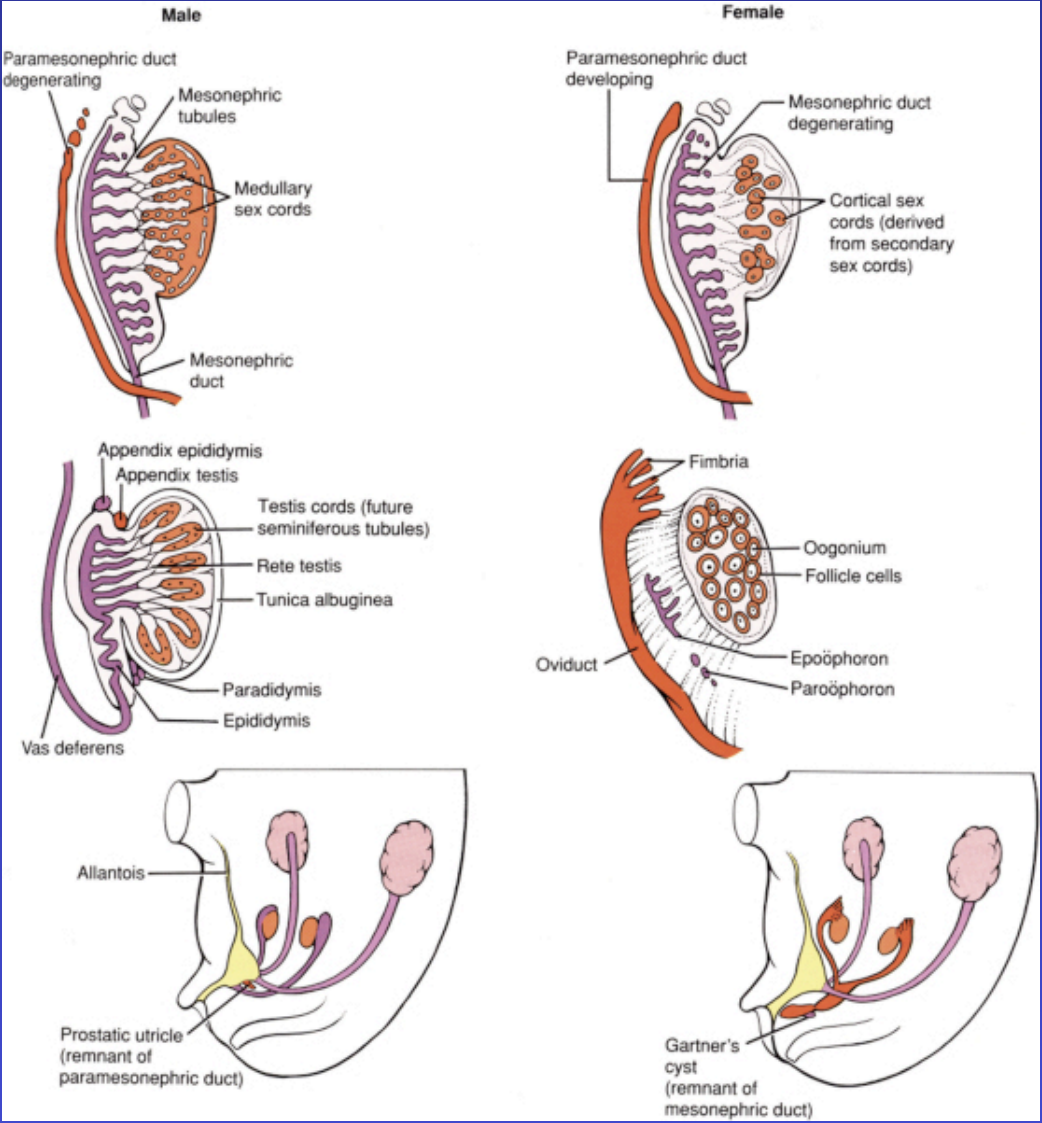
RICHARD SCHLUSSEL, M.D.

DEPARTMENT OF UROLOGY

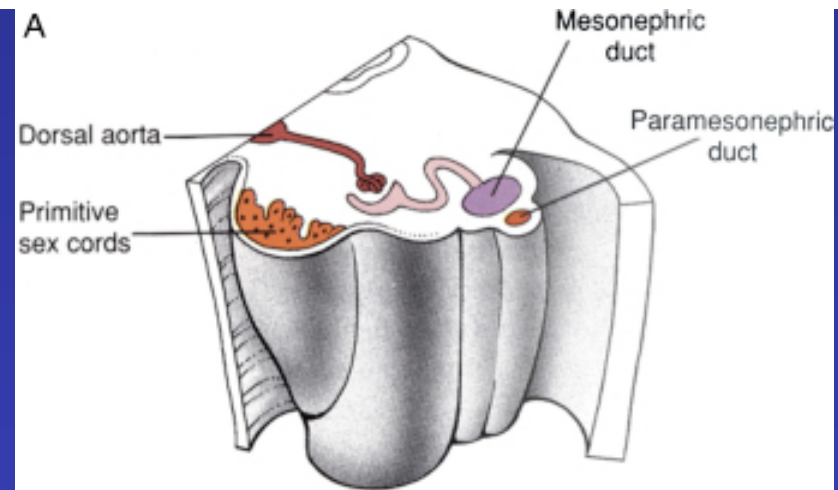
DIVISION OF PEDIATRIC UROLOGY



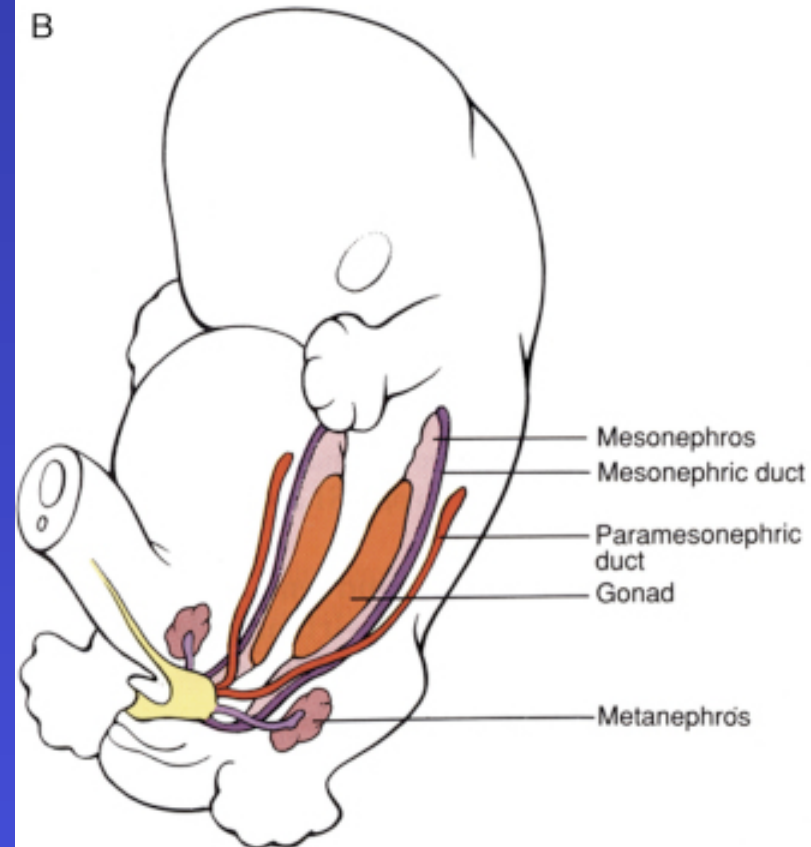
- **Normal development**
- **Duplication**
- **Agenesis**
- **UG Sinus**
- **Imperforate hymen**
- **CAH**



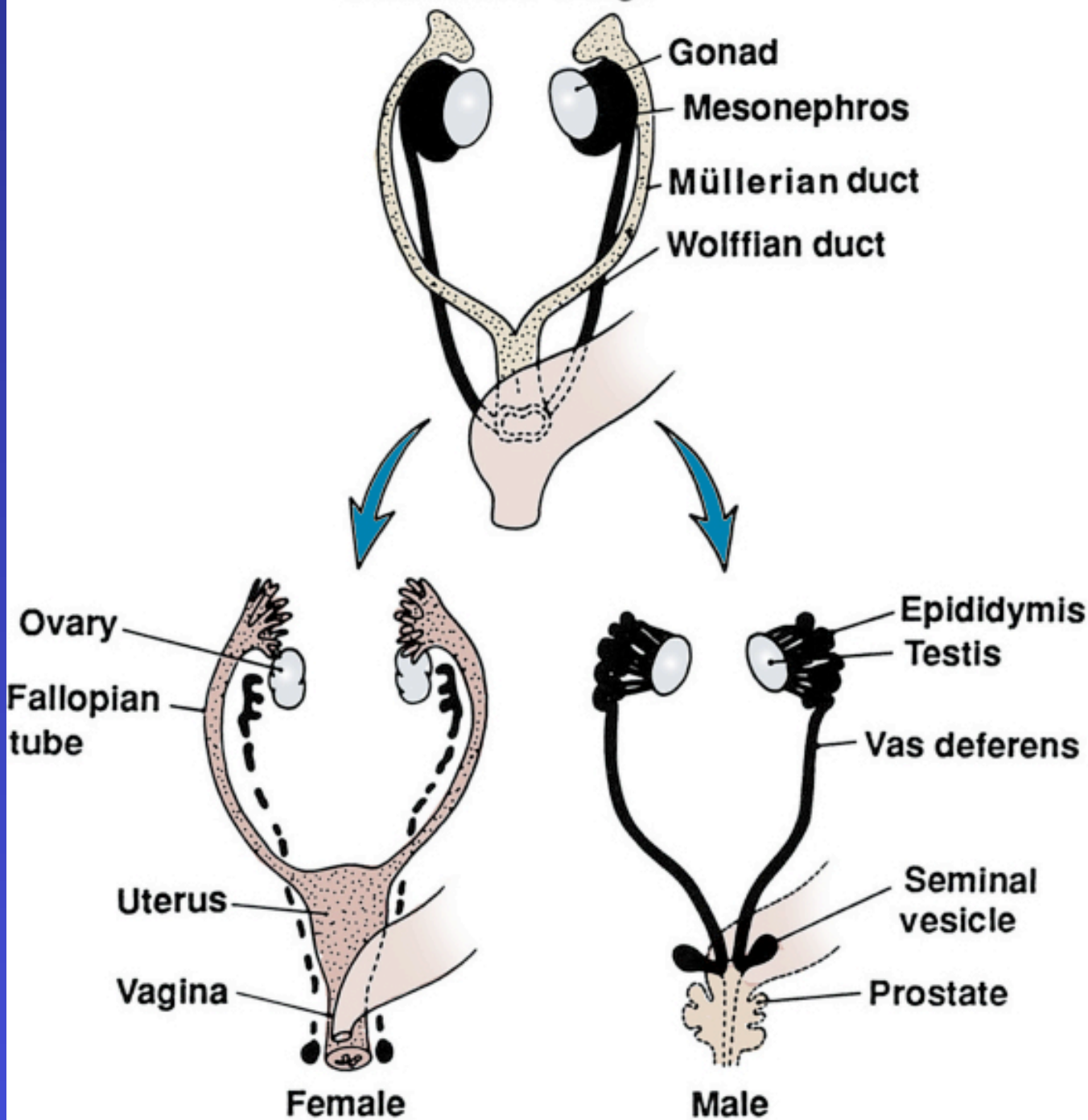
A

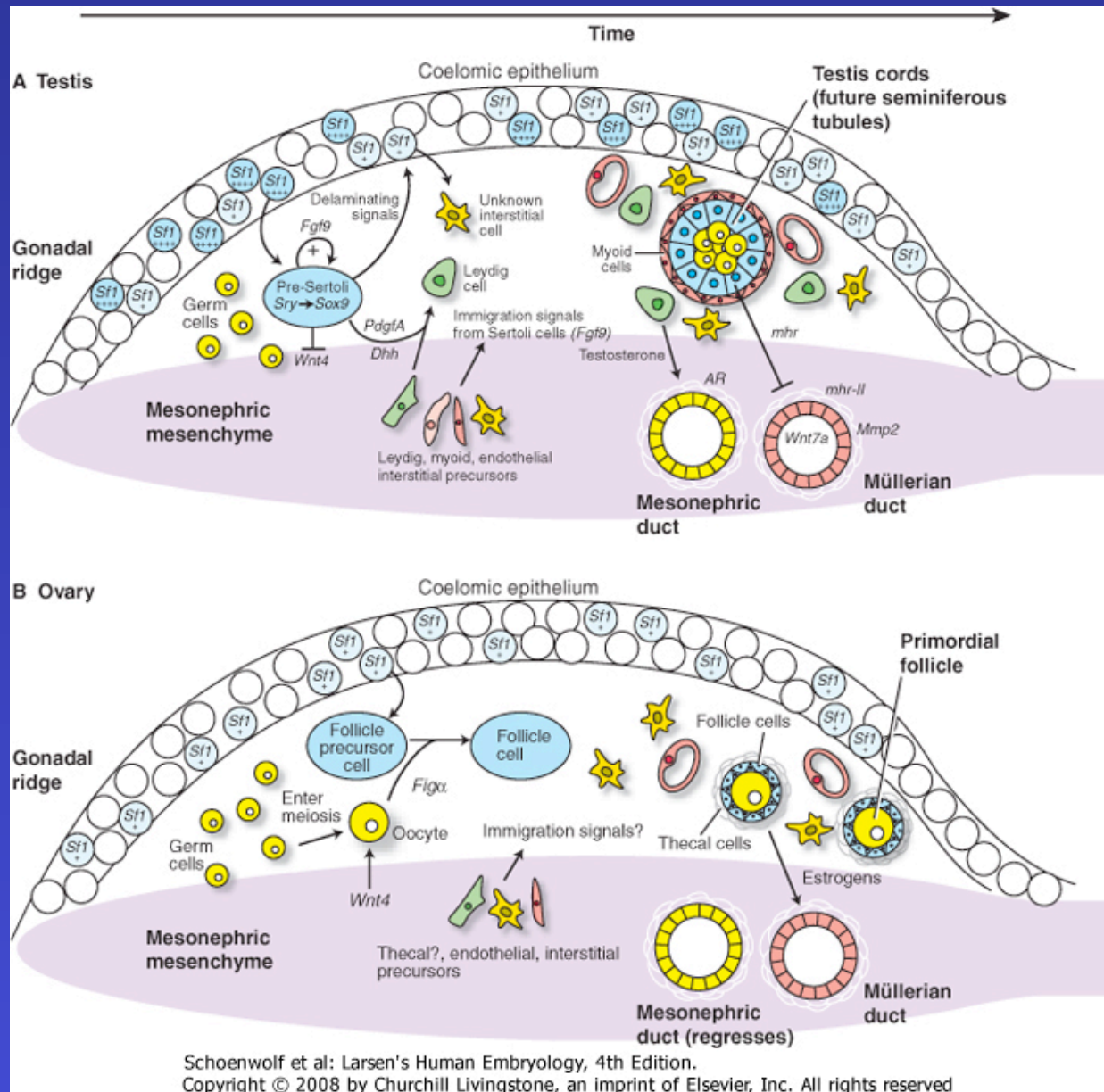


B

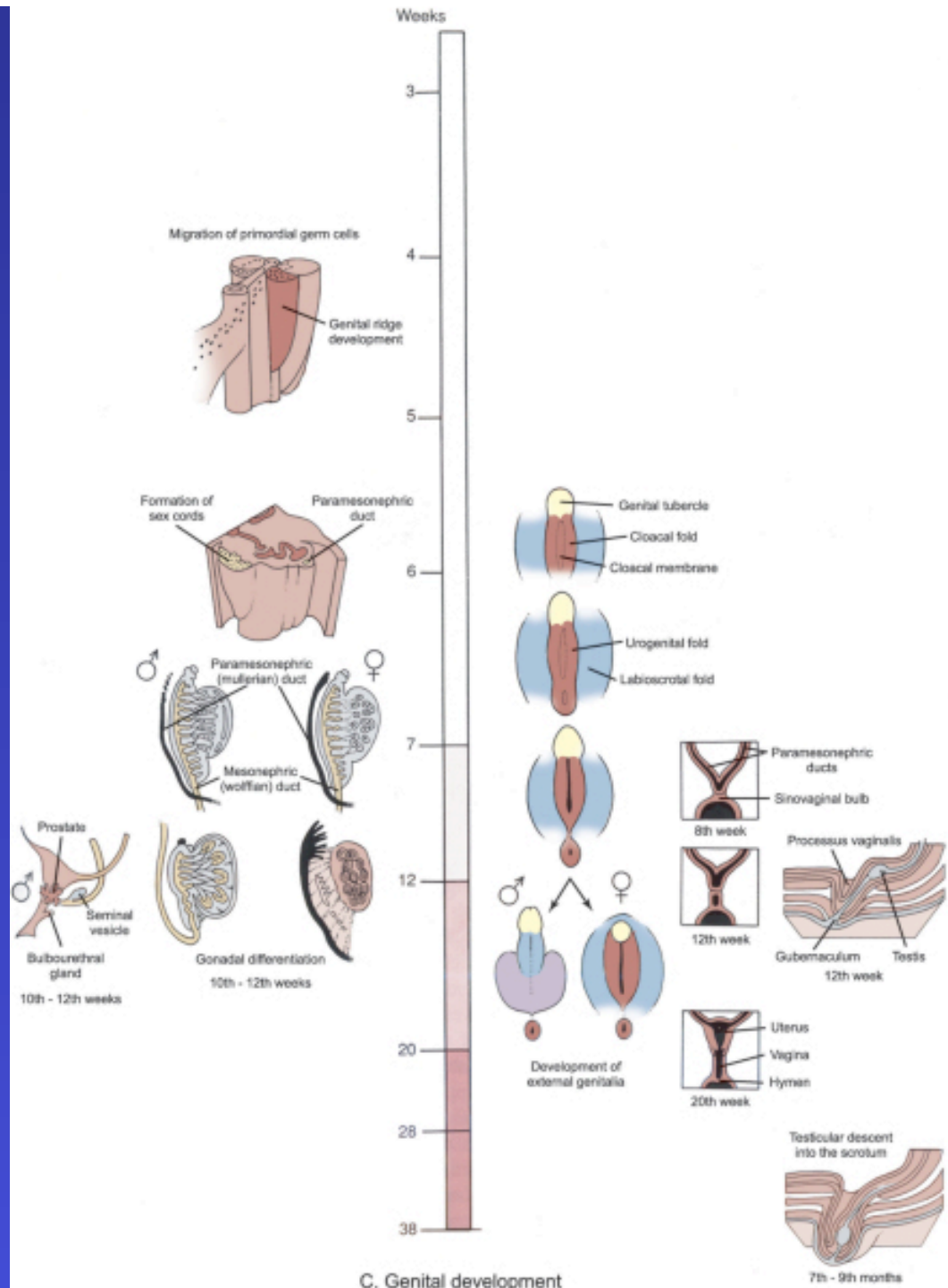


**Indifferent stage**



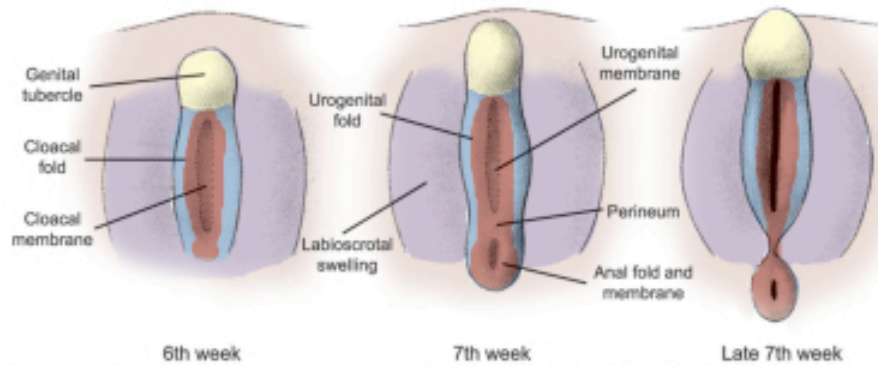


Schoenwolf et al: Larsen's Human Embryology, 4th Edition.  
 Copyright © 2008 by Churchill Livingstone, an imprint of Elsevier, Inc. All rights reserved

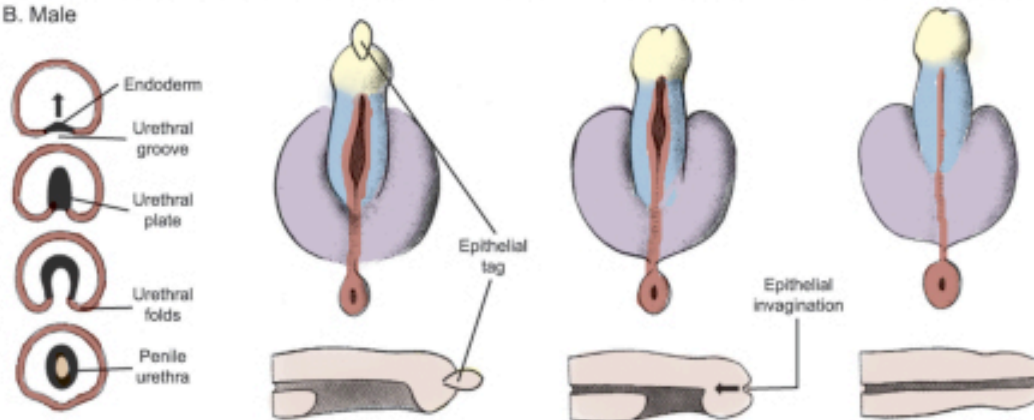


C. Genital development

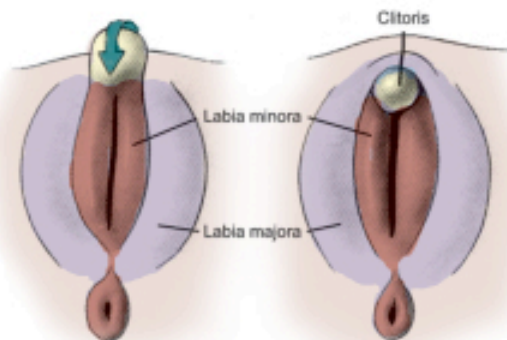
A. Indifferent stage



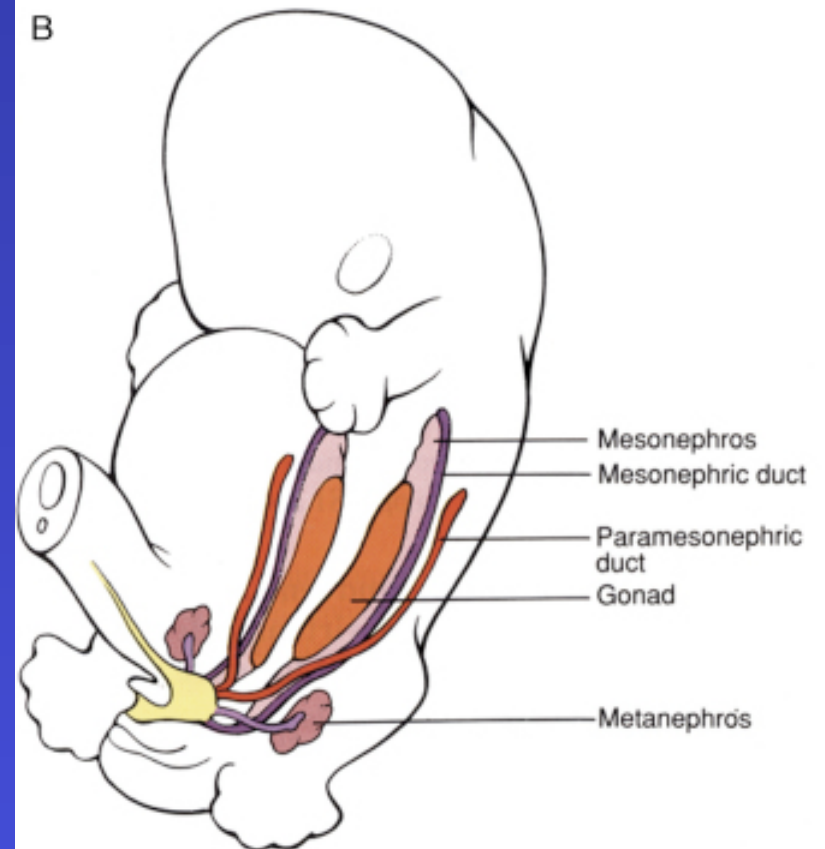
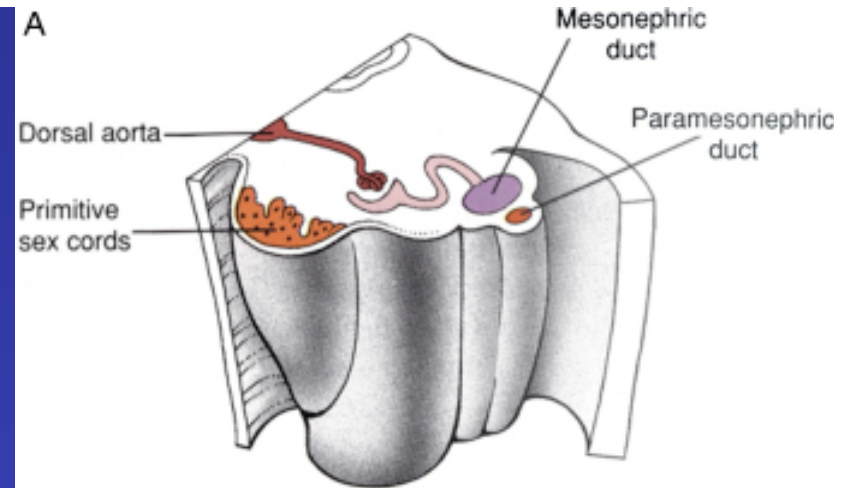
B. Male

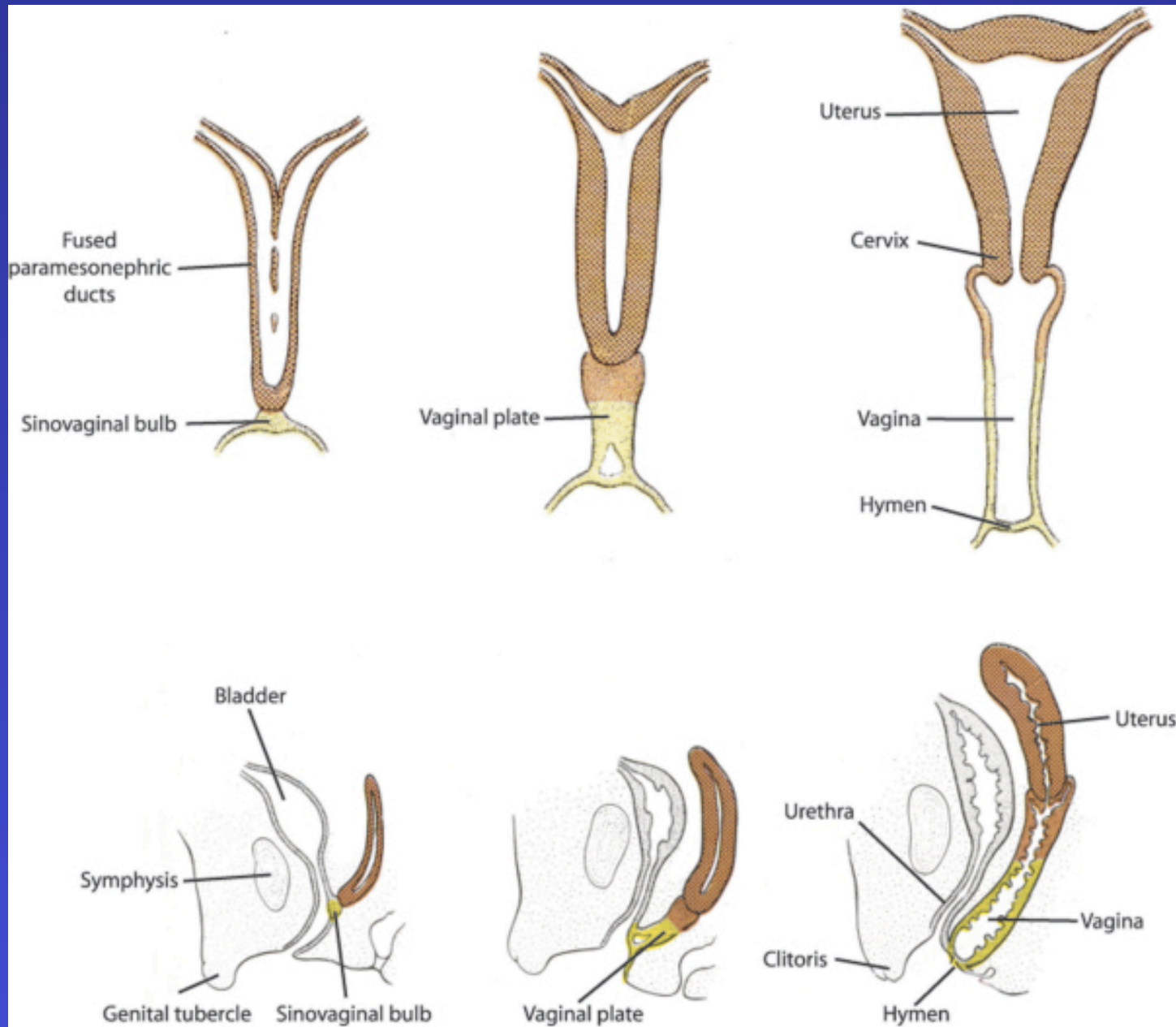


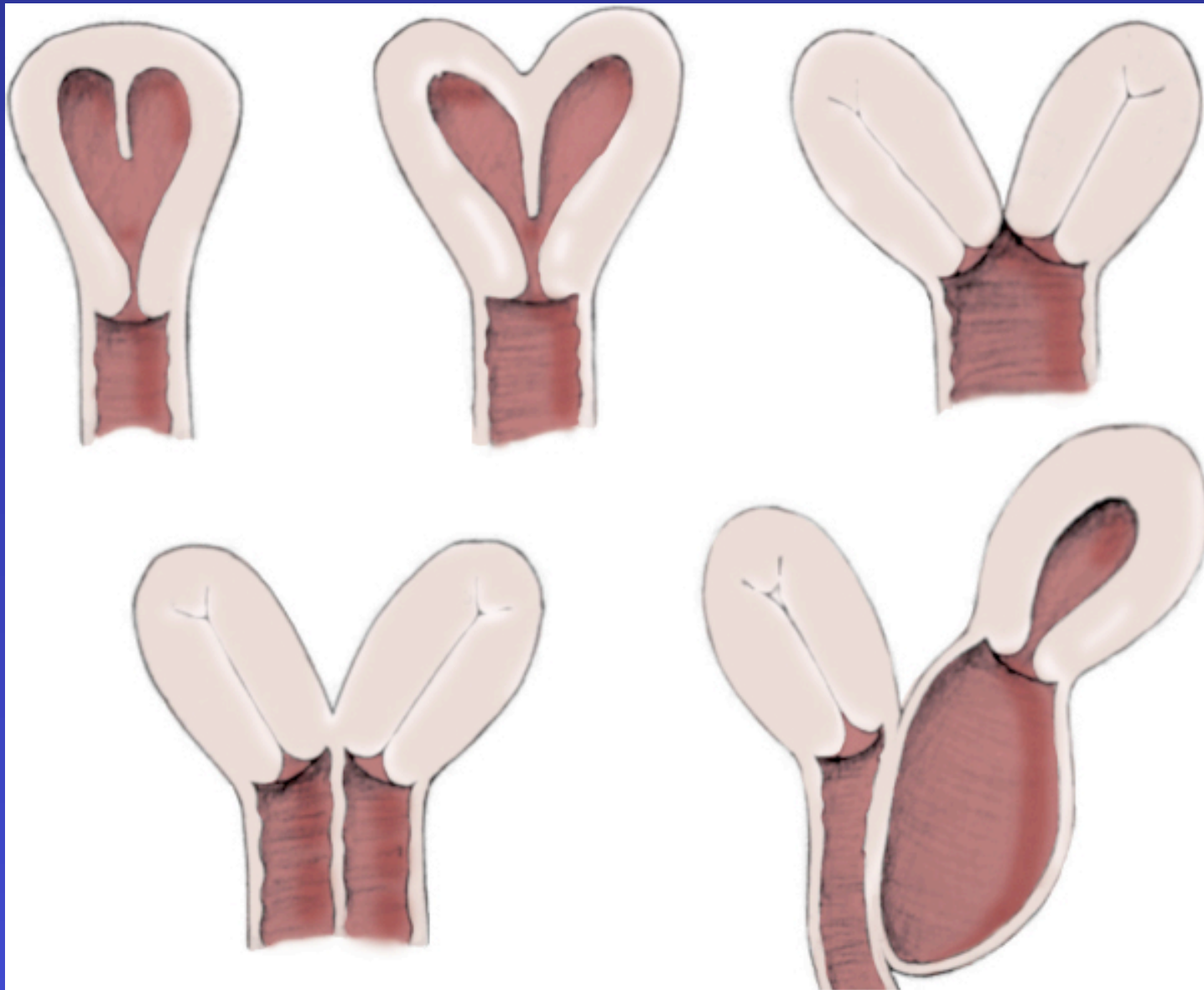
C. Female



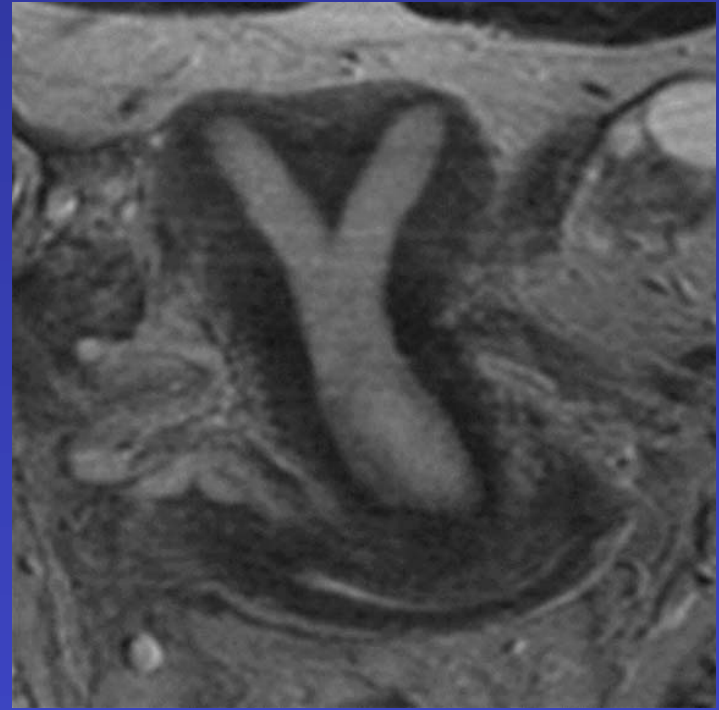
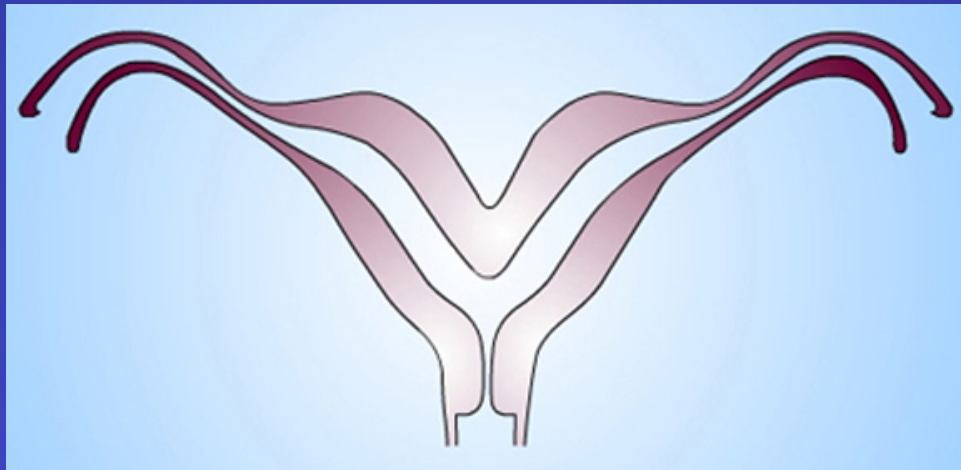
- **Paramesonephric duct**
  - A.K.A. **Mullerian Duct**
  - **Becomes future**
    - **Fallopian tubes**
    - **Uterus**
    - **Upper 2/3 vagina**



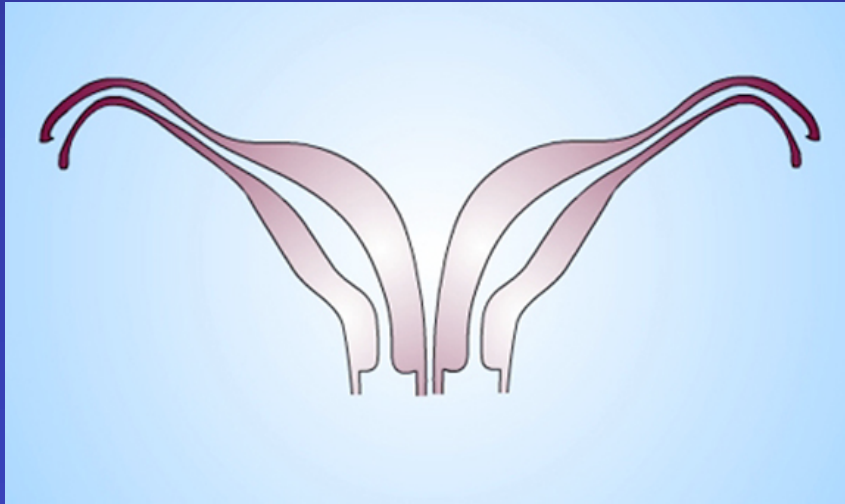




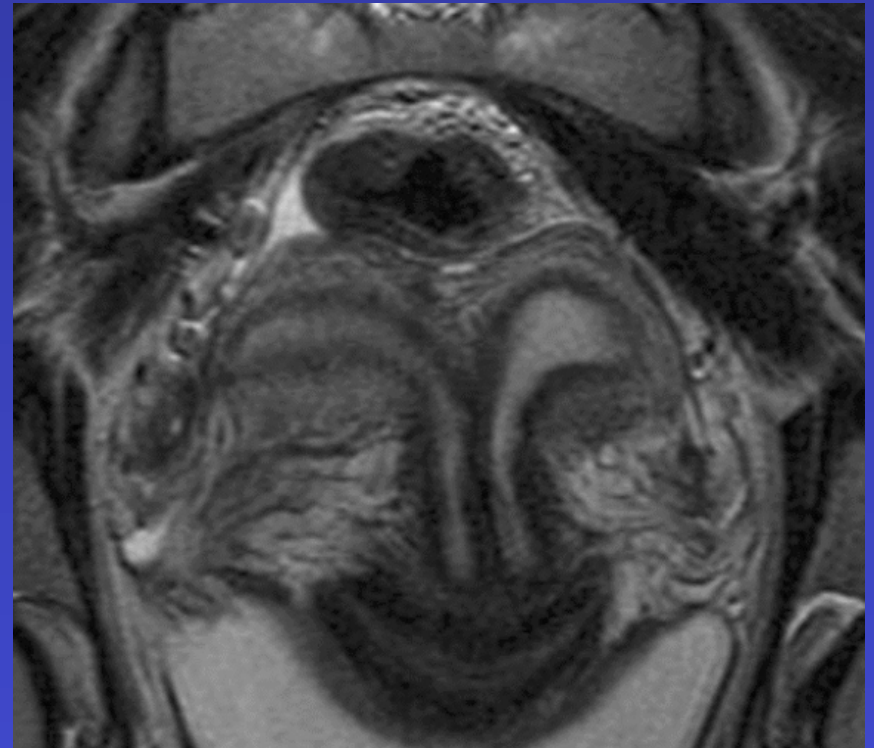
**VAGINAL AND UTERINE  
DUPLICATION**

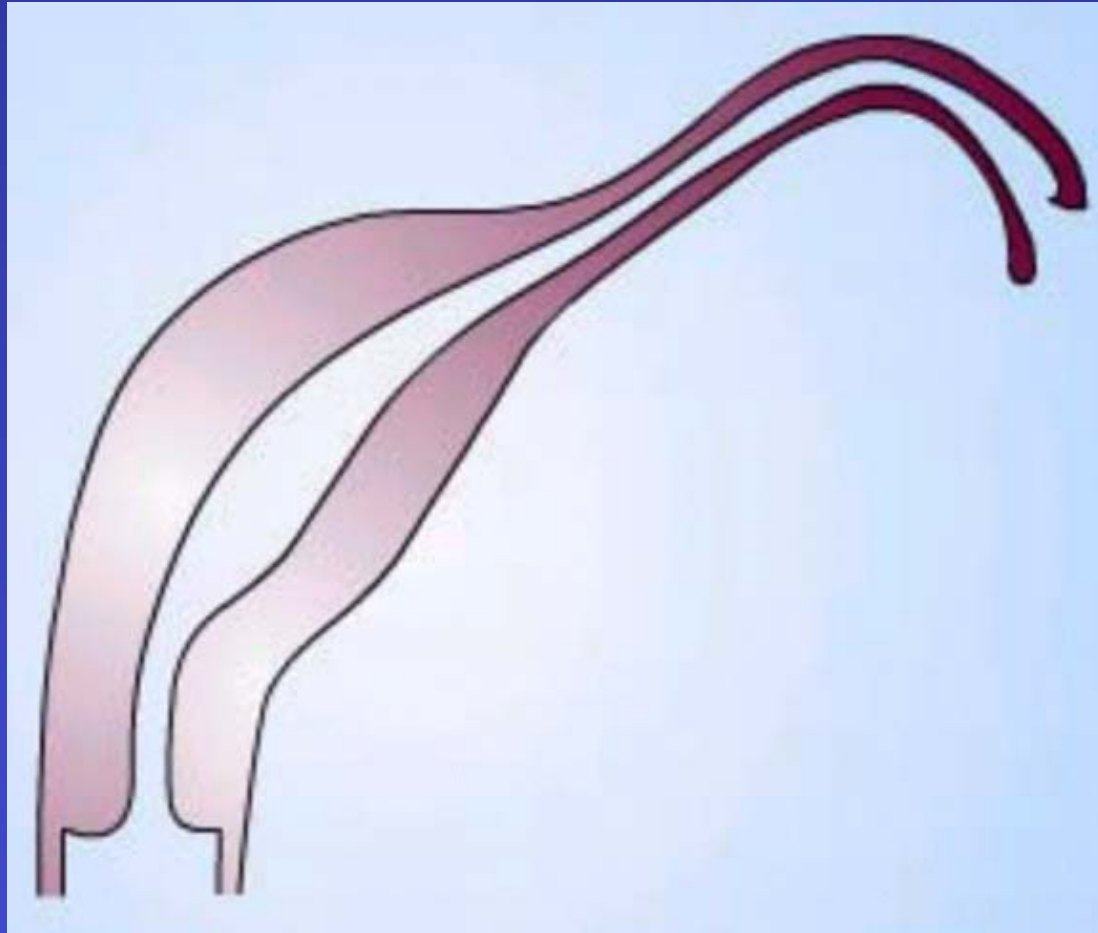


**Bicornuate Uterus**

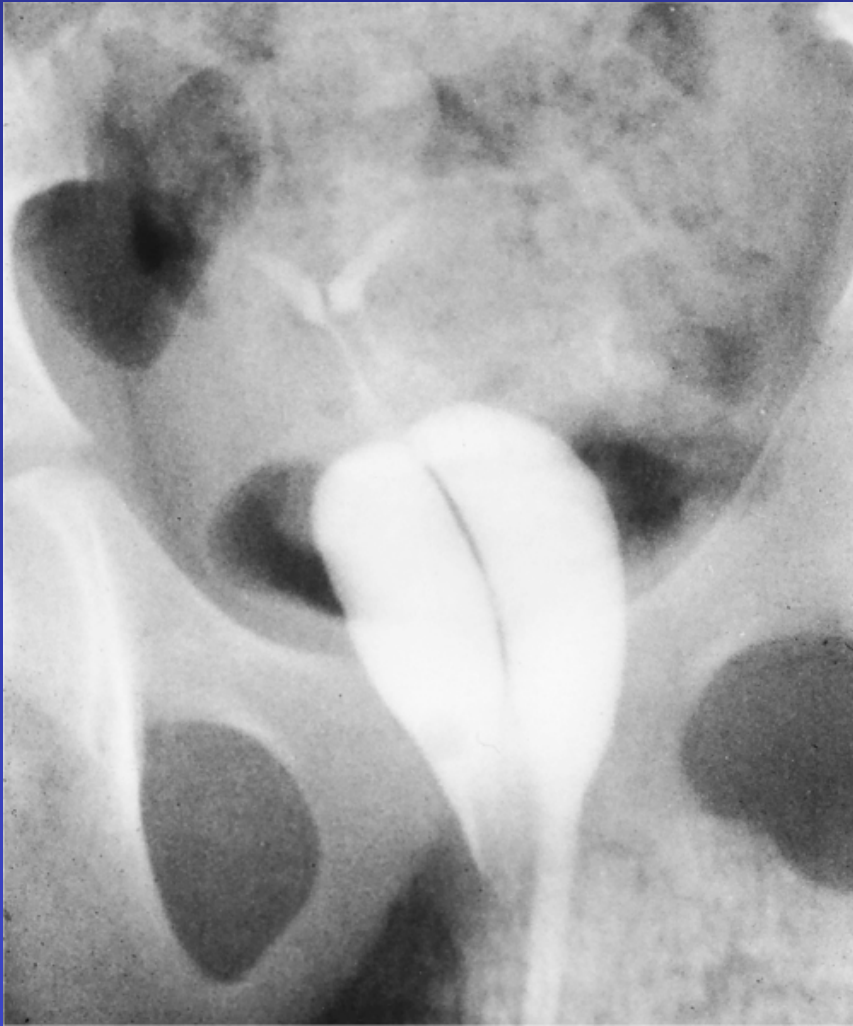

**Didelphys uterus**



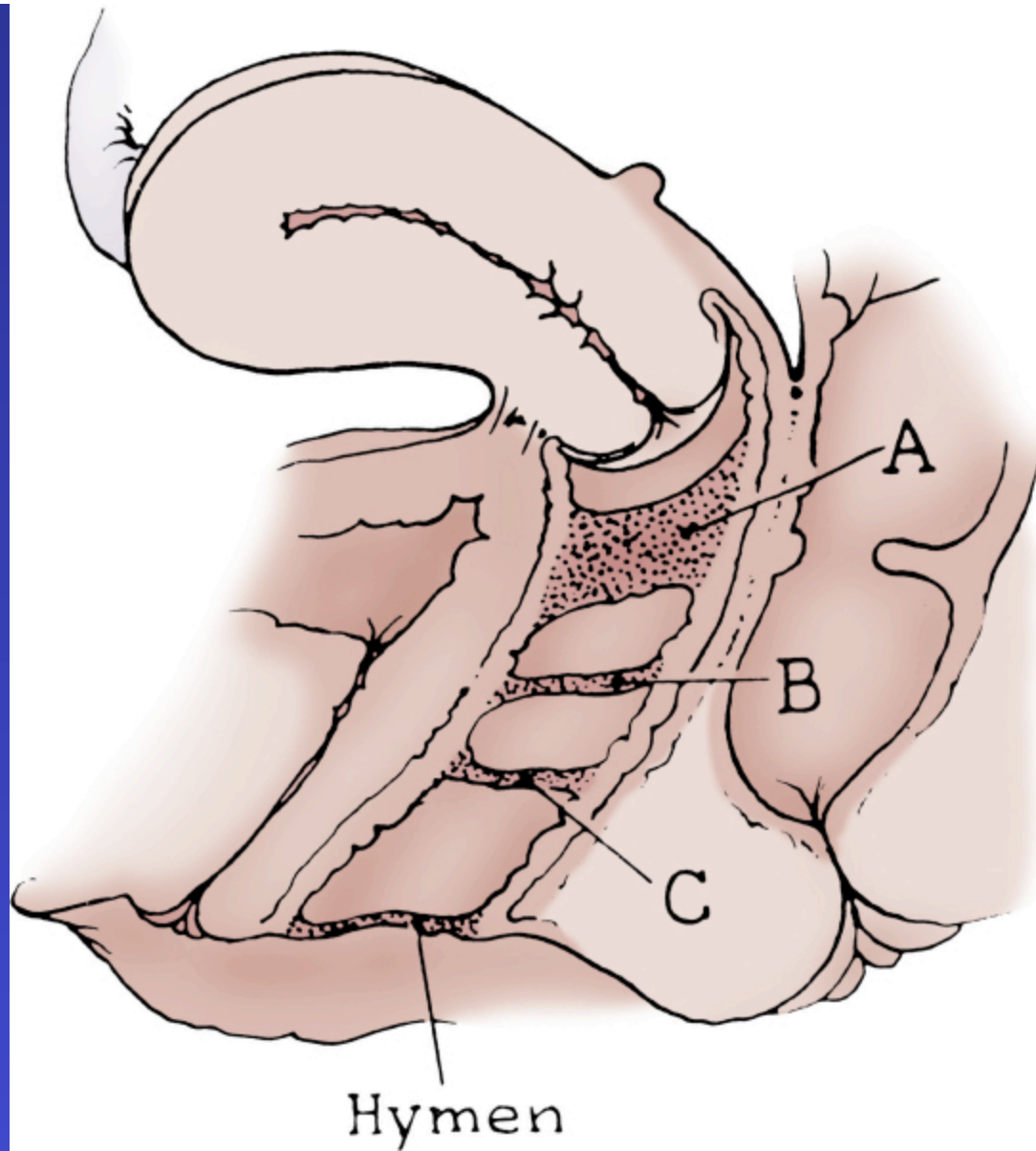


**Unicornuate Uterus**



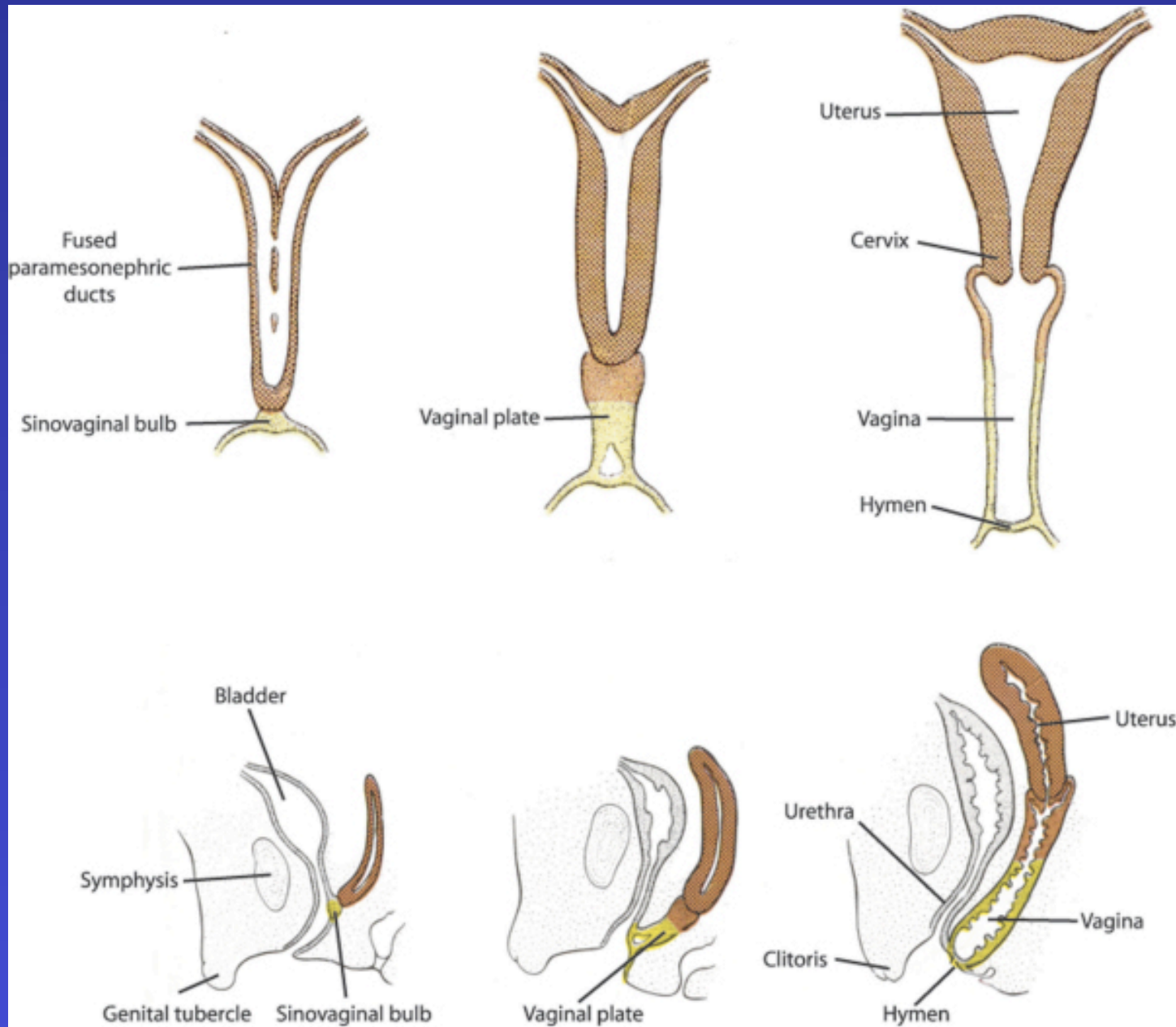
- **Symptom**
  - **Blood persists despite tampon during menses**

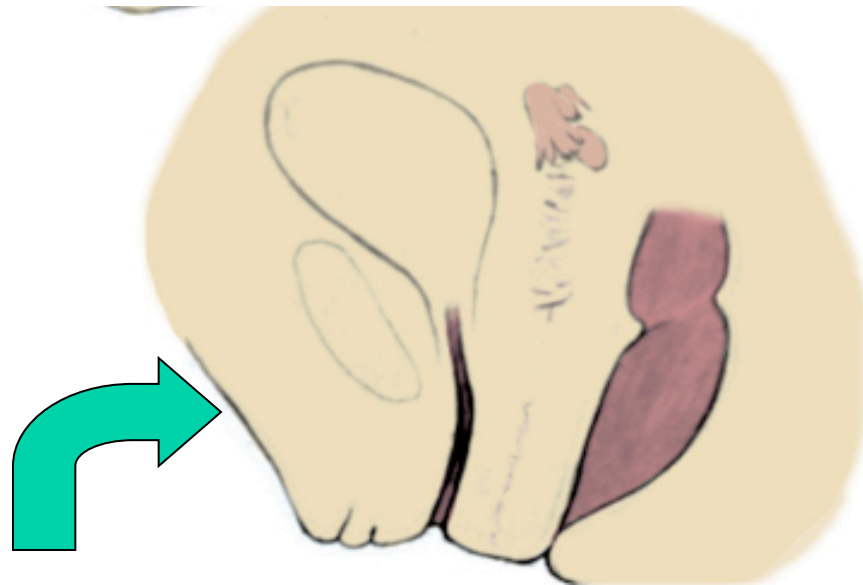
**Complete Vaginal Duplication**



## Symptom

- Upper vagina fills with blood during menses

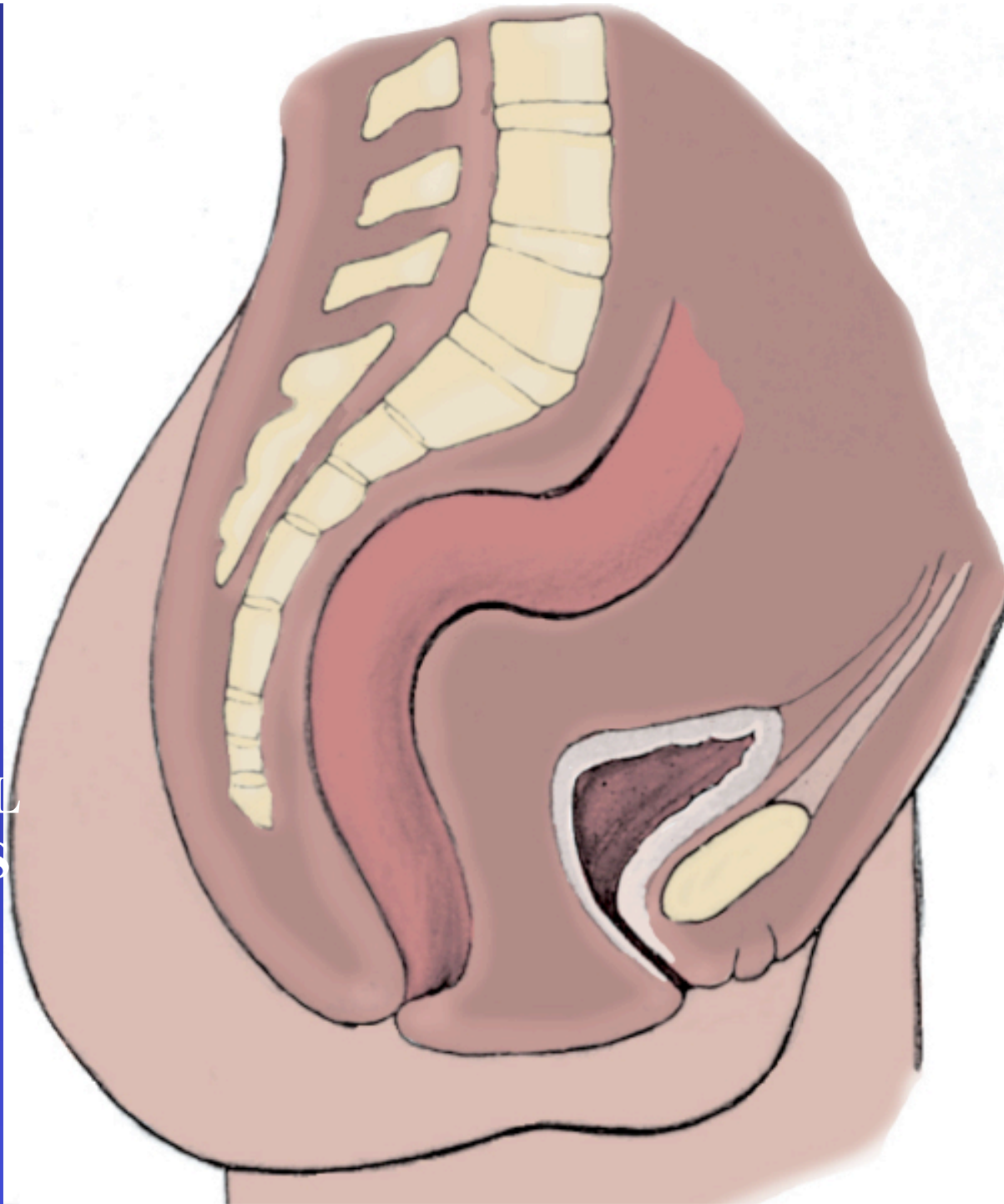


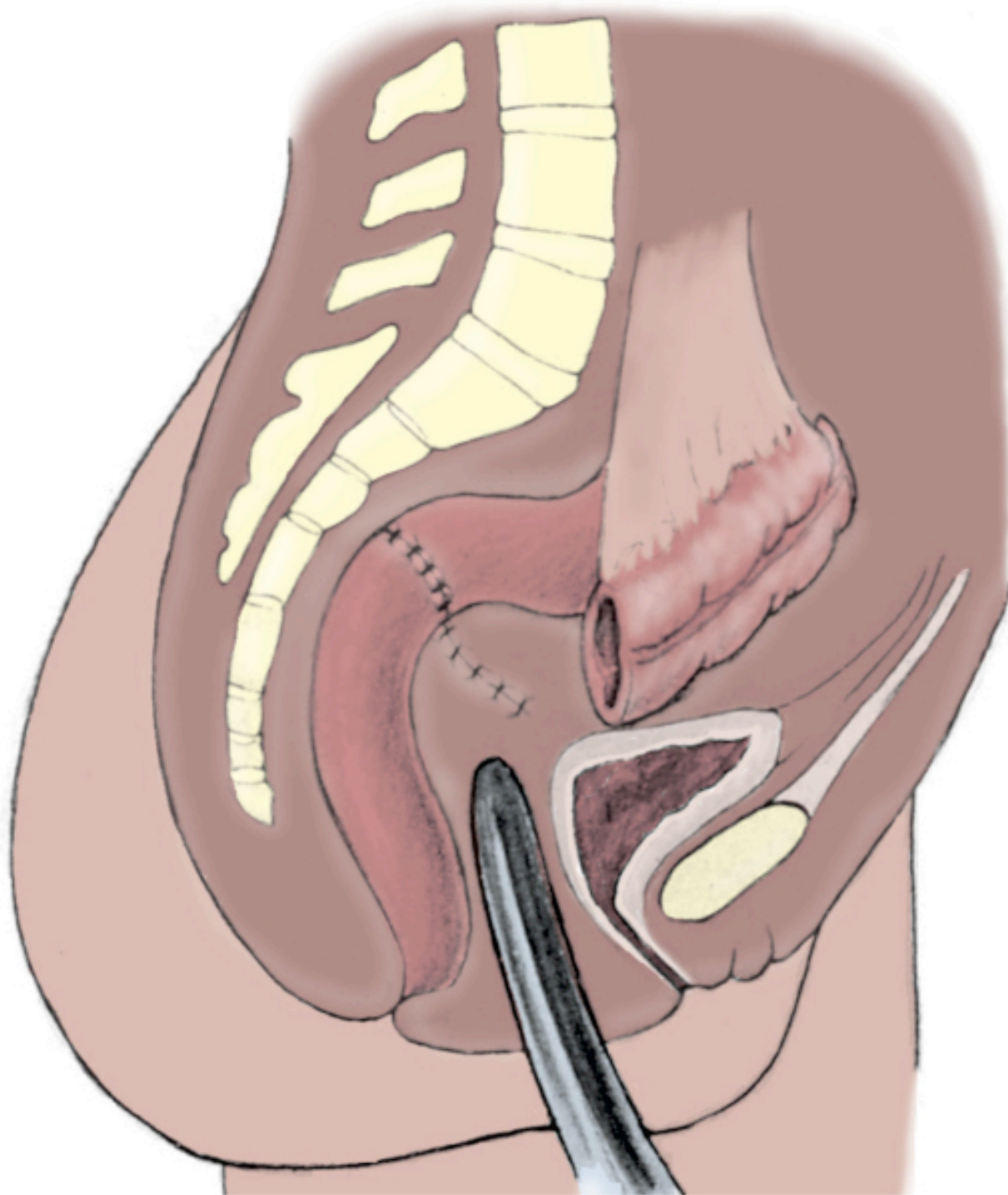


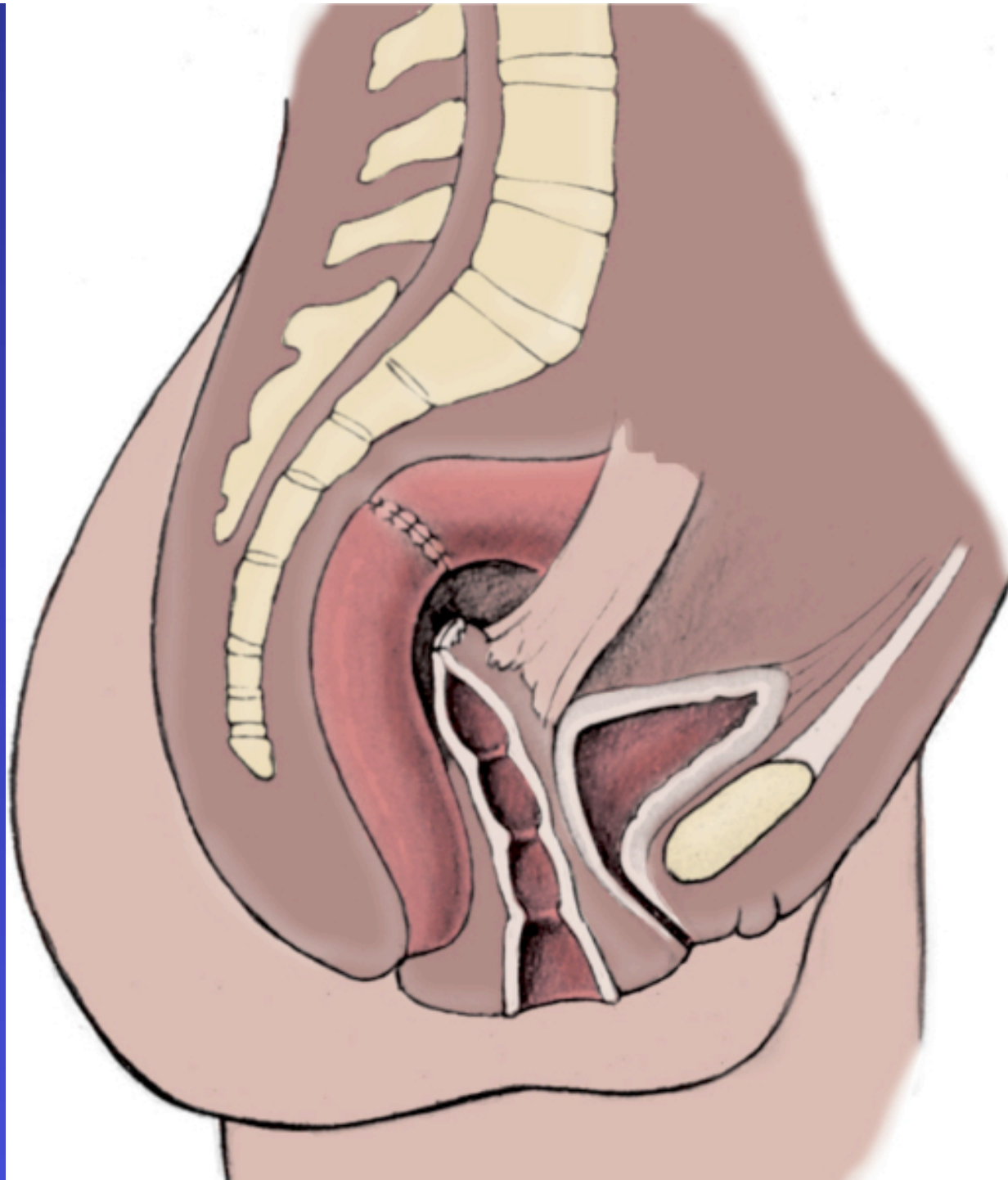
**Mayer-Rokitansky-Küster-Hauser Syndrome**

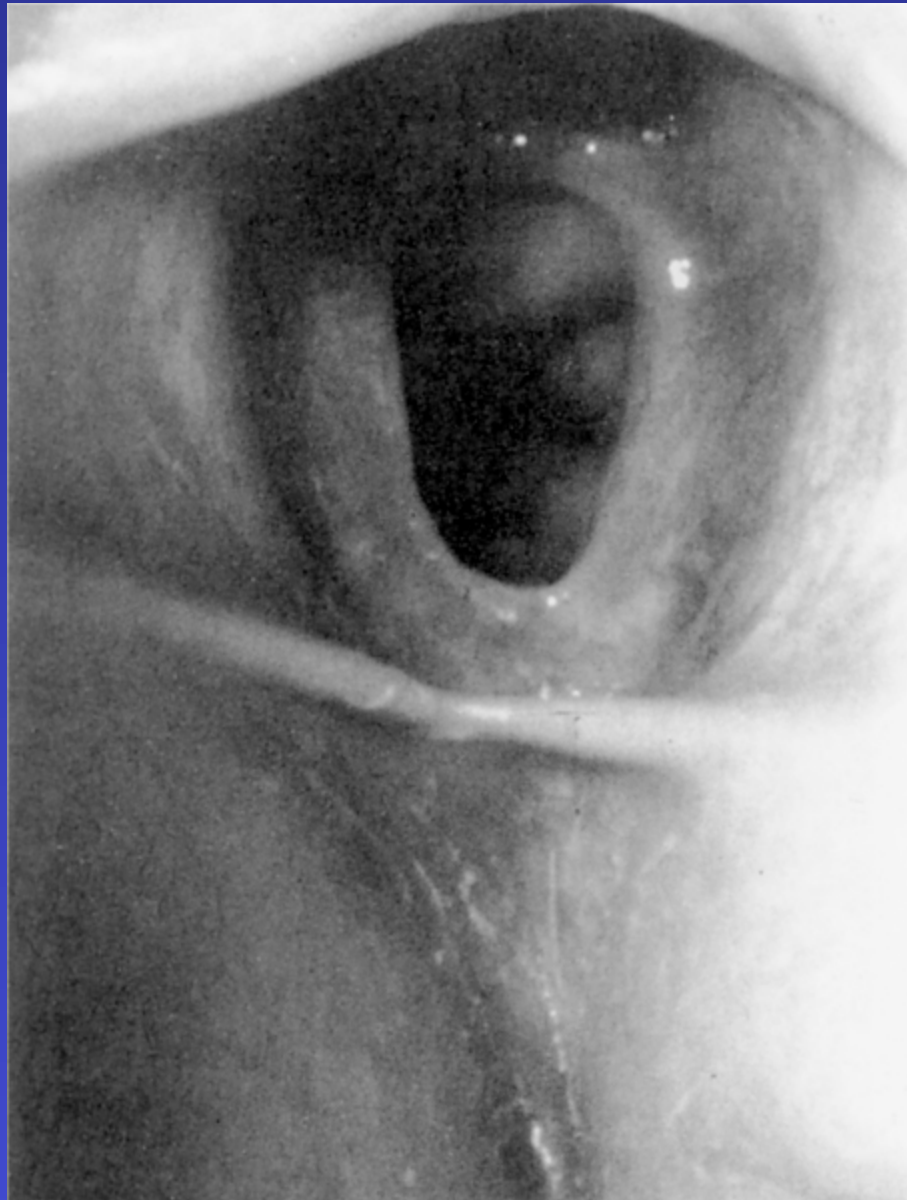**1 in 5,000  
births**

VAGINAL  
AGENSIS

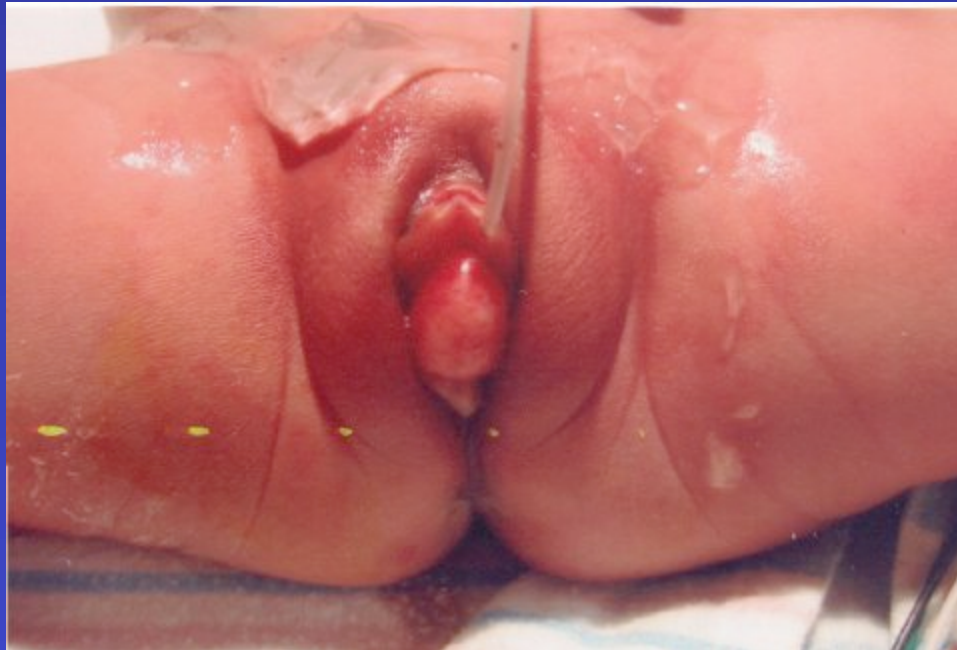





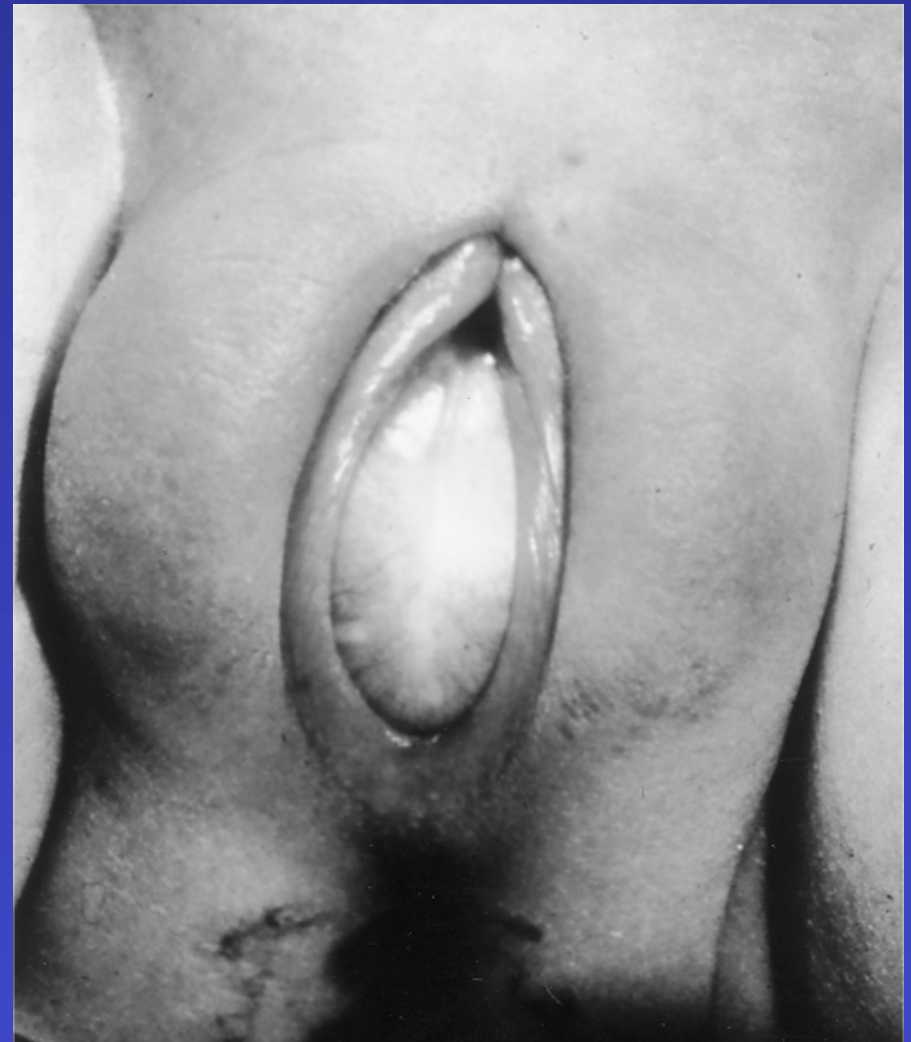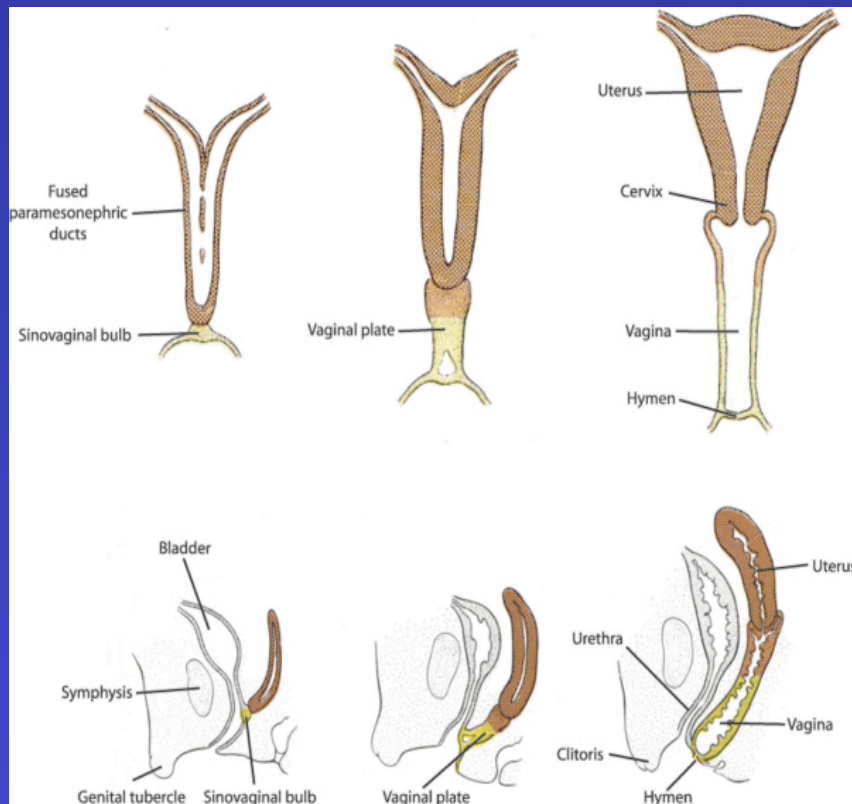


**Normal Hymenal Ring**

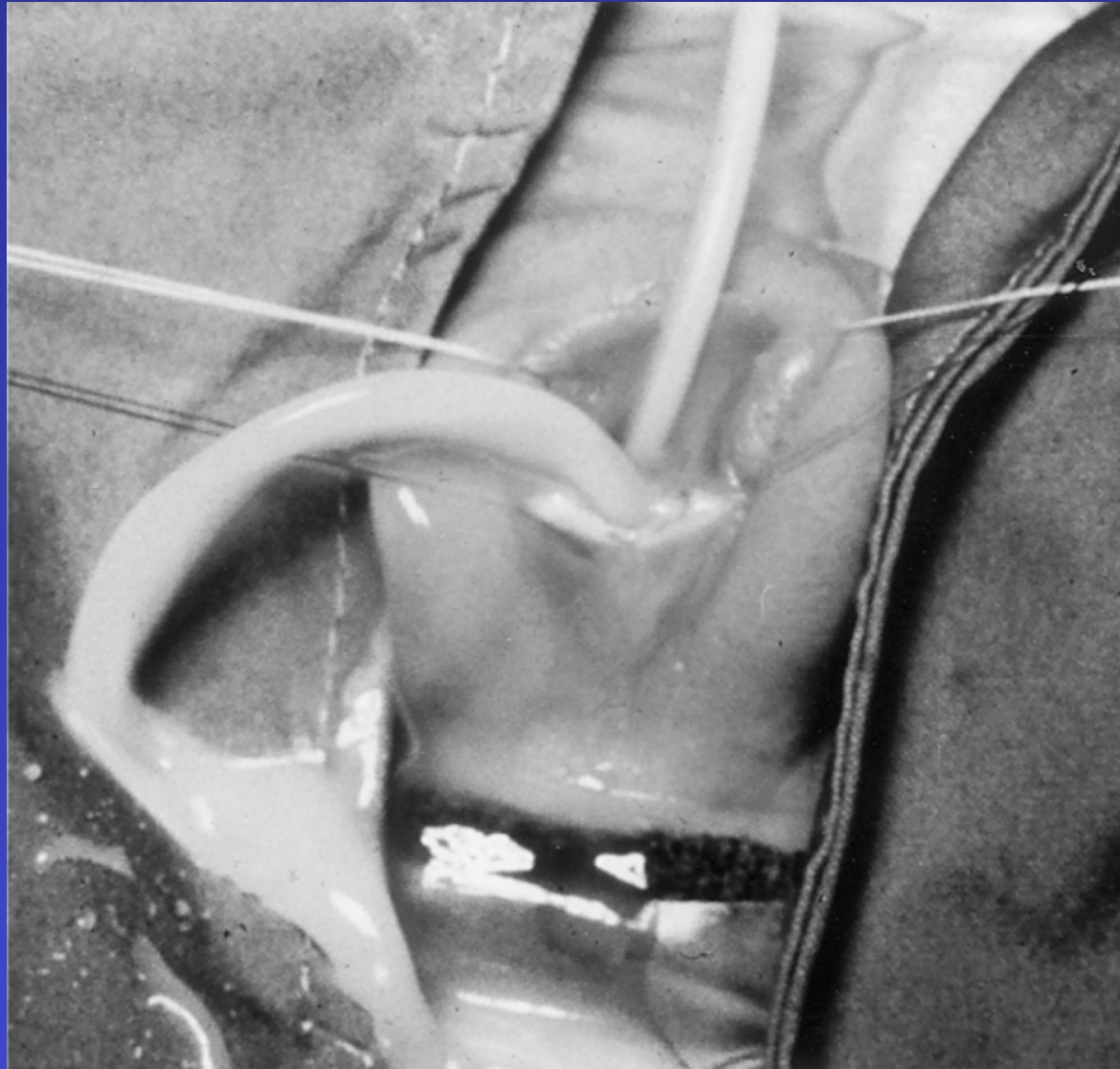

**Imperforate hymen**

# Imperforate hymen



**Mucous due to maternal hormones**

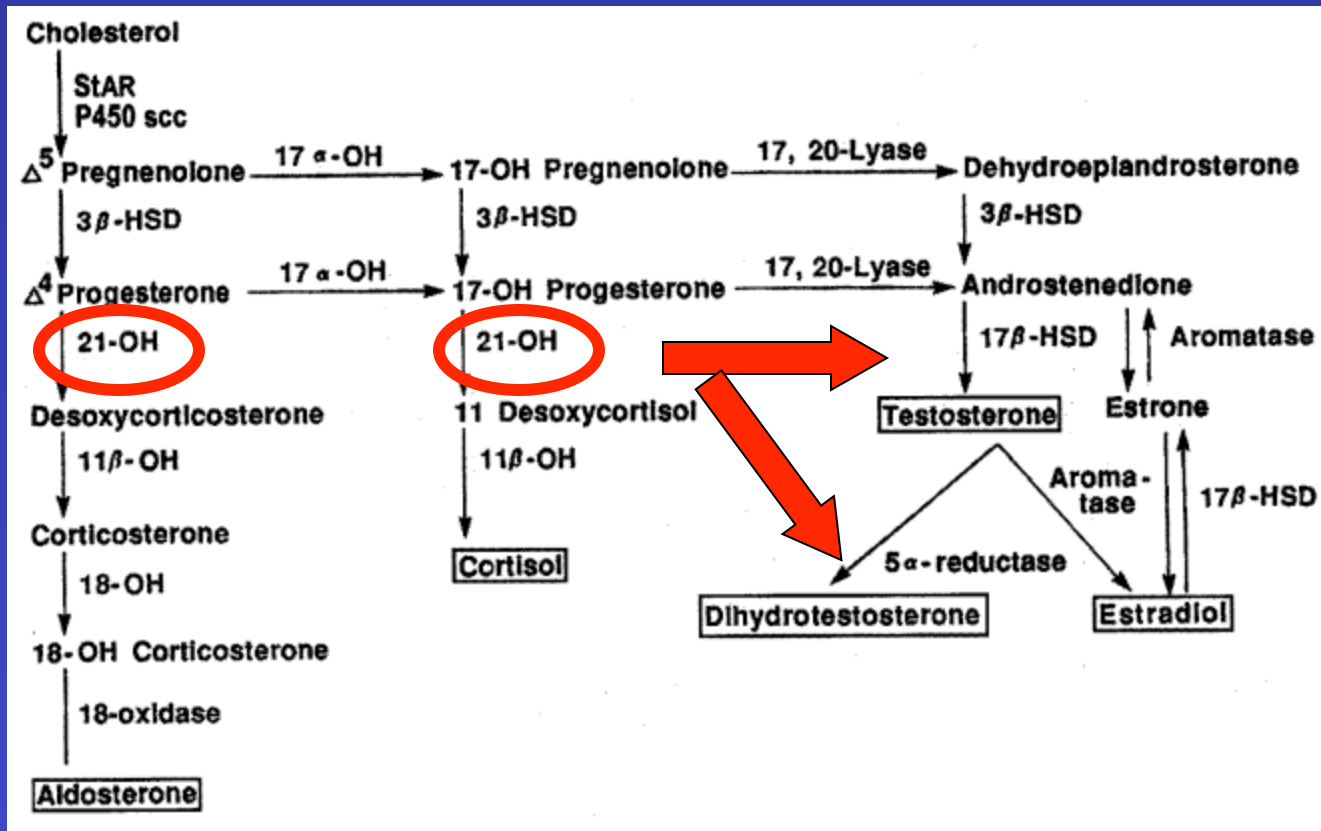


**Intra-op drainage of imperf hymen**

# Ambiguous Genitalia

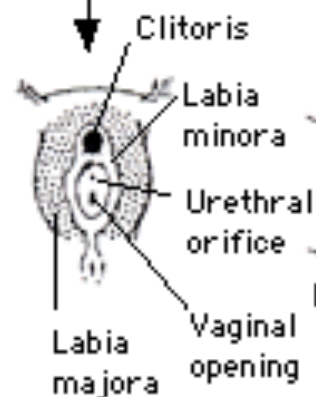
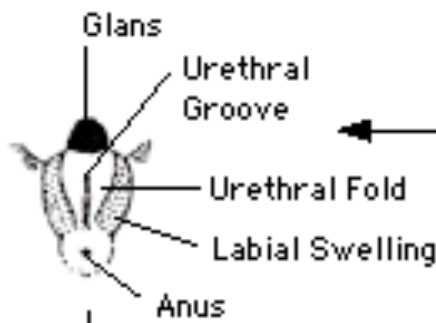
- **Female Pseudohermaphrodite**
  - **Congenital Adrenal Hyperplasia (CAH)**
    - **46 XX**
    - **Normal ovaries, uterus and upper vagina**
    - **Virilized external genitalia**
      - **Due to in utero exposure to testosterone**
    - **Most common cause of intersex**
  - **Normal potential for sexual and reproductive function as females**

# Ambiguous Genitalia

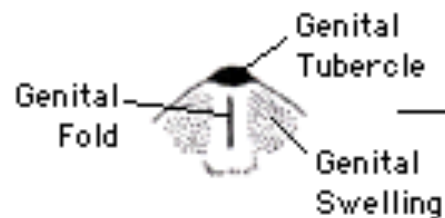


Congenital Adrenal Hyperplasia

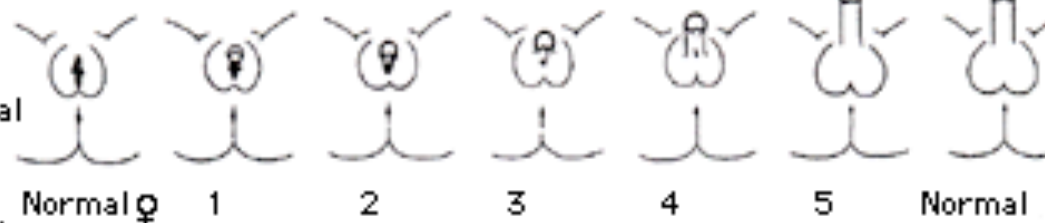
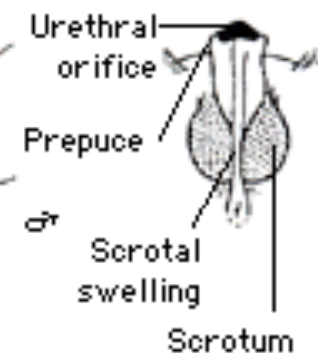
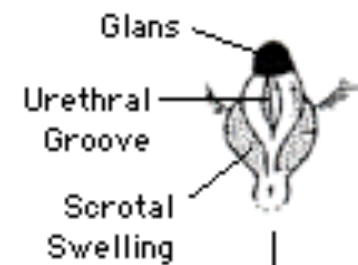
### Female



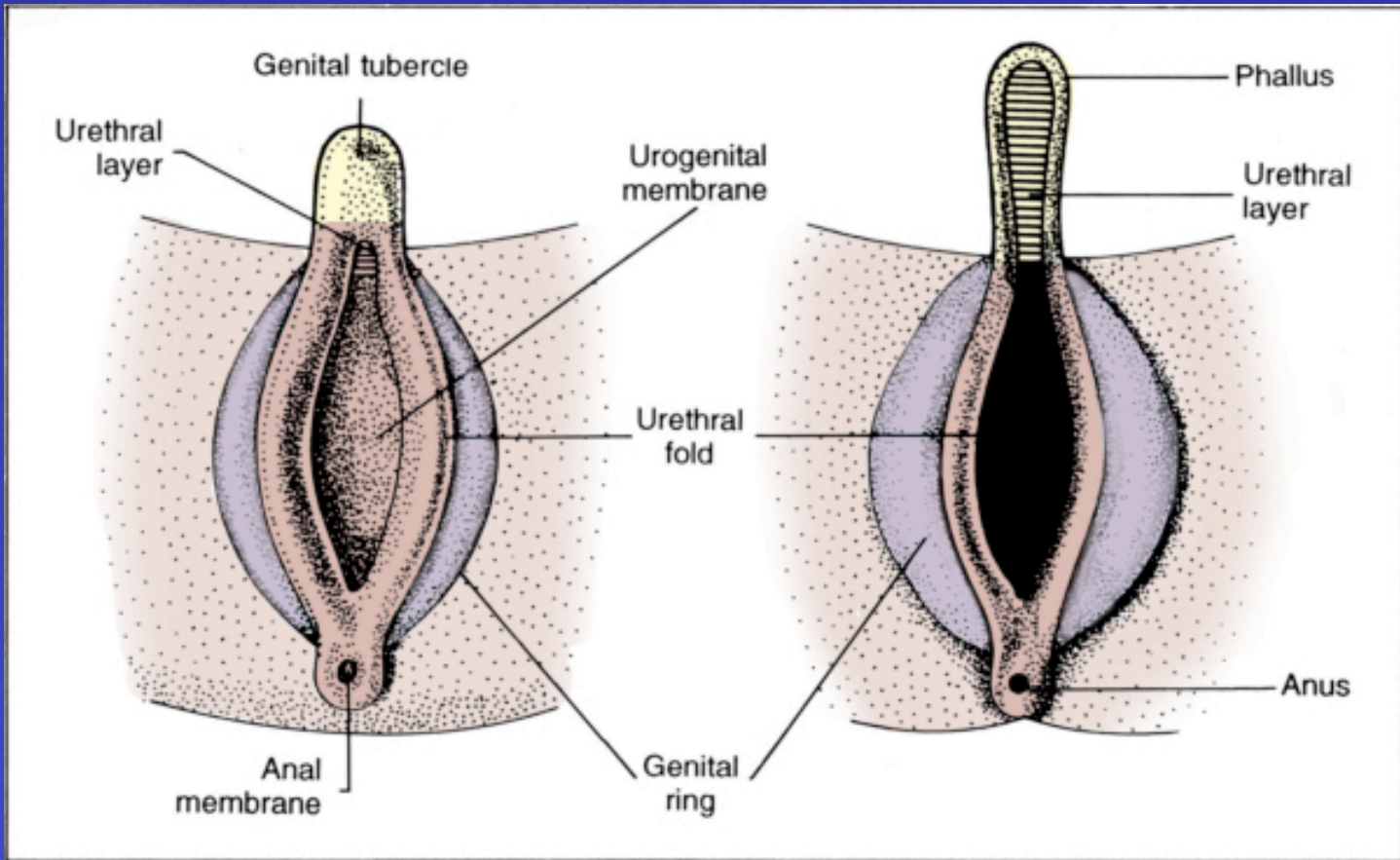
### Indifferent



### Male



**Virilization (external view)** Normal and abnormal differentiation of the external genitalia. Diagrams of normal female and male anatomy flank a series of schematic representations of different degrees of virilization, graded using the scale developed by Prader. Reproduced with permission from: White, PC, Speiser, PW. Congenital adrenal hyperplasia due to 21-hydroxylase deficiency. *Endocr Rev* 2000; 21:245. Copyright © 2000 The Endocrine Society.

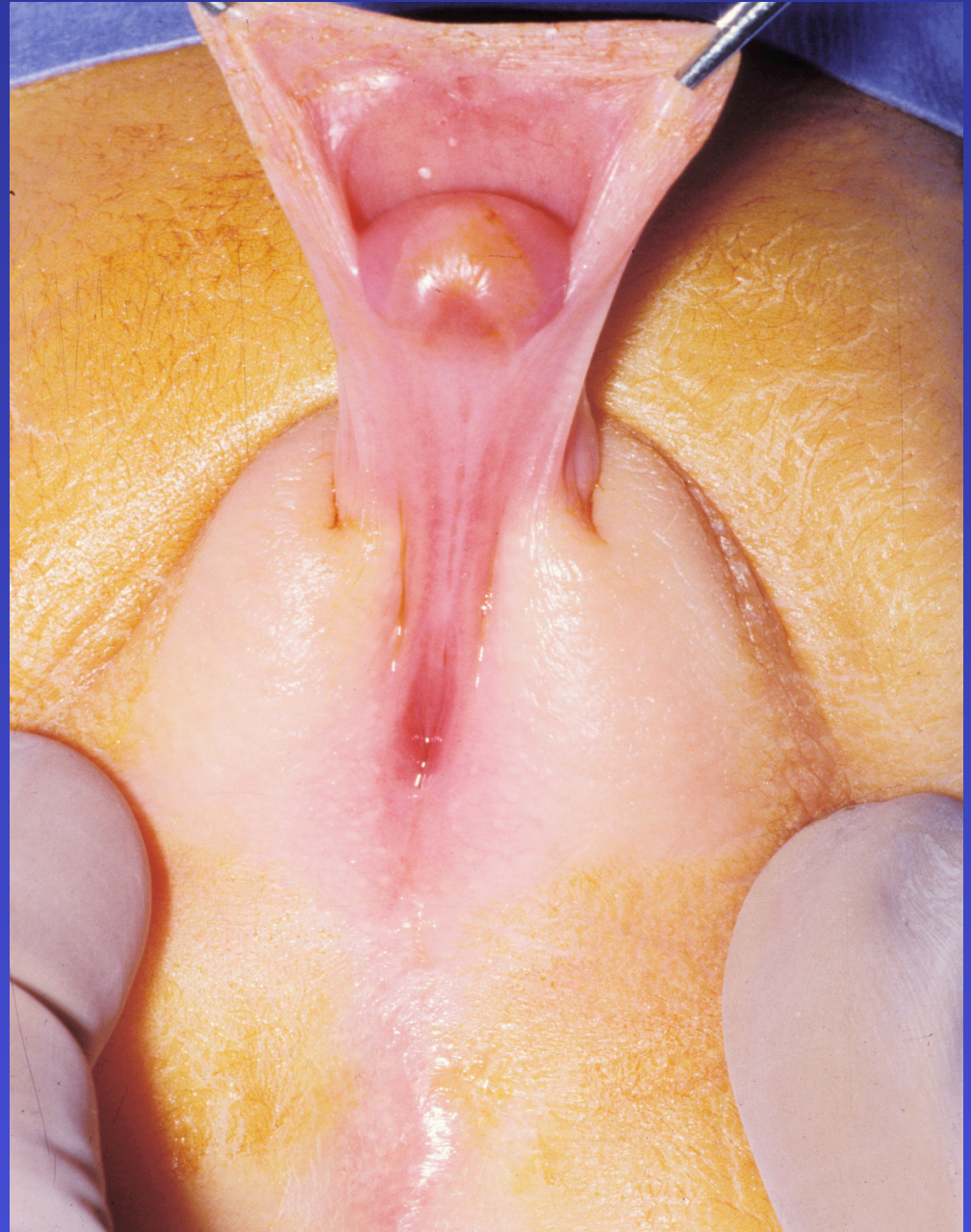

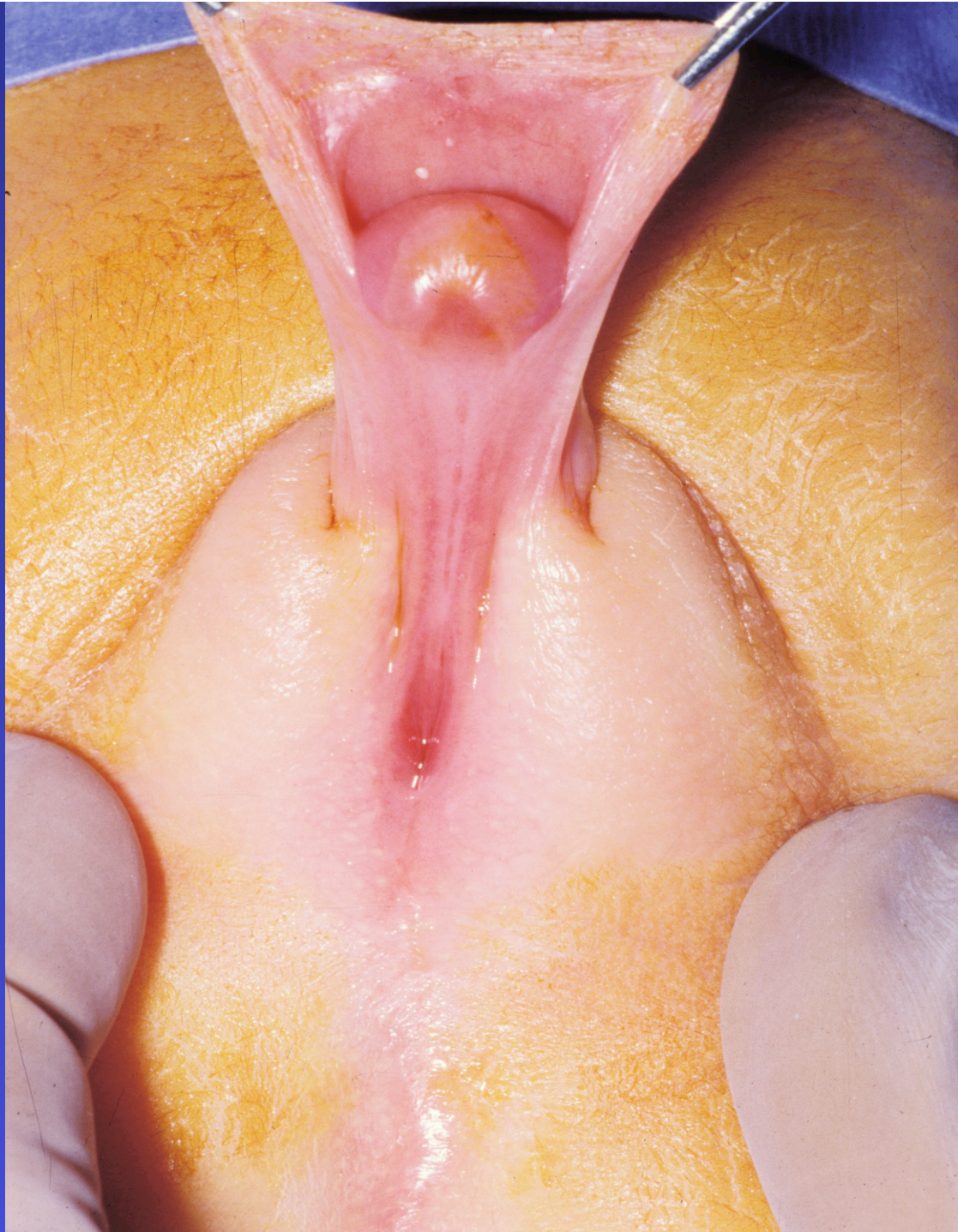-Nonpalpable testes

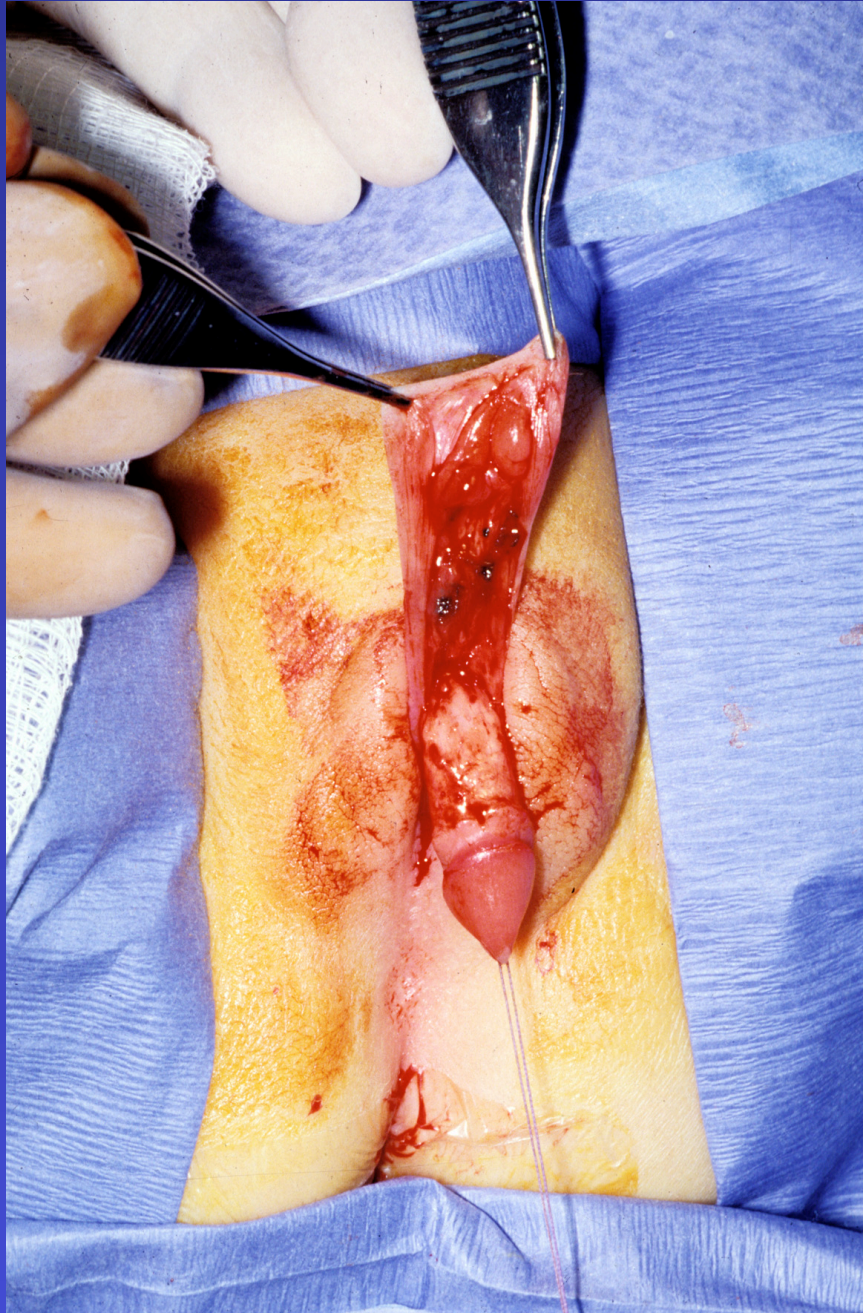
-Hypospadias

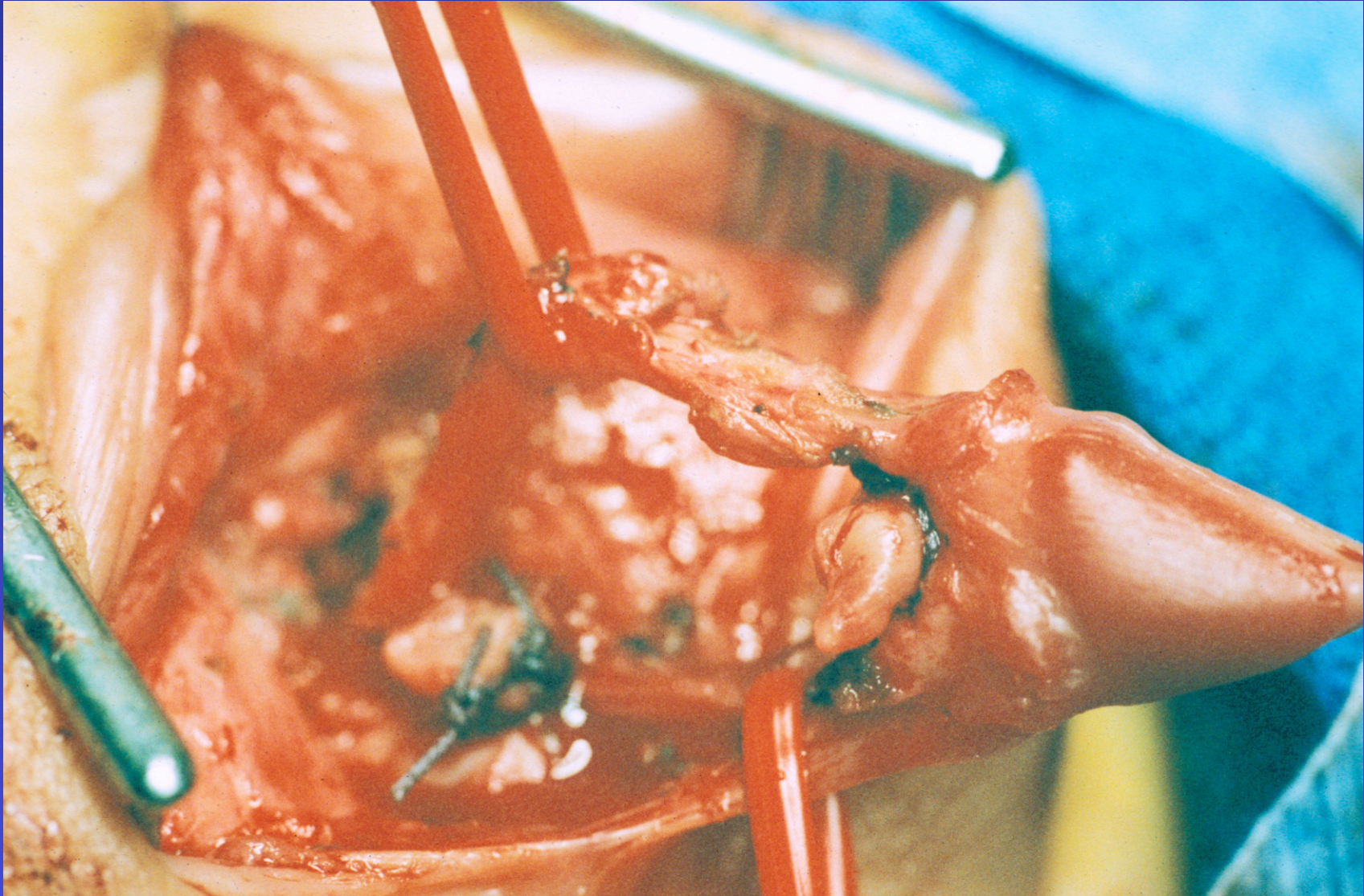
- small phallus with curvature

**-ALERT !!**  
**-ALERT !!**  
**-ALERT !!**

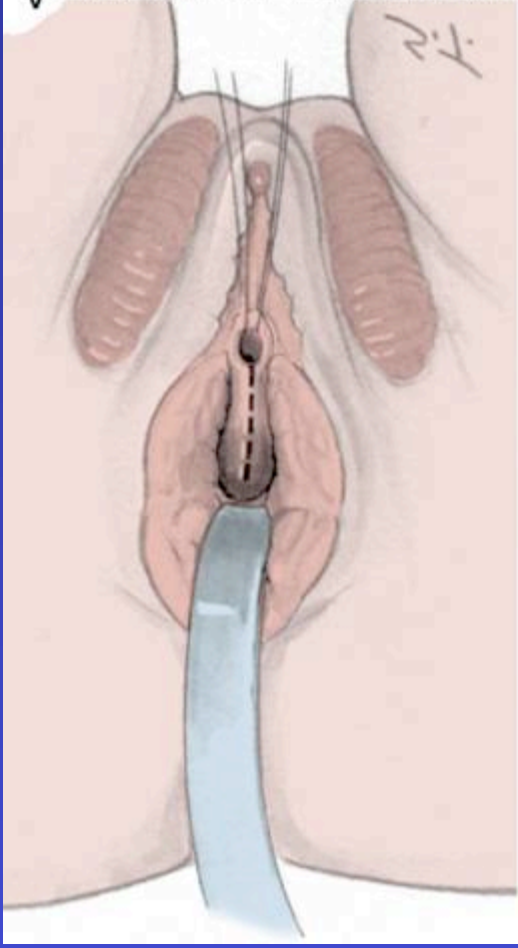




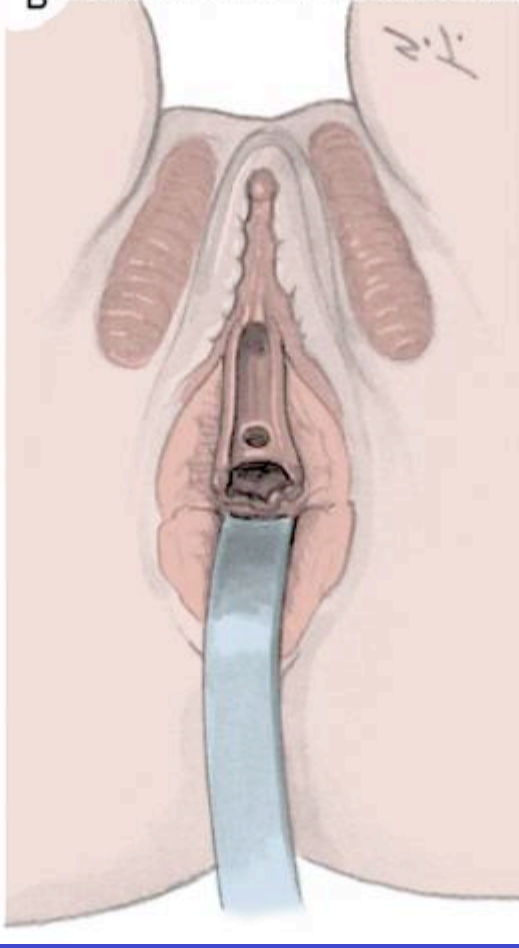




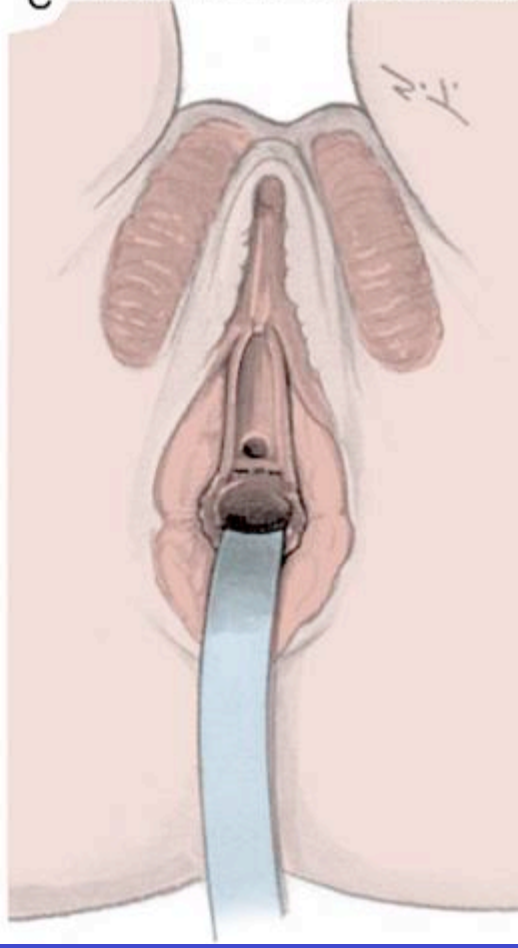
A © IND. UNIV. MED. ITUZI. DEPT. 00

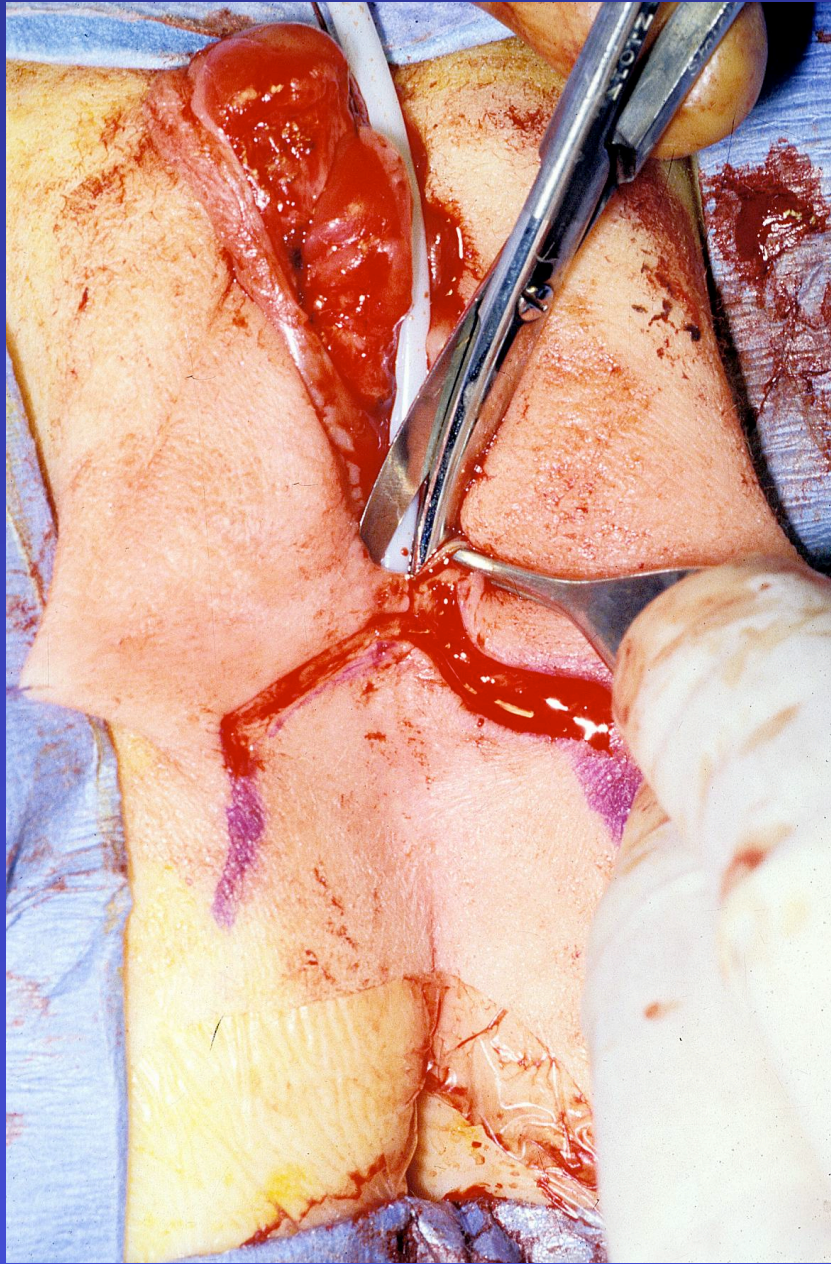


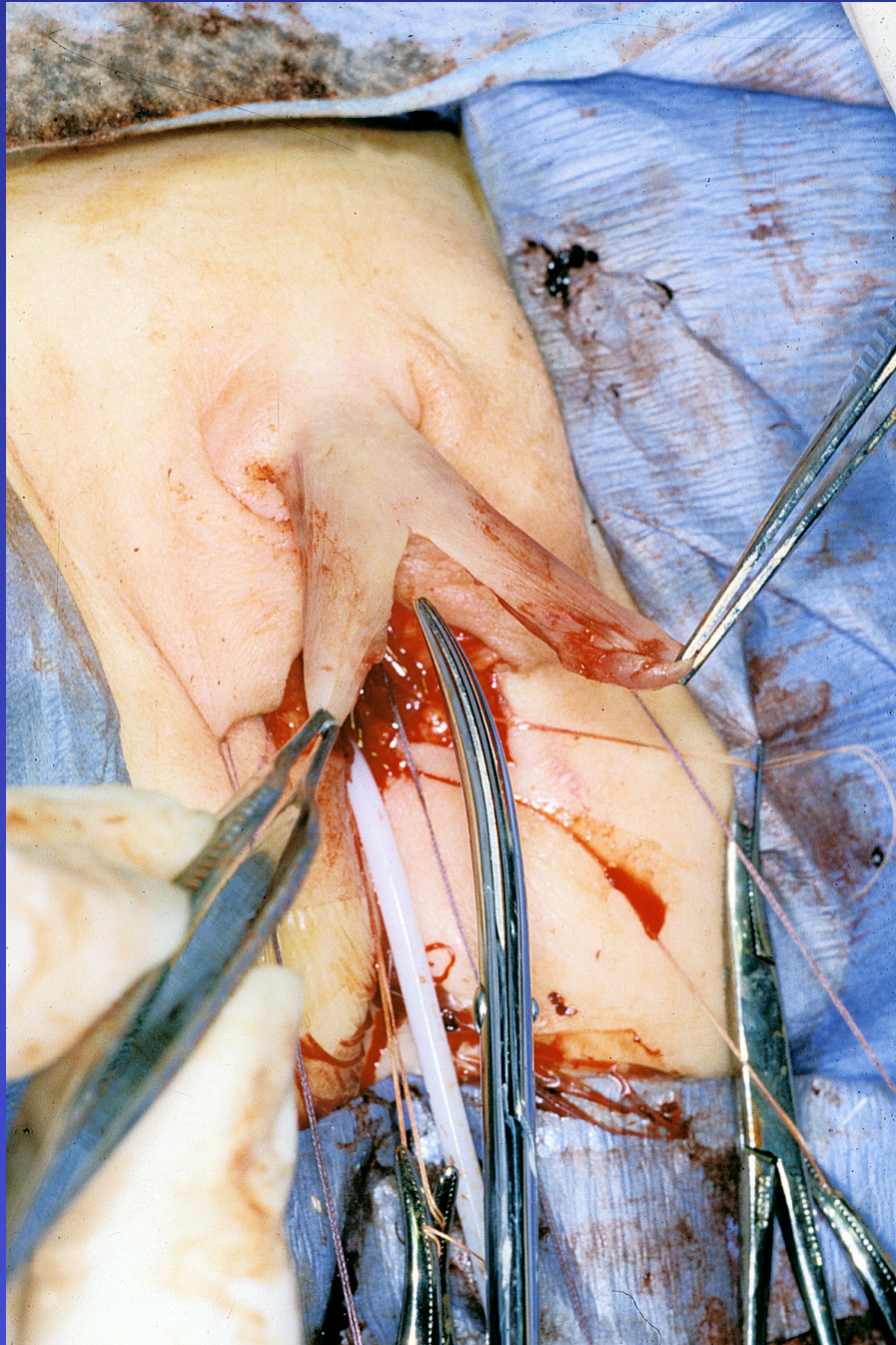
B © IND. UNIV. MED. ITUZI. DEPT. 00

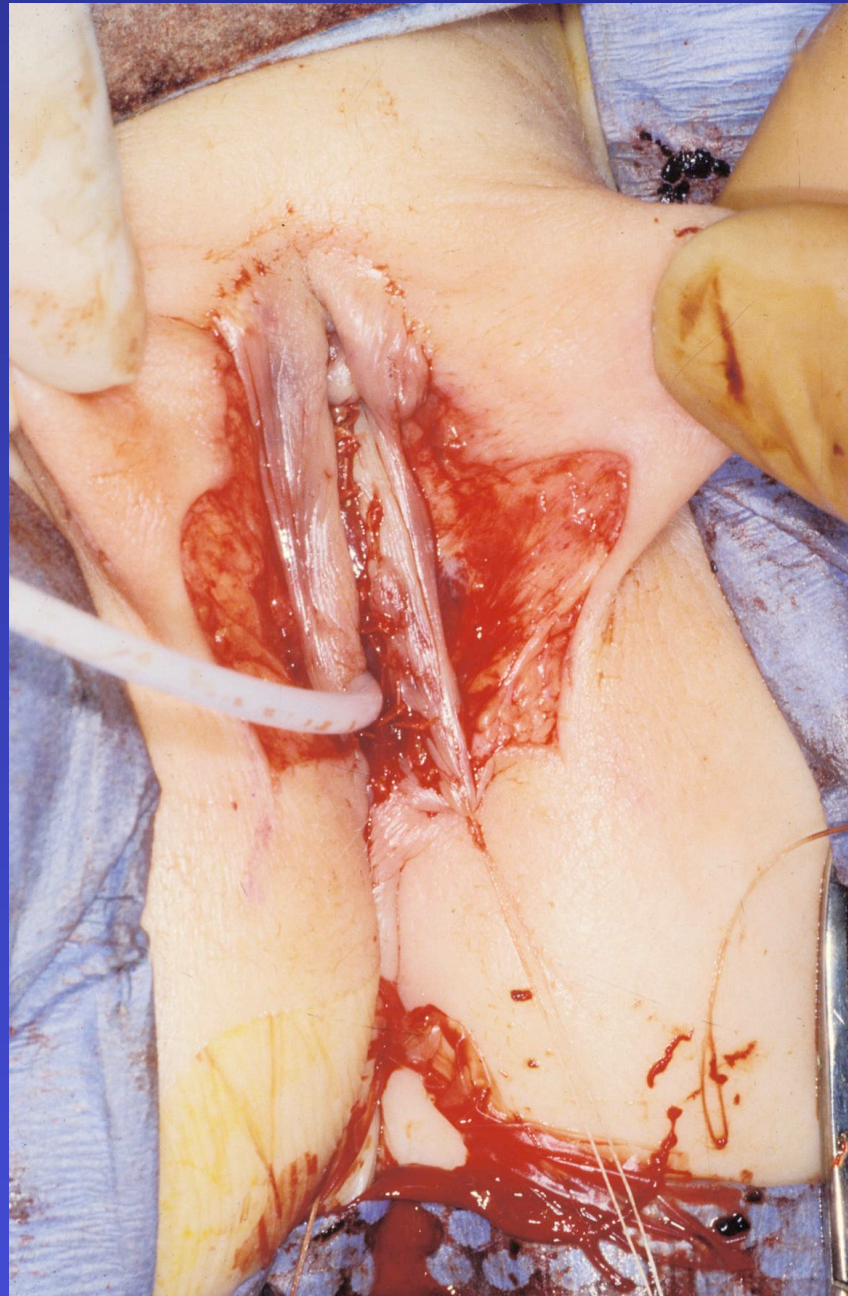


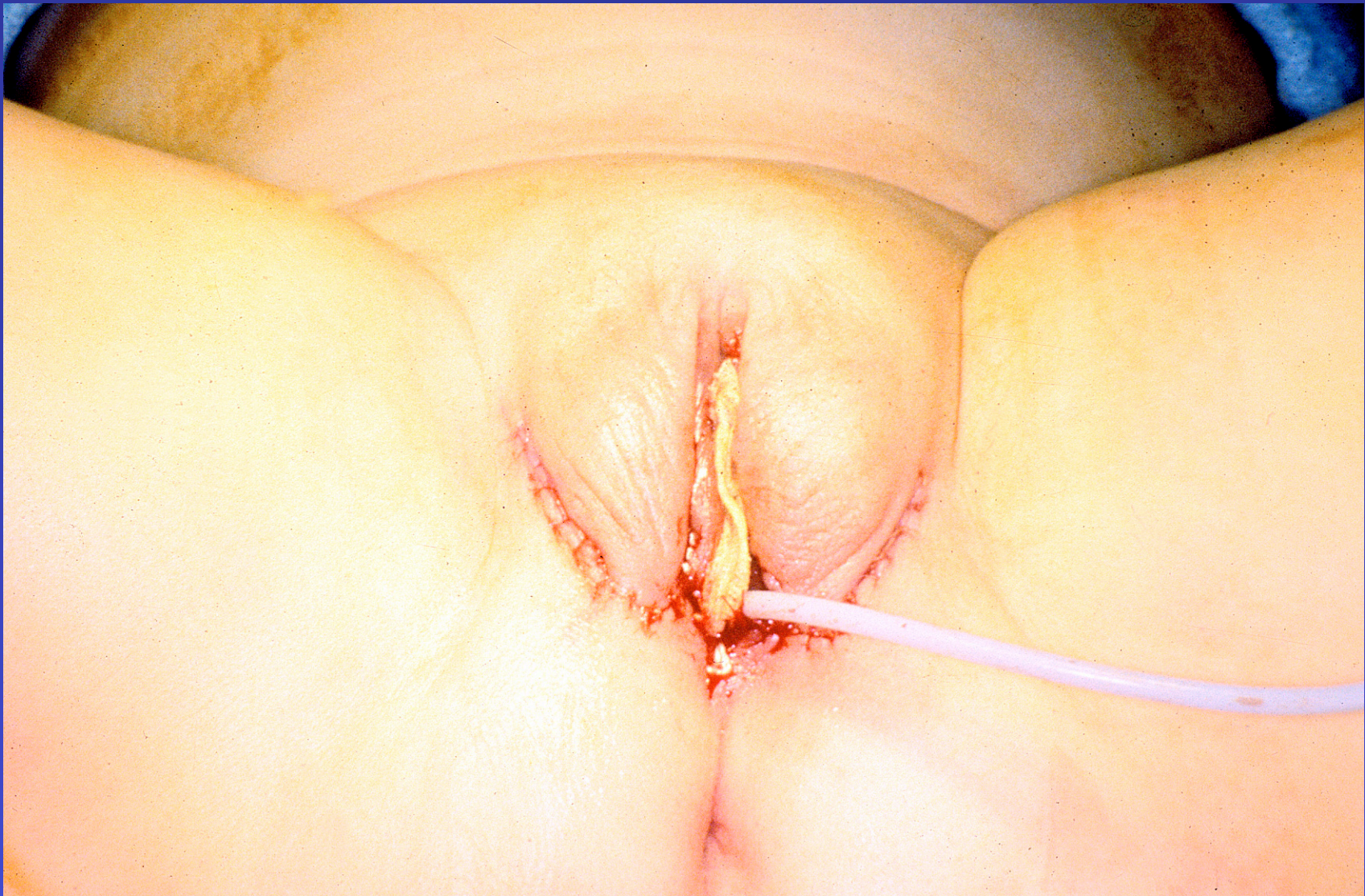C © IND. UNIV. MED. ITUZI. DEPT. 00

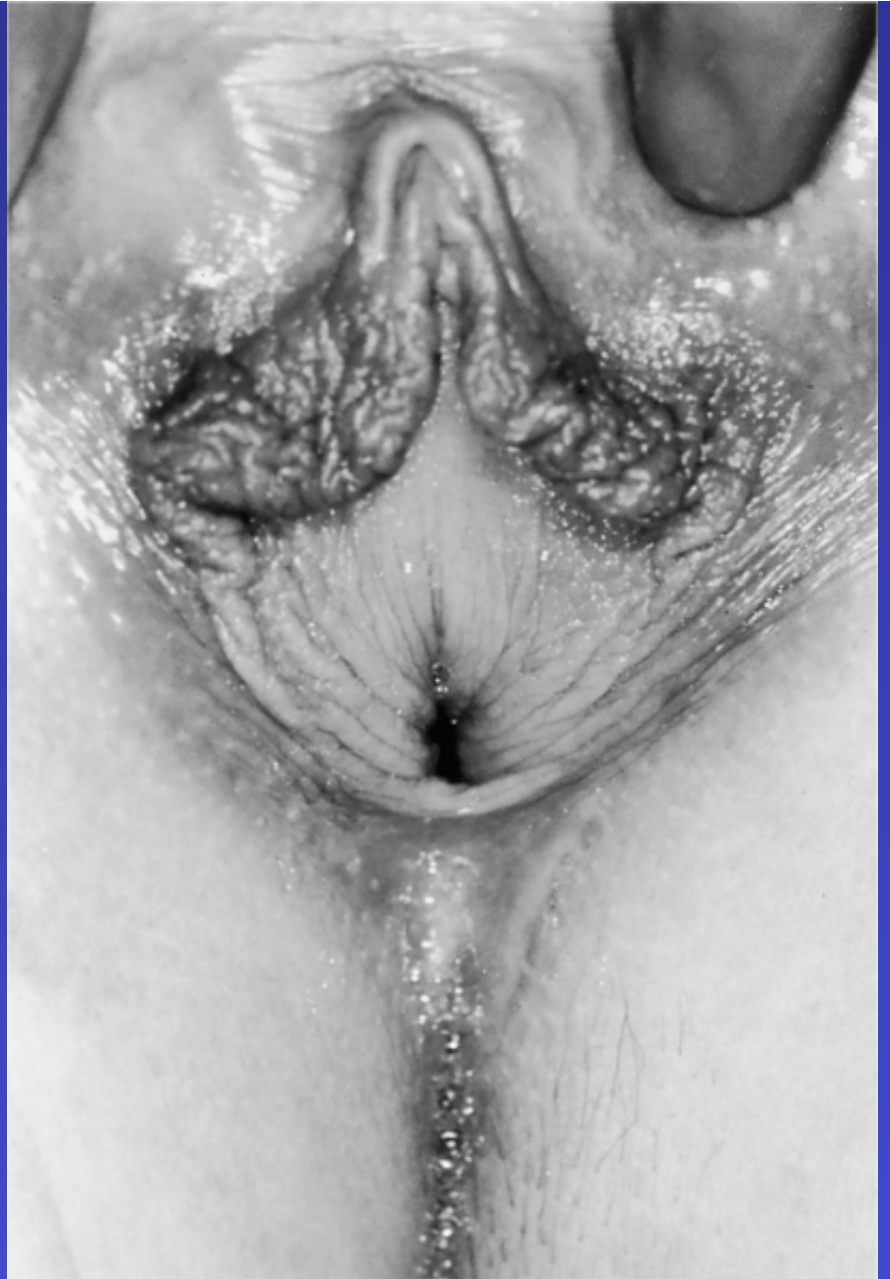
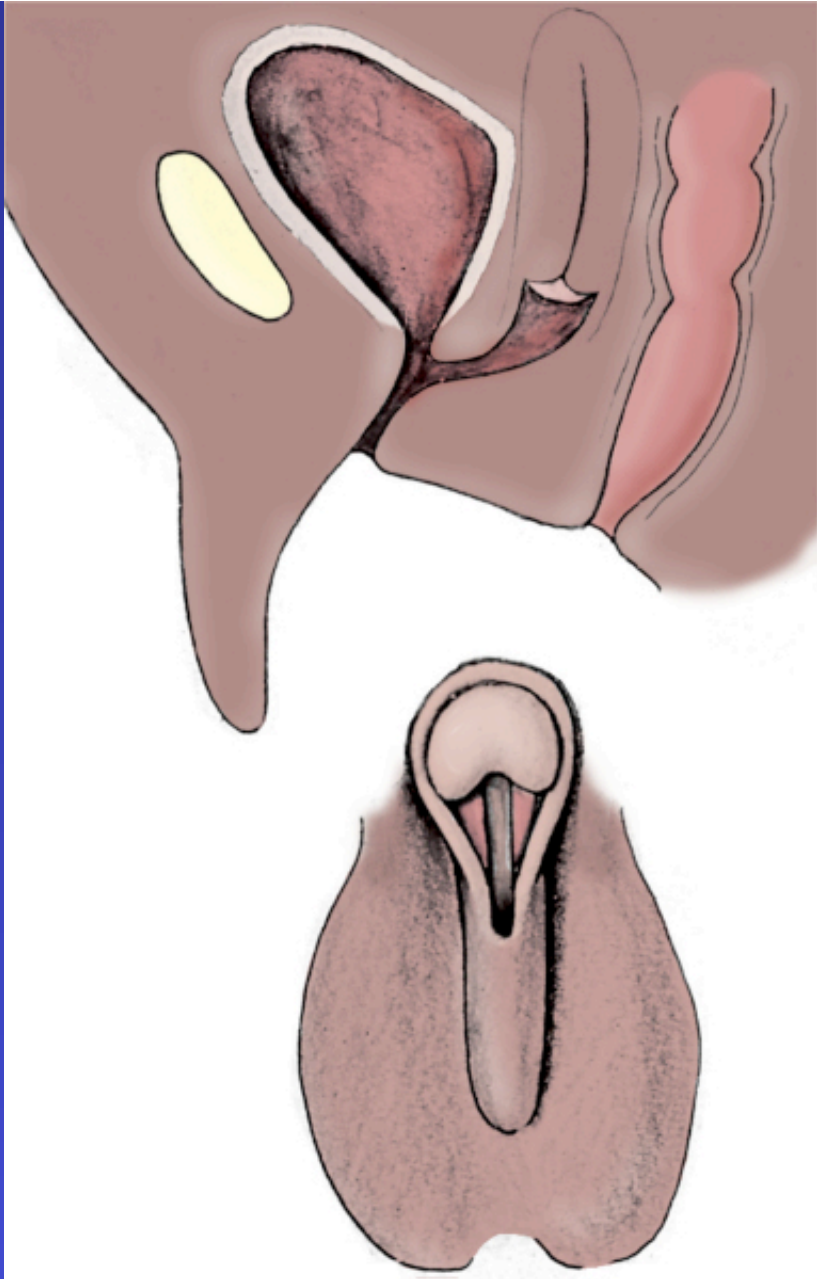




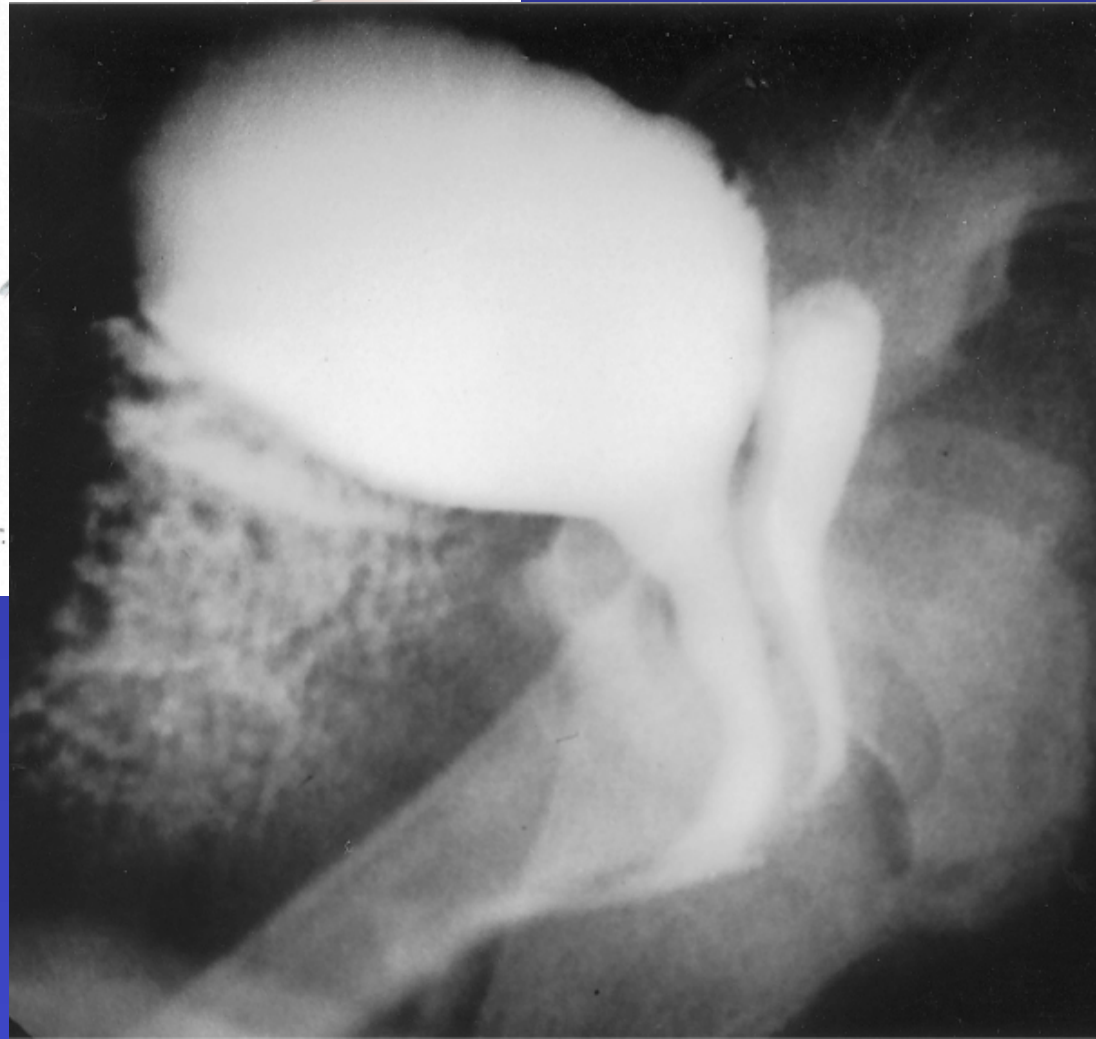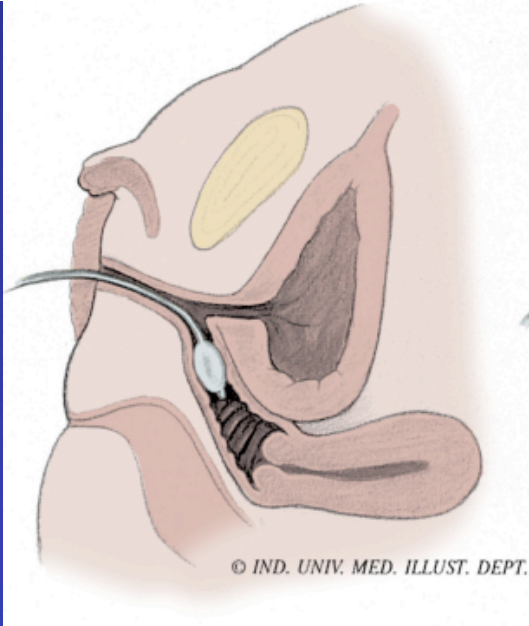




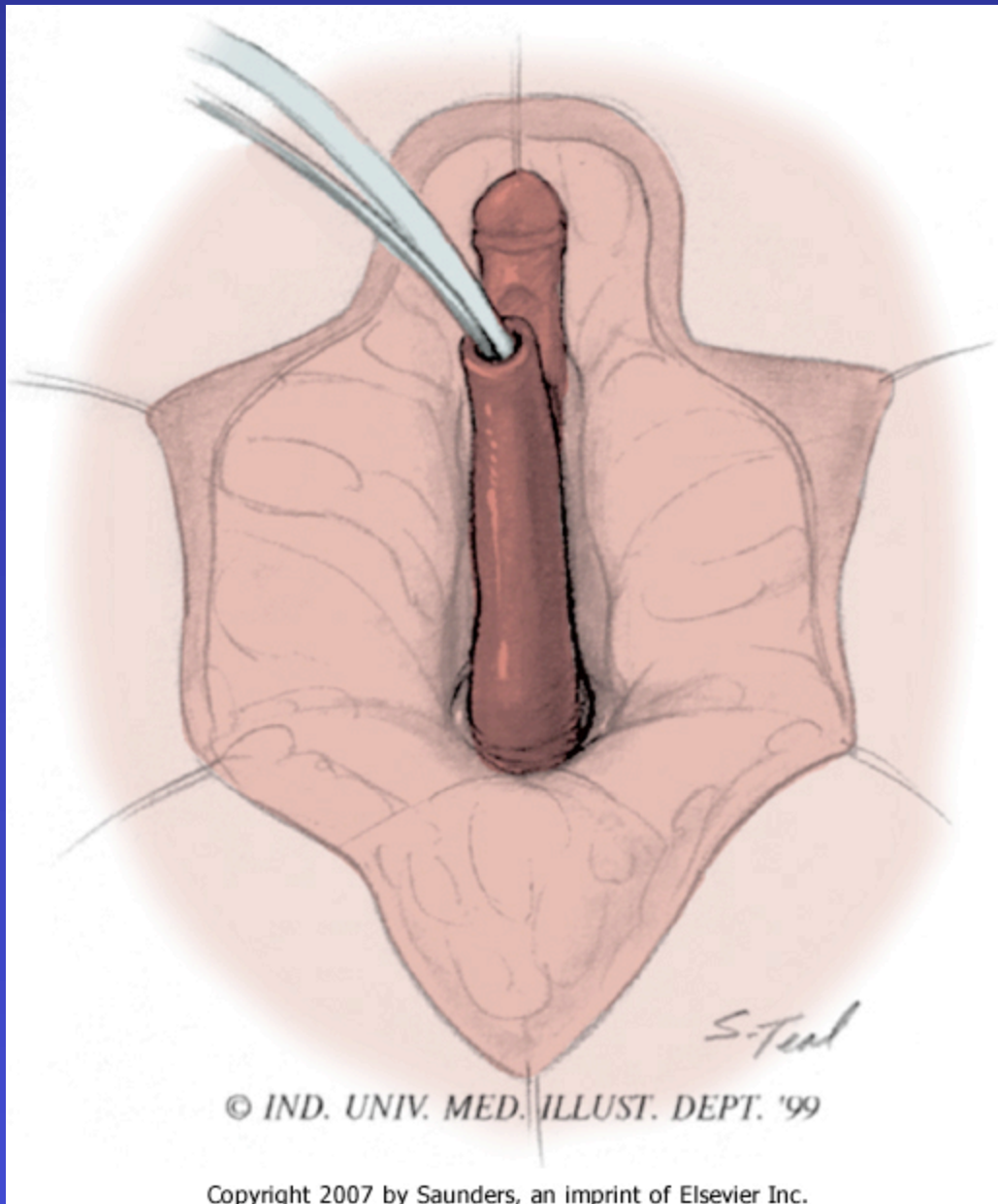


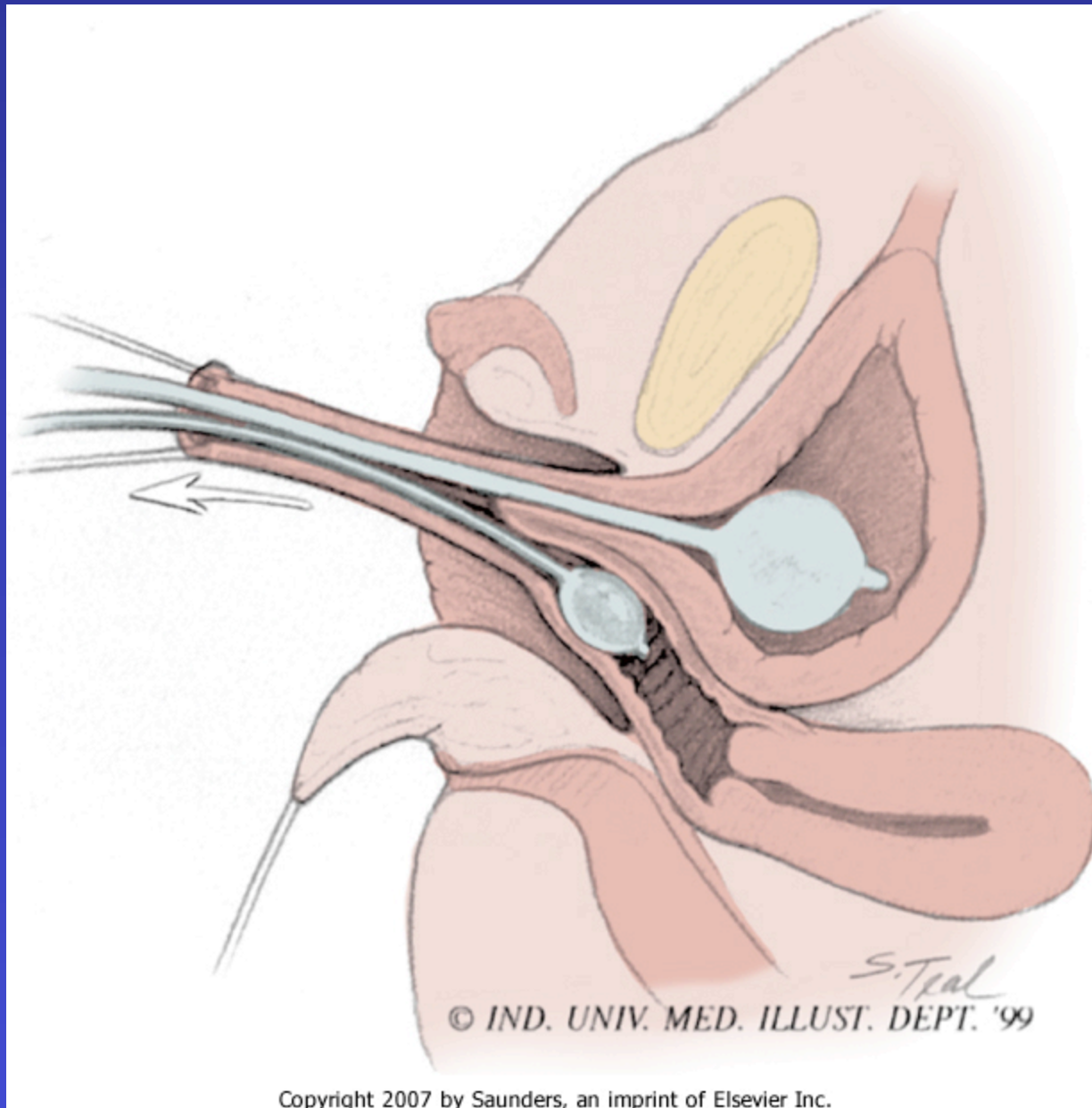


**UROGENITAL SINUS**

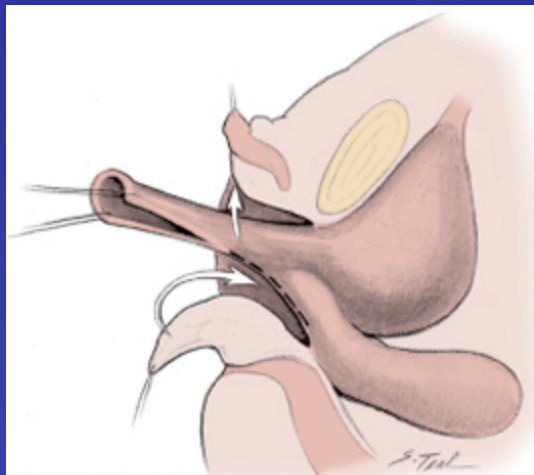


## UROGENITAL SINUS

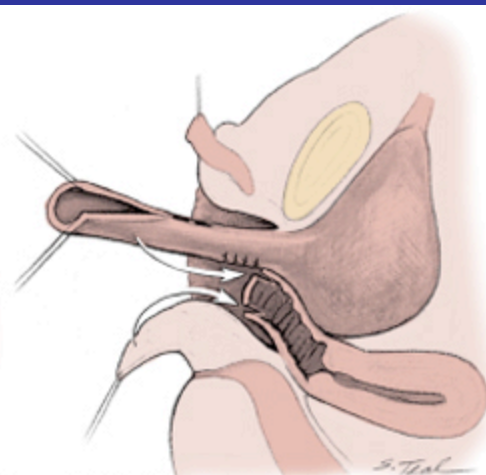




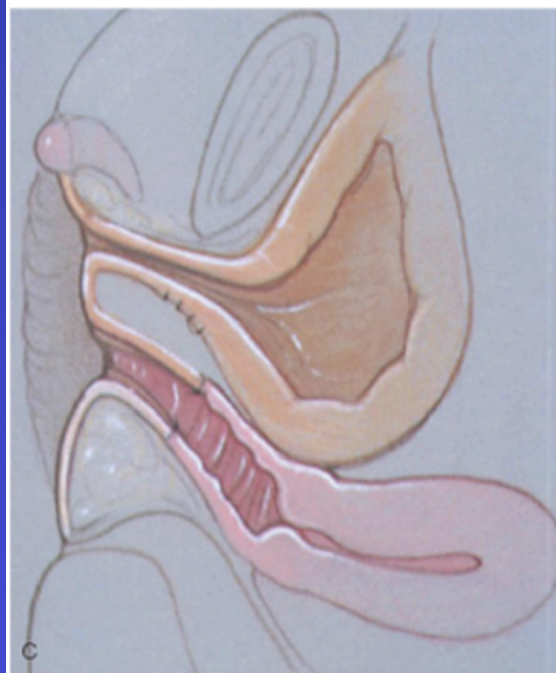Copyright 2007 by Saunders, an imprint of Elsevier Inc.



A © IND. UNIV. MED. ILLUSTR. DEPT. '99

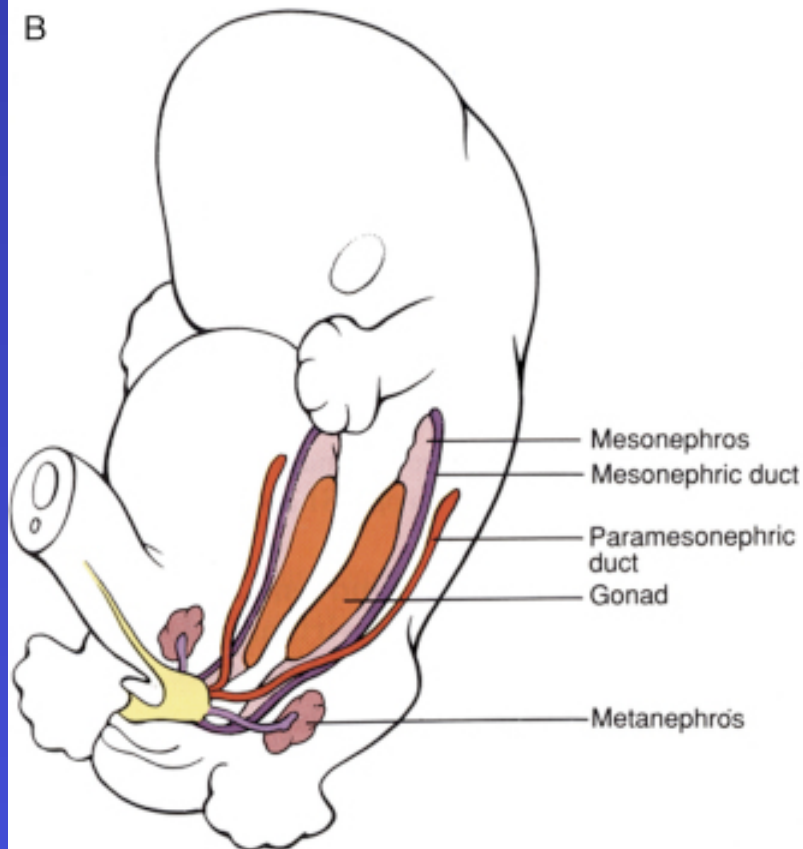
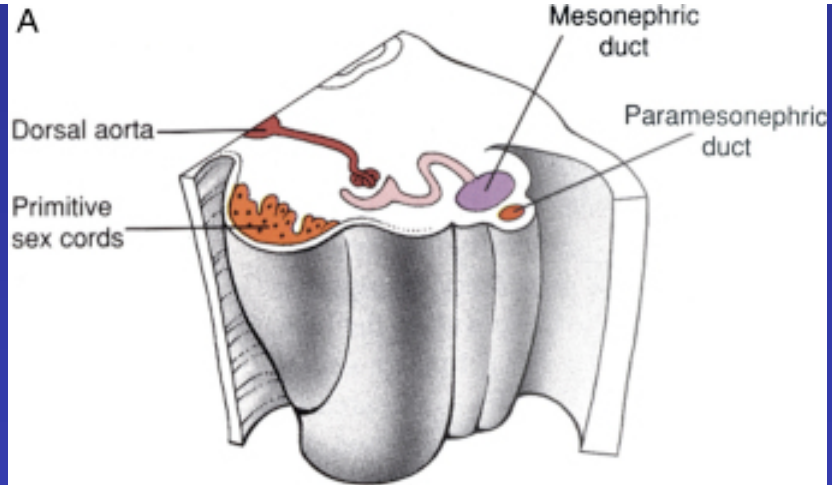


B © IND. UNIV. MED. ILLUSTR. DEPT. '99



C

Copyright 2007 by Saunders, an imprint of Elsevier Inc.

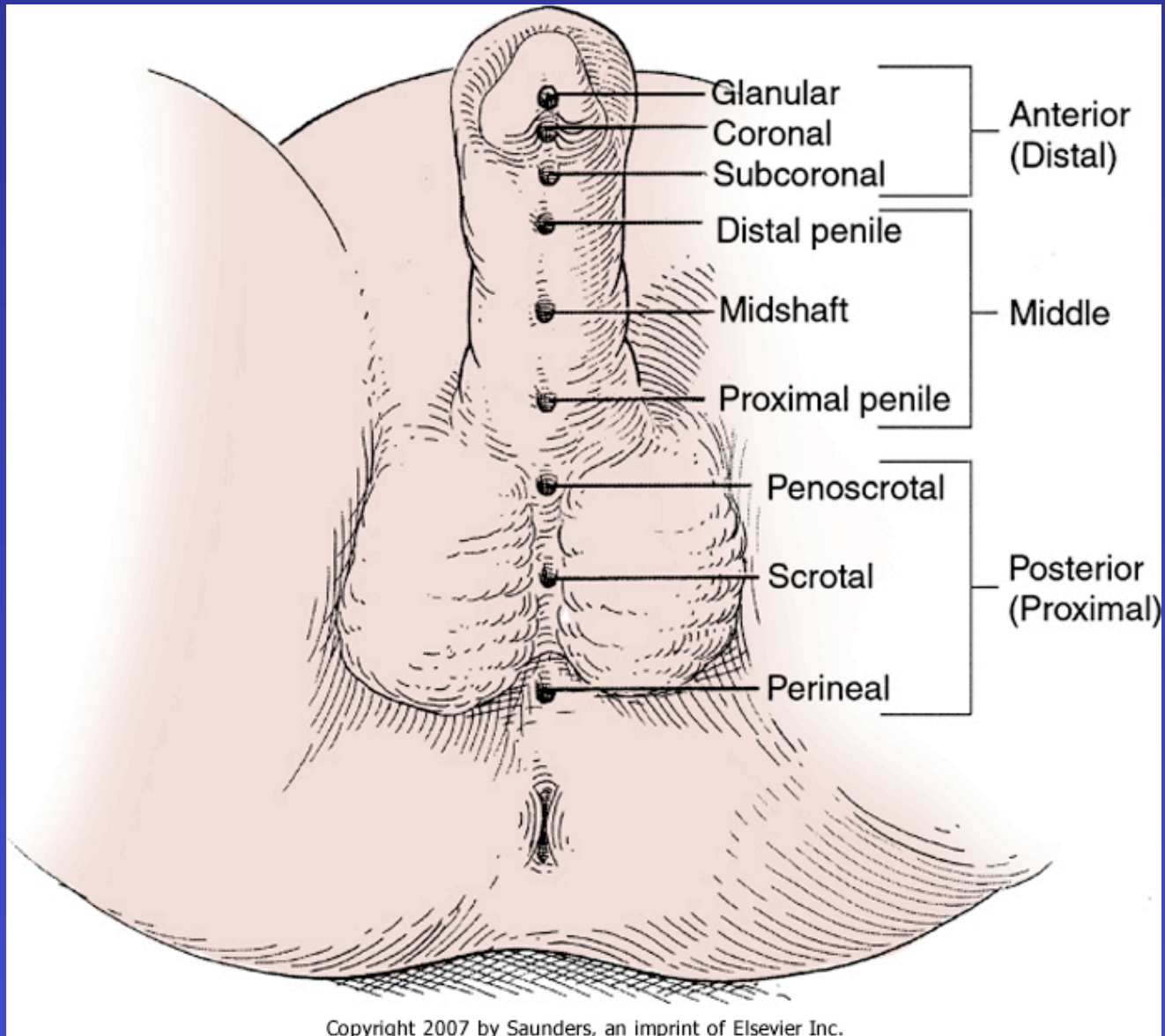


- **Association with Urinary Tract Anomalies**

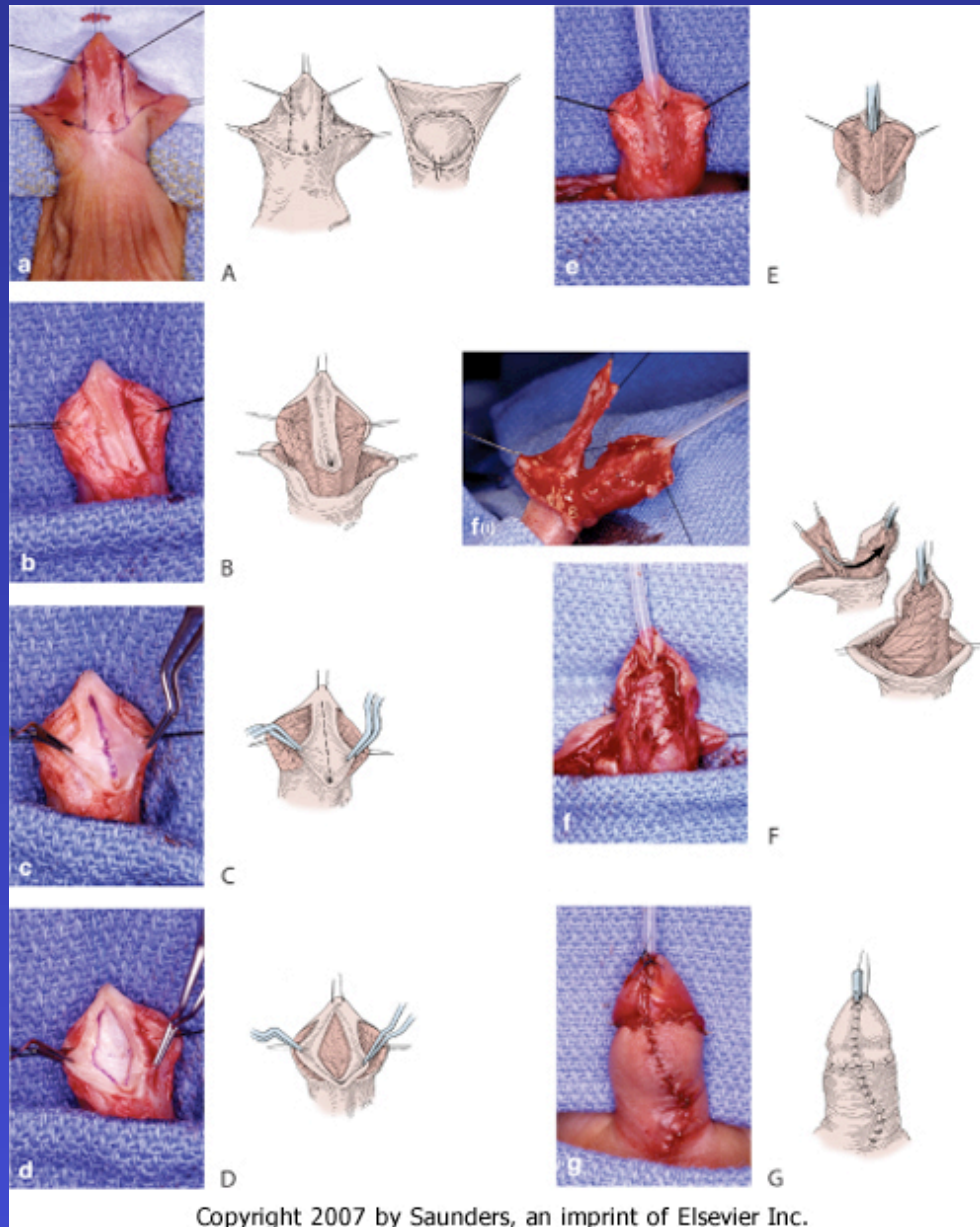
- Renal agenesis
- Ectopic ureters

# Albert Einstein

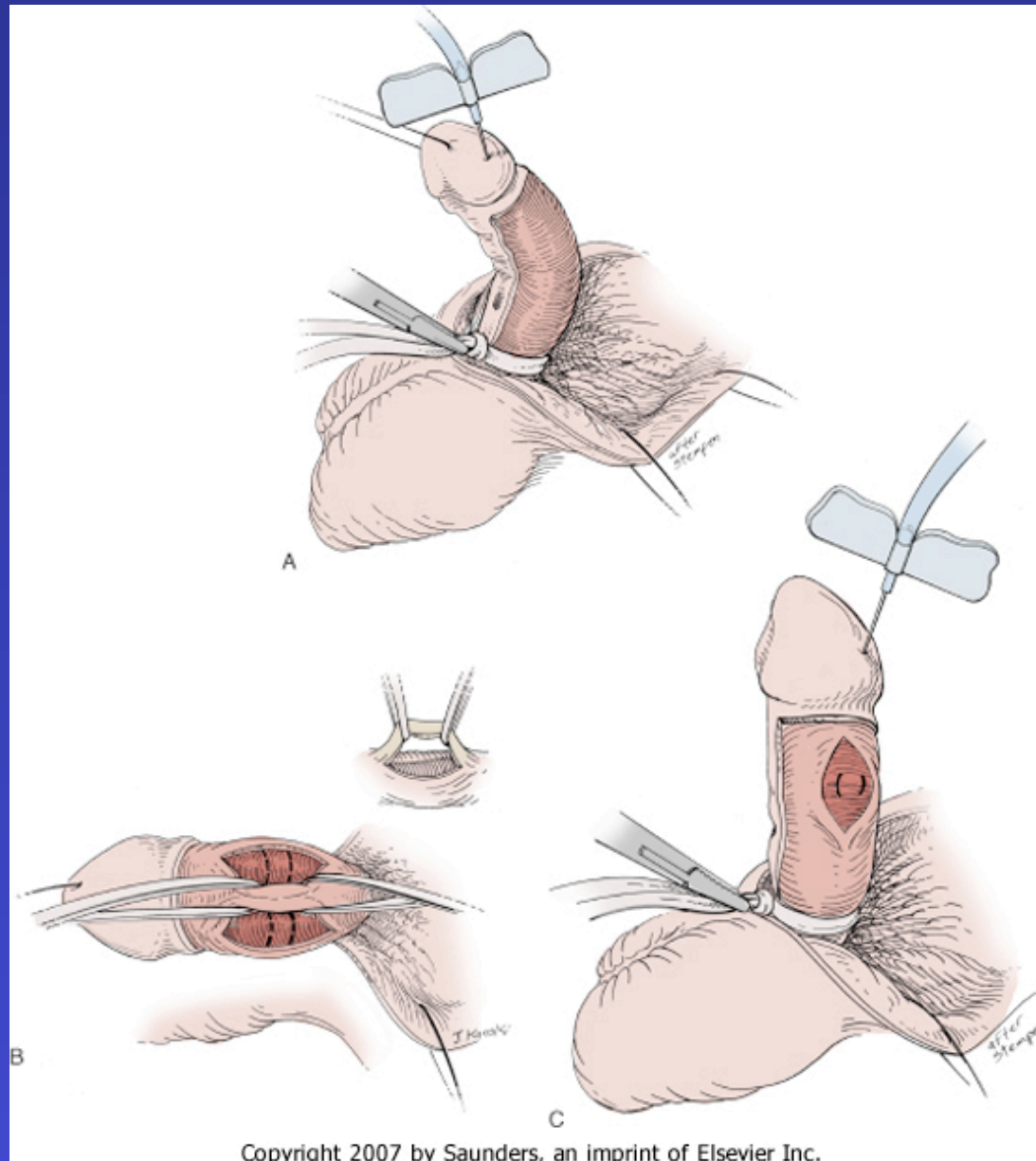
- “Imagination is more important than knowledge “
- "The secret to creativity is knowing how to hide your sources."
- “It’s not that I was so smart; I just stayed with a problem longer”



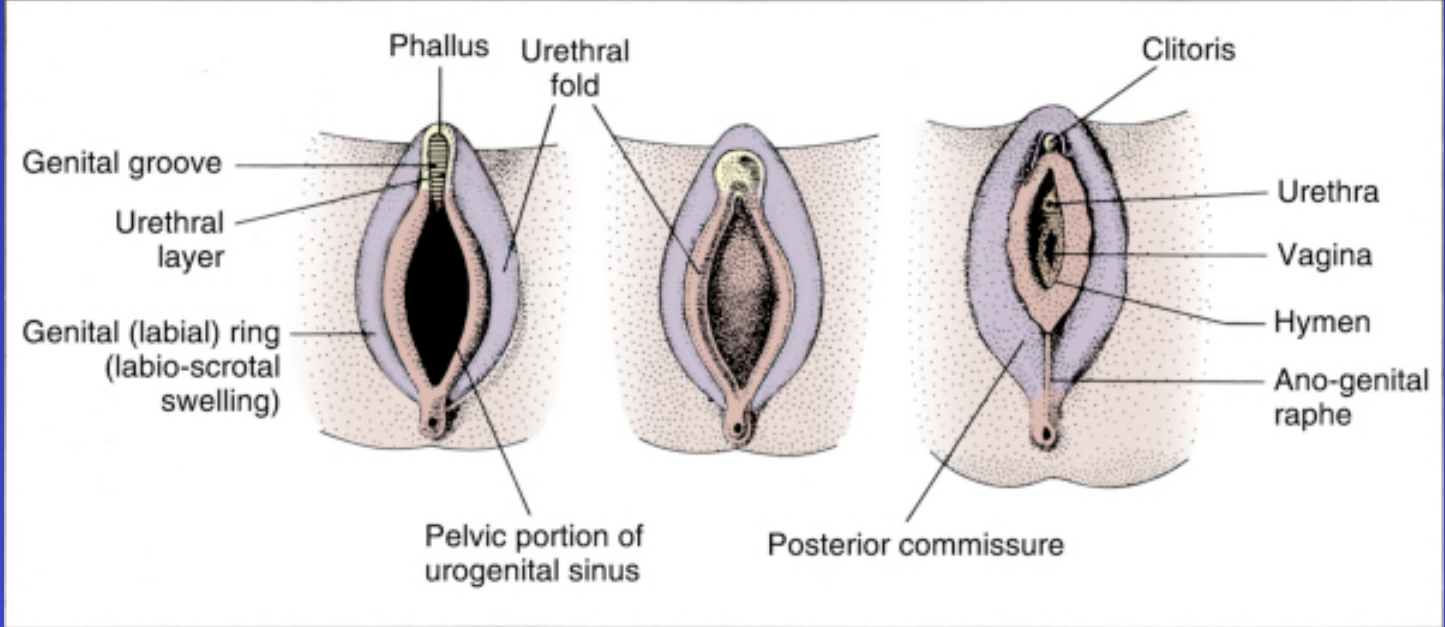
## Hypospadias

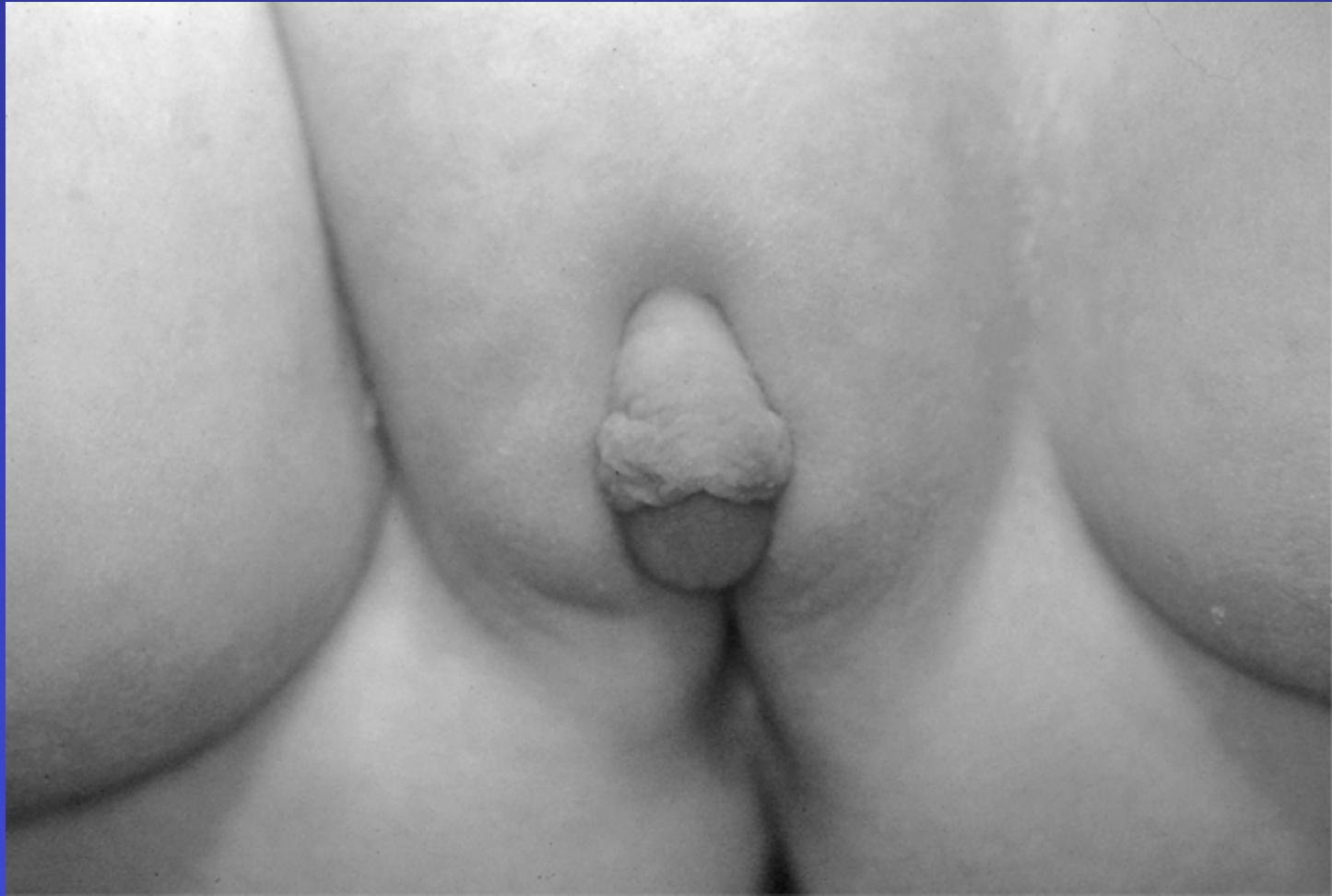

## Hypospadias repair



## Hypospadias repair





CAH 46 XX