

Case 7: RIGHT HEMIPARESIS (Side CC11-2; right panel only)

Chief Complaint: The patient is a 59 year old man who developed sudden **difficulty walking, right arm weakness, and slurred speech.**

History of Present Illness/Past Medical History: The patient has a long history of hypertension and cigarette smoking. He had no other medical problems until the day of admission, when, while walking home from the newsstand he suddenly developed difficulty walking, requiring support from his son. Upon reaching his apartment, he was unable to raise a cup of coffee with his right hand, and his speech was noted to be slurred. His family, therefore, brought him to the emergency room.

Physical Examination: Thin male appearing anxious but otherwise in NAD.
T=97.4 P=92 R=18 BP=130/90; Neck - supple; Lungs - clear; Cardiac - RR no M/G/R

Abd. - nl. BS NT/ND; Ext. - nl. pulses, no edema.

Neuro:

Mental Status - A&Ox3. **Speech slurred** but with normal fluency and comprehension (i.e. **dysarthric** but not aphasic).

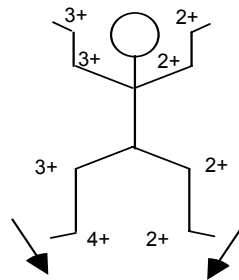
Cranial Nerves - normal except for **slight flattening of R nasolabial fold.**

Motor Strength - **4/5 in R arm and leg.** 5/5 in left arm and leg throughout.

Reflexes - (see sketch).

Coord/Gait - **RAM and FNF slowed on R. Gait - req. support (R weakness).**

Sensation - Normal to all modalities throughout.



Questions:

1. Based on your knowledge of neuroanatomy attempt to localize which structures in the nervous system could be affected in order to produce each of the symptoms and signs appearing in **boldface** above.
2. What are the possible locations for a lesion that could explain these finding?