

Cardiovascular Pathophysiology: Right to Left Shunts aka Cyanotic Lesions

Ismee A. Williams, MD, MS

iib6@columbia.edu

Pediatric Cardiology

Learning Objectives

- To discuss the hemodynamic significance of right to left shunts
- To describe the common cyanotic cardiac lesions in the newborn
- To understand the different causes of cyanosis: obstruction to pulmonary blood flow vs mixing

Importance of Congenital Heart Disease

- Incidence 6 to 8 per 1000 births
- 15% are *life threatening*
- 25% are discharged without diagnosis
- 1/3 have cyanosis

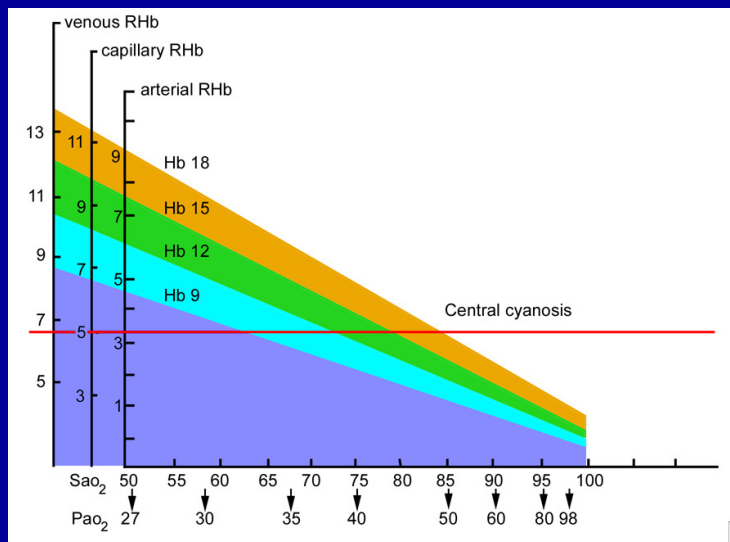
What is Cyanosis?

- Bluish discoloration of skin that occurs when the amount of deoxygenated hemoglobin ≥ 5 g/dL in capillaries
- Central Cyanosis: decreased systemic oxygen delivery
- Peripheral Cyanosis: increased oxygen extraction by tissue

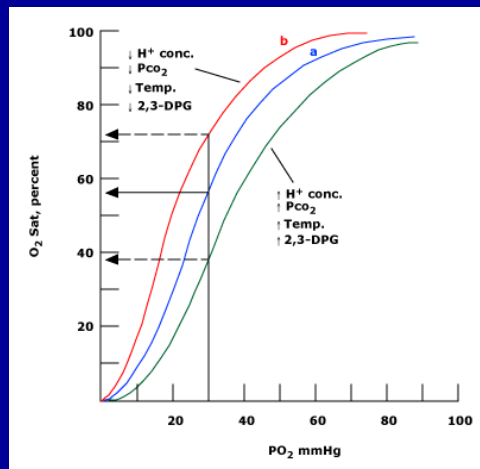
Factors affecting detection of Cyanosis

- **Total hemoglobin concentration** affects the level of O₂ saturation at which cyanosis is observed
 - Hgb conc = 9 g/dL, need an O₂ Sat of 67% to have 3-5 g/dL of reduced hemoglobin and **see cyanosis**
 - Hgb conc = 20 g/dL, see cyanosis at O₂ Sat of 85%
 - **Decreased O₂ sat may not be recognized in the setting of anemia**
- **Skin pigmentation**
- **Factors that shift the oxygen dissociation curve to the left** result in oxygen binding more tightly to Hgb and decreased release to the tissue at a given O₂ tension (PO₂)
 - Therefore, will be harder to **see cyanosis** (get 5 g/dL of deoxygenated Hgb) at any given PO₂

Won't see cyanosis if anemic



Detecting Cyanosis



- Shift to the left (harder to see cyanosis): hyperventilation, hypothermia, and low 2,3 diphosphoglycerate, fetal Hgb
- Shift to the right (easier to see cyanosis): acidosis, fever, or increased adult hemoglobin

Causes of Cyanosis

- Pulmonary causes (most common)
- Hemoglobin problems
- Poor perfusion (sepsis)
- PPHN
- Cardiac causes

Persistent Pulmonary Hypertension of the Newborn

- Used to be called Persistent Fetal Circulation
- Abnormal pulmonary vasoconstriction or failure to “relax” leads to right to left shunting at the foramen ovale and the ductus arteriosus
- Profound cyanosis
- Associated with neonatal asphyxia, maternal infection
- Apgar scores are low
- Usually self-limited with NO and ECMO treatment

Cardiac Causes of Cyanosis

- Decreased/obstructed pulmonary blood flow
- Systemic and Pulmonary venous Mixing

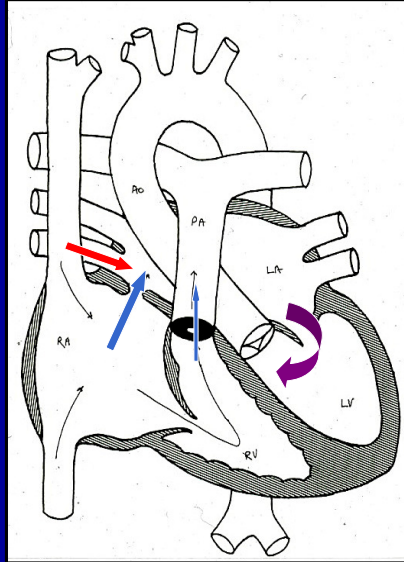
Decreased Pulmonary Blood Flow

- Obligatory intracardiac right to left shunting
- Pulmonary blood flow is provided by an alternative path – usually the ductus arteriosus
- Very cyanotic

Cardiac Lesions causing cyanosis due to decreased pulmonary blood flow

- Pulmonary stenosis
- Pulmonary atresia
- Tricuspid atresia
- Tetralogy of Fallot

Pulmonary Stenosis

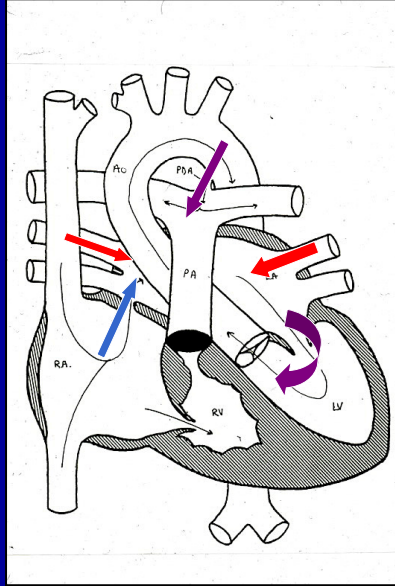


- Location of obstruction varies:
- RV outflow
- Pulmonary Valve Most common
- Main Pulmonary Artery

Pulmonary Stenosis

- 25-30% of CHD
 - Isolated PS in 8-10% of CHD
- Hemodynamic consequence: pressure overload and hypertrophy of the RV
- PE: cyanosis, systolic ejection murmur at LUSB
- Tx: Balloon vs surgery

Pulmonary Atresia

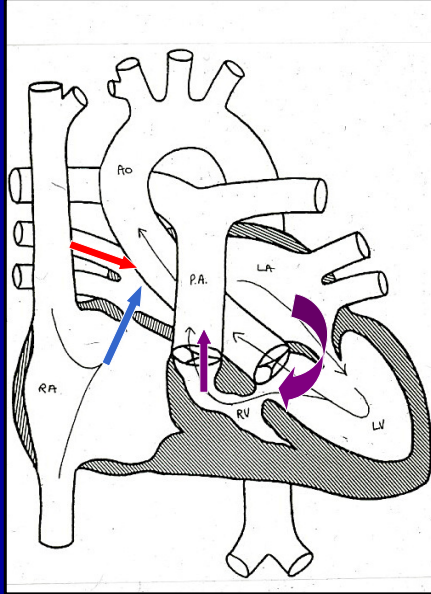


- Obligate right to left flow across the foramen ovale
- Pulmonary blood flow supplied by the ductus arteriosus
“ductal dependent”

Pulmonary atresia

- 3% of CHD (0.041 per 1000 live births)
- Size of the RV varies
- PE: cyanosis, no systolic ejection murmur (no flow)
 - may have holosystolic murmur at LLSB associated with tricuspid regurgitation
- CXR: black lungs
- Treatment depends on “flavor” of PA/IVS
 - balloon of pulmonary valve if RV size adequate
 - aortico-pulmonary shunt to increase pulmonary blood flow
 - staged surgery to a Fontan if RV too small
 - Heart transplant if RV dependent coronary sinusoids

Tricuspid Atresia

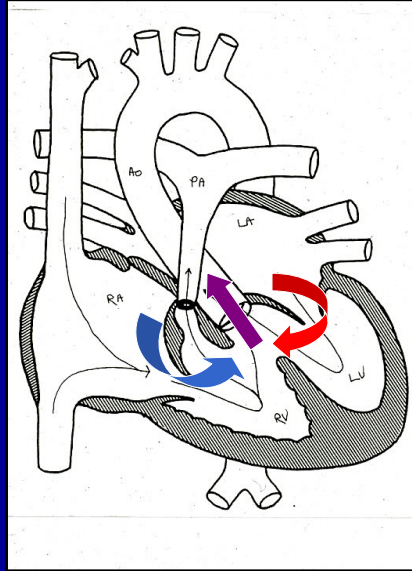


- Obligatory right to left shunt at the PFO
- Typically have a VSD that allows blood into the RV and out the PA
 - Obstruction to pulmonary flow related to size of VSD
- Hypoplastic right ventricle

Tricuspid Atresia

- 3% of CHD (0.056 per 1000 live births)
- 25% have transposed great vessels and problems with aortic/systemic blood flow
- PE: systolic murmur, cyanosis
- Tx: staged surgery to a Fontan

Tetralogy of Fallot



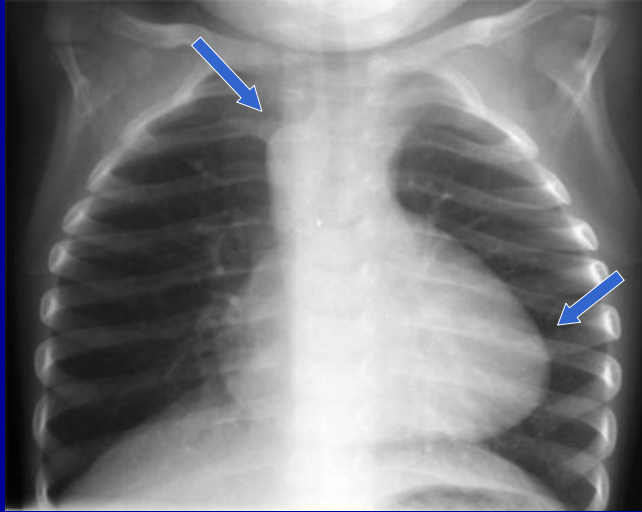
Single defect: anterior malalignment of the interventricular septum

- VSD
- Aortic override
- Pulmonary Stenosis
- RVH

Tetralogy of Fallot

- 3.5-9% of CHD (0.26-0.8 per 1000 live births)
- Commonly associated with other defects
 - DiGeorge Syndrome in 25%
- Degree of pulmonary obstruction varies
- Symptoms depend on amount of obstruction to pulmonary blood flow
 - cyanosis, *tet spells*
- PE: systolic ejection murmur at LUSB
- Tx: Surgical repair of VSD and PS

Boot shaped heart = TOF



Upturned cardiac apex due to RVH

Right aortic arch

Lungs hyperinflated (black) due to decreased blood flow

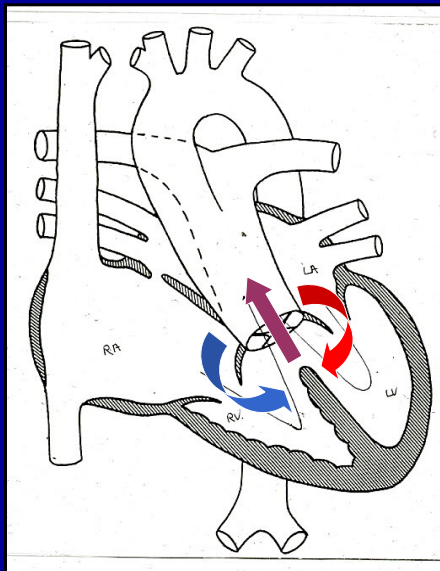
Mixing of Systemic and Pulmonary Venous Return

- No obstruction to pulmonary blood flow
 - Pulmonary flow may be greater than normal
- See both right to left AND left to right intracardiac shunting
- Associated with pulmonary HTN and ventricular failure
- Cyanosis typically less intense than with pulmonary obstruction

Cyanosis due to Mixing

- Truncus arteriosus
- Total anomalous pulmonary venous return (TAPVR)
- Transposition of the Great Arteries (TGA)
- Mixing with Heart Failure
 - HLHS, Aortic stenosis, coarctation

Truncus Arteriosus

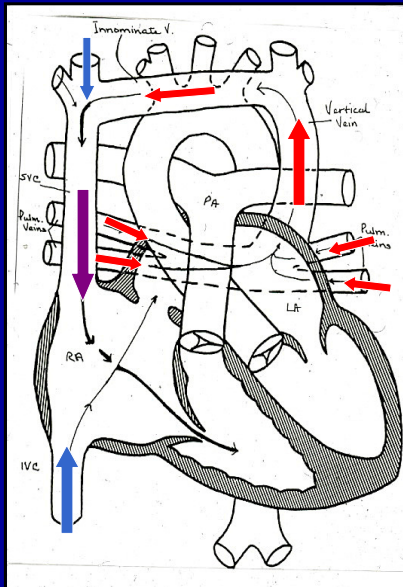


- Aorta and pulmonary artery not separate
- Single vessel gives rise to aorta, coronaries, and pulmonary arteries
- VSD always present
- Systemic and pulmonary venous blood mix at the ventricular level

Truncus arteriosus

- 1-2.5% of CHD (0.08 per 1000 live births)
- Truncal valve usually very dysplastic
- Commonly associated lesions
 - Coronary anomalies, interrupted aortic arch
 - 25% DiGeorge
- PE: cyanosis and murmur of regurgitation
- High risk to develop pulm HTN over time
- Tx: surgical repair in infancy

TAPVR

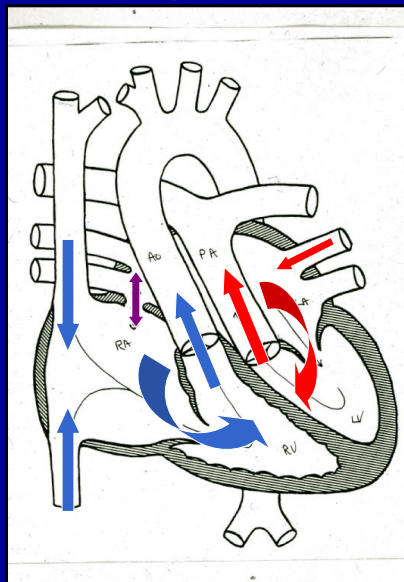


- Pulmonary veins return to the right heart
 - Via supracardiac, intracardiac, or infradiaphragmatic path
- Pulmonary venous blood mixes with systemic venous blood at the atrial level
- Obligatory right to left shunt at atrial level to support systemic flow

TAPVR

- 2-3% of CHD (0.058 per 1000 live births)
- Failure of the left atrium to incorporate the pulmonary veins during development
- Obstruction to pulmonary venous flow is common
 - Can occur at different levels
 - Most common in infradiaphragmatic TAPVR
 - Leads to pulmonary congestion and death
- PE: cyanosis, respiratory distress, CXR white out with small heart
- Tx: no PGE, surgical repair

Transposition of the Great Arteries



- Great arteries are “switched”
- Systemic venous return goes back to the body
- Pulmonary venous return goes back to the lungs
- Survival dependent on mixing between the two parallel circulations

Transposition of the Great Arteries

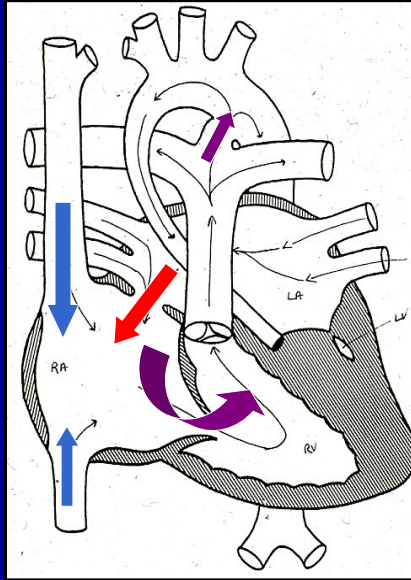
- Most common cyanotic CHD (0.22 per 1000 live births)
- Fetal circulation allows mixing
- Problems after birth
- Mixing via PFO/ASD, VSD (1/3), or PDA
- PE: severe cyanosis, no murmur
- Tx: balloon atrial septostomy to maximize mixing at the atrial level
 - surgical arterial switch

Cyanosis due Mixing with Heart Failure

- Obstruction to systemic outflow, mixing, cyanosis, poor perfusion
- Depend on PDA to supply systemic blood flow
- As PDA closes, see poor perfusion, acidosis, death

- Hypoplastic left heart syndrome (HLHS)
- Critical valvar Aortic Stenosis
- Interrupted aortic arch/Coarctation of the Aorta

HLHS



- Left side of the heart too small/absent
- Classic form is mitral and aortic atresia
- Pulmonary venous blood shunts left to right at PFO and mixes with systemic venous return
- Blood going out the RV into the PA passes through the PDA to feed the body

HLHS

- 0.16-0.27 per 1000 live births
- Severe form of single ventricle
- PE: no murmur, cyanosis, poor pulses
- Tx: PGE, Surgery: Norwood, Glenn, Fontan

Evaluation of the cyanotic newborn

- History: family hx, prenatal testing, peripartum information
- Vital Signs: HR, RR, O2 sat, 4 ext BP
- Physical exam: observation of skin, movement, respirations, palpation and auscultation of chest, palpation of femoral pulses, capillary perfusion
- Laboratory testing: ABG, CBC, BLCx, CXR, EKG, Echo

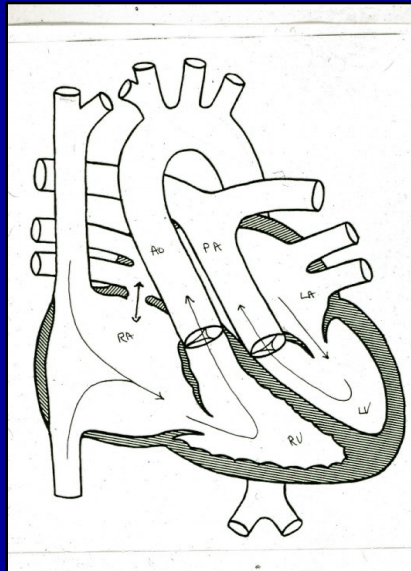
Hyperoxia Test: Heart vs Lungs?

- Cardiac lesions typically have fully saturated pulmonary venous blood
 - High FiO₂ has little effect on PO₂ and O₂ Sat
- Pulmonary lesions typically have pulmonary venous desaturation
 - Higher FiO₂ increases pulmonary venous oxygen levels and PO₂ and O₂ Sat
- Administer 100% FiO₂ for 10 minutes and compare the PO₂ at baseline and after oxygen
 - PO₂ > 150 mm Hg = pulmonary cause
 - PO₂ < 150 mm Hg = cardiac cause

Case presentation

- Called to the nursery to evaluate a 3.5 kg product of a NSVD born at 39 wk GA to a 35 yo G2P1
- APGARS 9 and 9
- At four hours of life RN noted the infant appeared “dusky”
- Central cyanosis, no tachypnea, no murmur
- O₂ Sat = 70%, PO₂ = 40 mm Hg on RA, and O₂ Sat = 82%, PO₂ = 50 mm Hg on 100% FiO₂
- CXR NL

Transposition of the Great Arteries

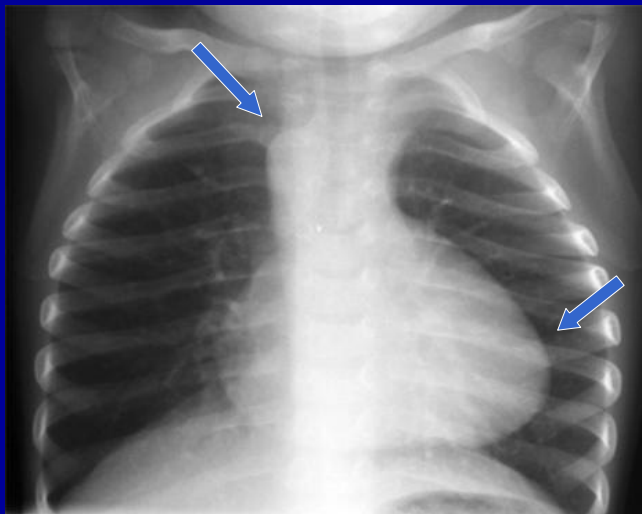


- Prostaglandin E1
- Emergent balloon atrial septostomy
- O₂ sat increases to 85%
- Arterial switch operation next day

Case presentation

- Called to the nursery to evaluate a 3.5 kg product of a NSVD born at 39 wk GA to a 35 yo G2P1
- APGARS 9 and 9
- Murmur heard on discharge exam
- No tachypnea, loud SEM at LUSB
- O2 Sat = 90%
- CXR?
- Echo?

Boot shaped heart = TOF

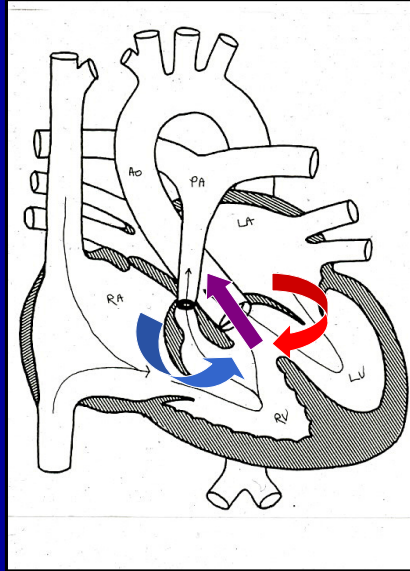


Upturned cardiac apex due to RVH

Right aortic arch

Lungs hyperinflated (black) due to decreased blood flow

Tetralogy of Fallot



Educate parents about tet spells

Genetic testing for DiGeorge

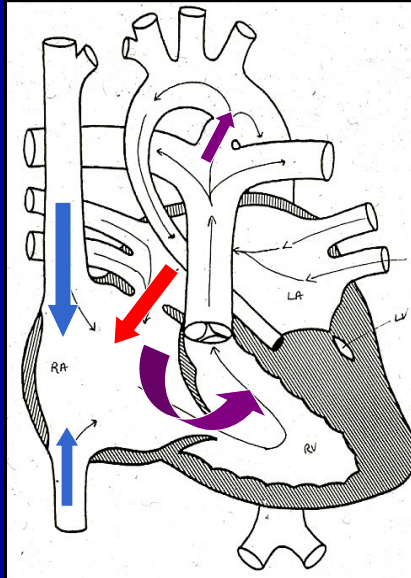
Frequent follow up to check O2 sat

Plan elective surgical repair at 4 - 6 months

Case presentation

- Get a call from an outside pediatrician
- 10 day old infant with grunting and poor perfusion – presumed sepsis
- APGARS 9 and 9, no prenatal US
- In ER: Grey infant, O2 Sat = 90%, no femoral pulses, no murmur
- Echo?

HLHS



- Prostaglandin E1
- Pressors
- Intubate FiO2 21%
- Sedate and hypoventilate
- Norwood Stage I when stable

Summary

- Cyanosis when 3-5 gm/dl of desaturated Hgb – hard to see if anemic
- Multiple causes
- Cardiac causes are EMERGENCIES
- Decreased pulmonary blood flow vs Mixing
- Prostaglandin E2 to keep ductus arteriosus OPEN