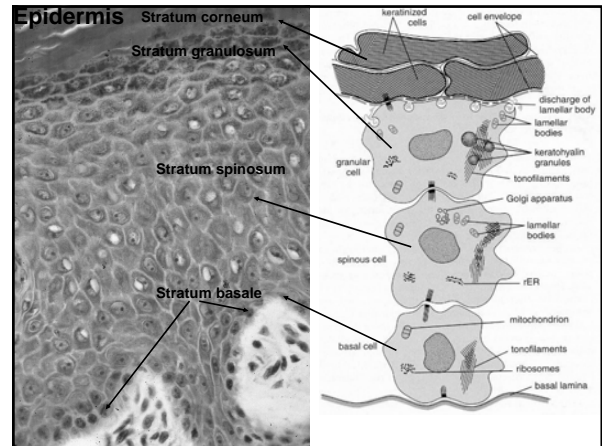


Tissue Repair: Regeneration and Fibrosis

Patrice Spitalnik, MD
Pfs2101@columbia.edu

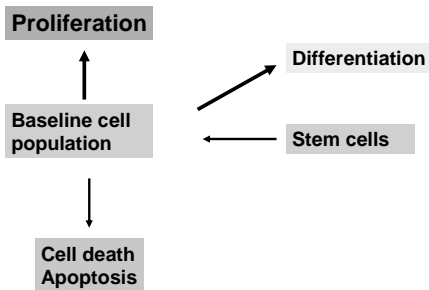


Lecture Outline

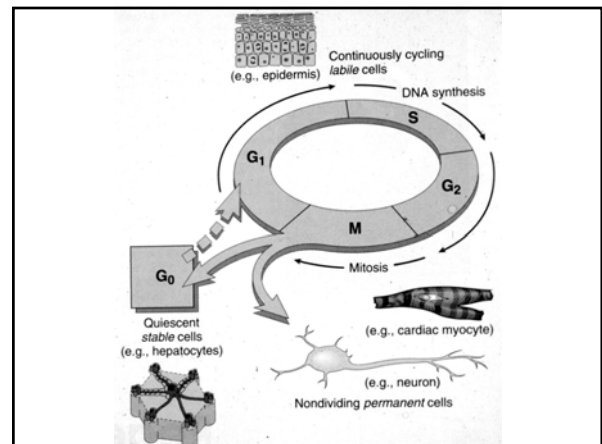
- Control of Cell Proliferation – cell cycle
- Growth Factors
- Extracellular matrix
- Cell and Tissue Regeneration
- Repair (scar)
- Cutaneous wound healing
- Pathologic repair

Tissue Types

- Continuously Dividing (labile)
 - Hematopoietic and surface epithelia
- Stable
 - Liver, kidney, pancreas, smooth muscle, endothelial cells, fibroblasts
- Permanent
 - Neurons and cardiac muscle



Tissue Steady State



Signaling of Growth Factor Receptors

- Autocrine – lymphocytes, liver
- Paracrine – macrophages in wound healing
- Endocrine - hormones

TGF- beta

- Produced by:
 - Platelets and macrophages
- **MOST IMPORTANT FACTOR IN WOUND HEALING**
- Actions:
 - Monocyte chemotaxis
 - Fibroblast migration and proliferation
 - Angiogenesis and fibronectin synthesis
 - Collagen and ECM:
 - Increased synthesis
 - Decreased degradation by MMP's, increased TIMP's

Growth Factors in Tissue Repair

- Vascular Endothelial growth factor (**VEGF**) – increased vascular permeability
- Transforming Growth Factor-Beta (**TGF-B**)
- Platelet Derived Growth Factor (**PDGF**)
- Epidermal Growth Factor (**EGF**)
- Fibroblast Growth Factor (**FGF**)

PDGF

- Produced by platelets, macrophages, endothelial cells
- Chemotactic for neutrophils, macrophages, fibroblasts, smooth muscle cells
- Stimulates production of MMP's, fibronectin and hyaluronic acid
- Stimulates angiogenesis

VEGF

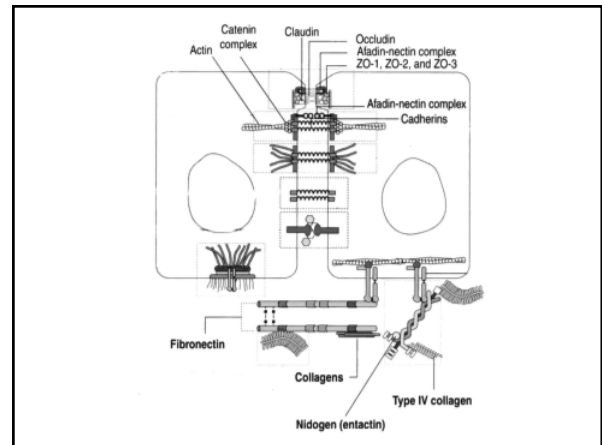
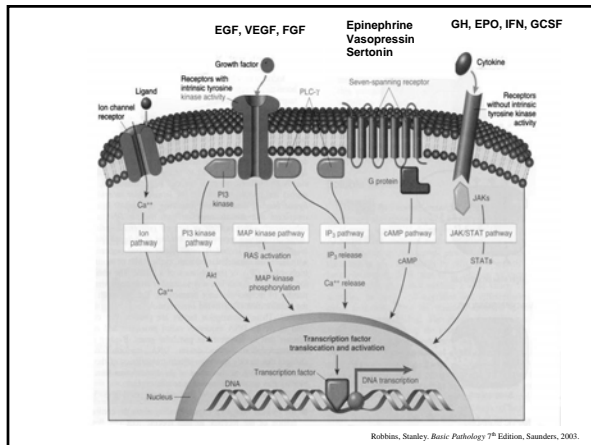
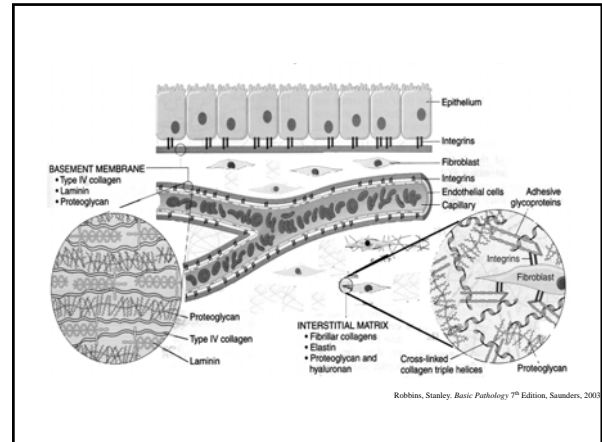
- Produced by mesenchymal cells
- Increases vascular permeability
- Mitogenic for endothelial cells

EGF

- Produced by activated macrophages
- Mitogenic for keratinocytes and fibroblasts
- Stimulates granulation tissue formation


FGF

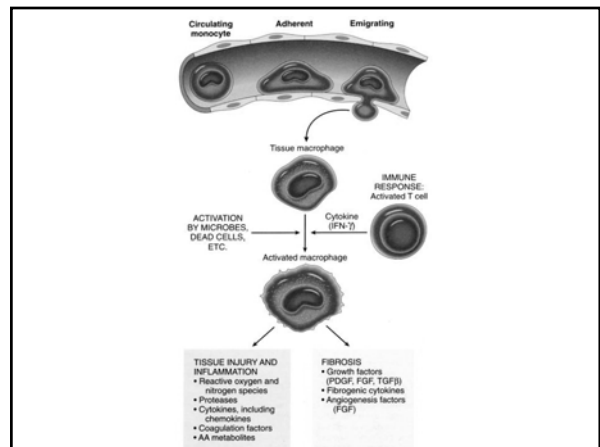
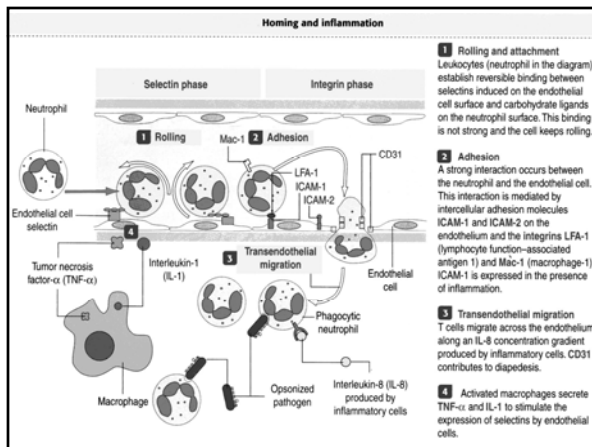
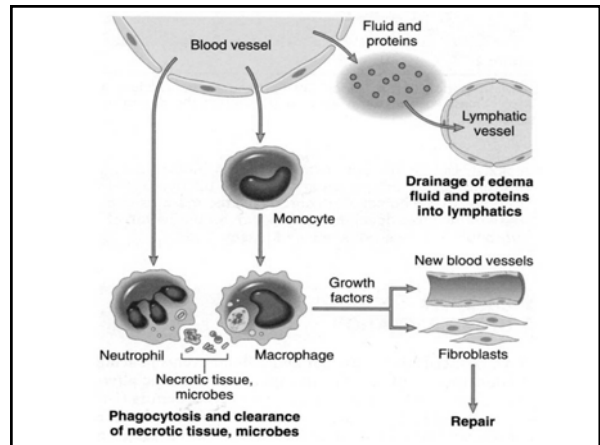
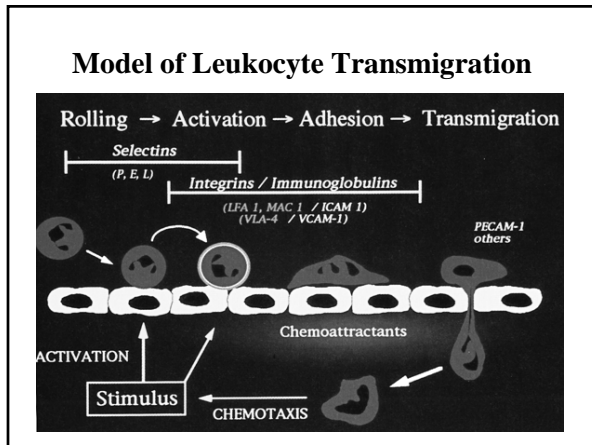
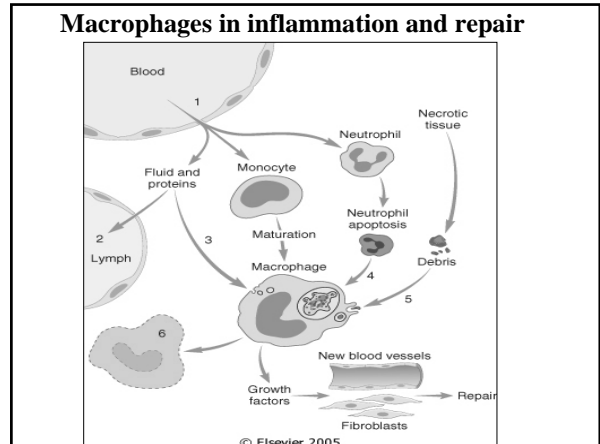
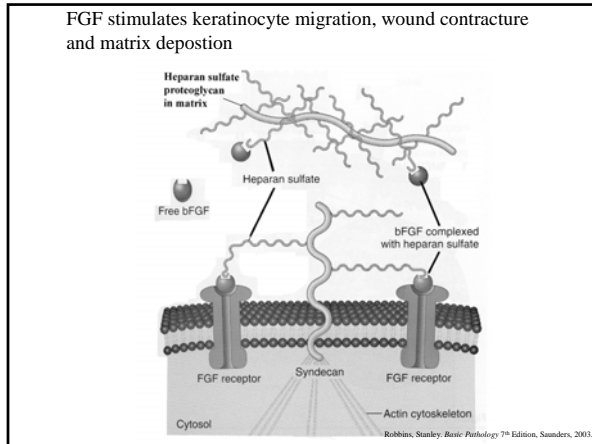
- Produced by macrophages, T cells
- Chemotactic for fibroblasts
- Mitogenic for fibroblasts and keratinocytes
- Stimulates keratinocyte migration, angiogenesis, wound contraction and matrix production

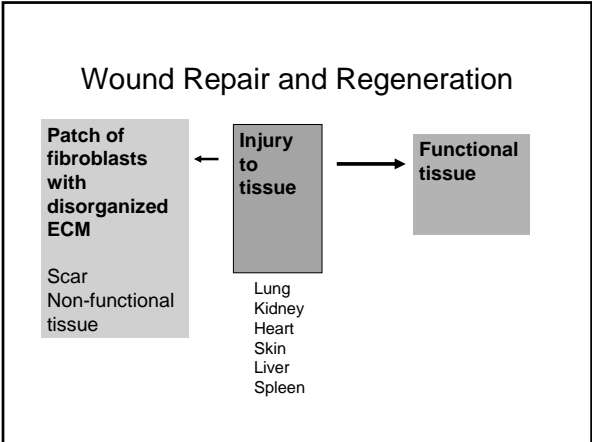


Role of ECM

- Mechanical Support – anchorage, cell migration, cell polarity
- Cell growth control
- Maintenance of cell differentiation -

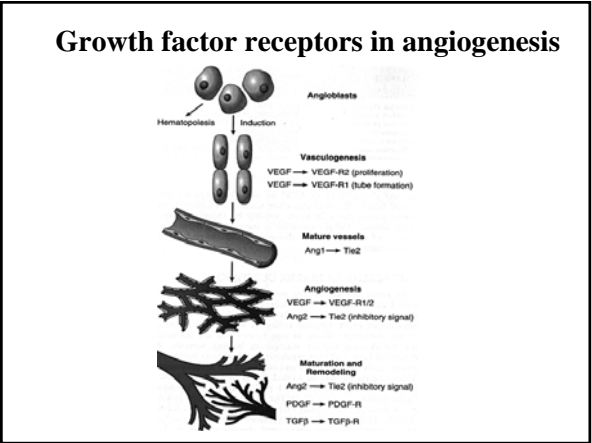




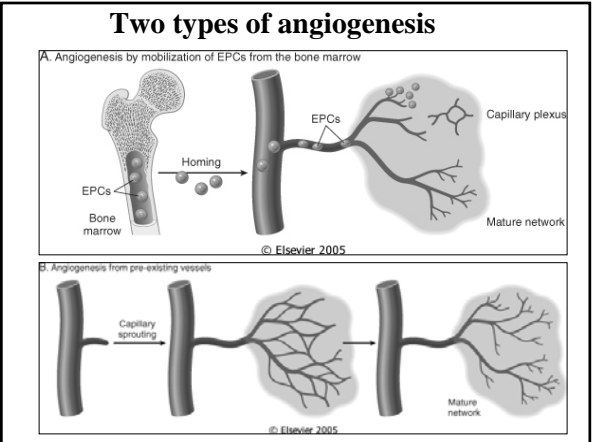


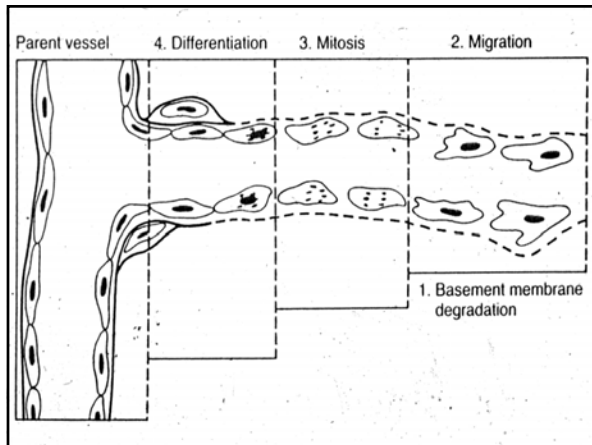
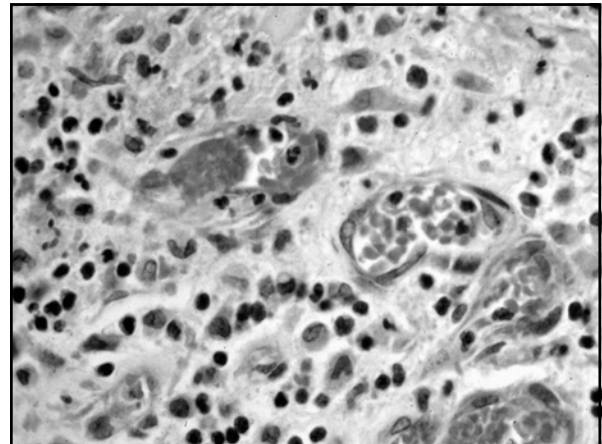
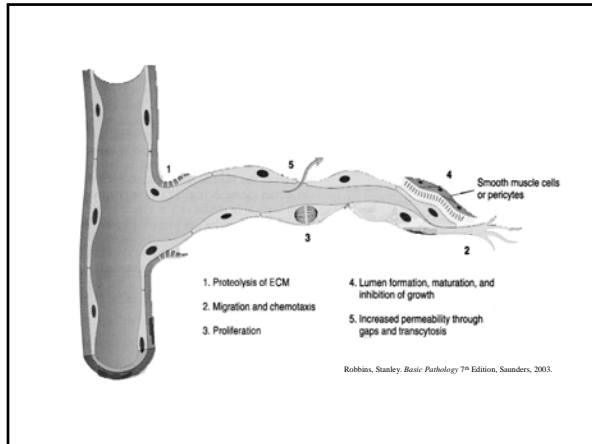
- ### Angiogenesis
- Proteolysis of vessel basement membrane
 - Endothelial cell migration and proliferation
 - Pericyte recruitment

- ### Key Points
- How does each tissue restore itself to prevent scar?
 - Humans lose the ability to prevent scar after fetal life
 - Scar prevents tissue regeneration
 - What is the purpose of the scar?



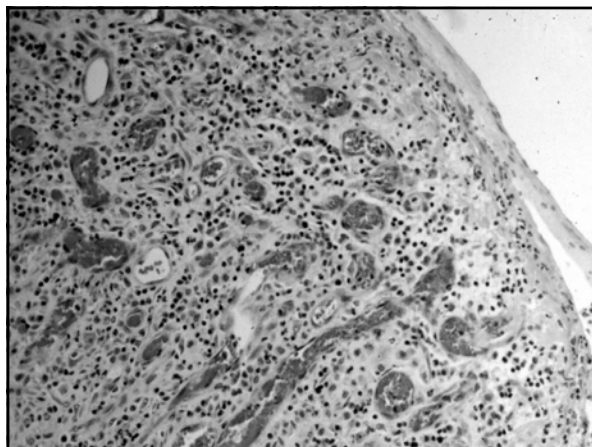
- ### Repair By Connective Tissue
- Formation of new blood vessels (angiogenesis)
 - Migration and proliferation of fibroblasts
 - Deposition of ECM (scar)
 - Maturation and reorganization of fibrous tissue (remodeling)





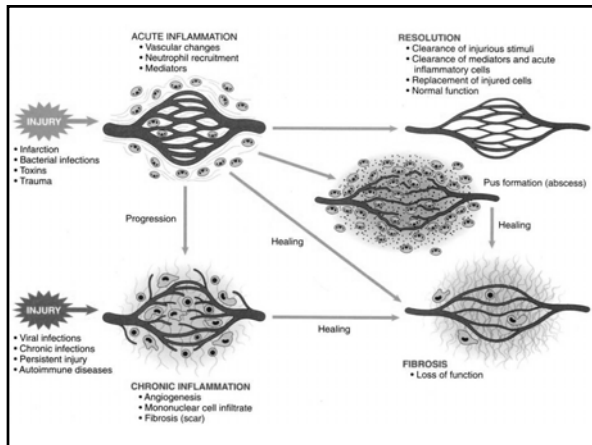
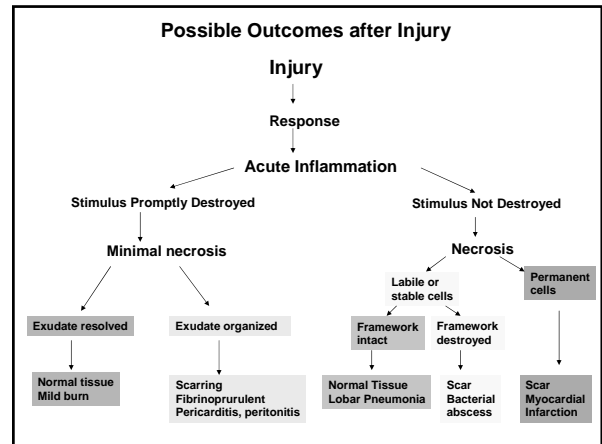
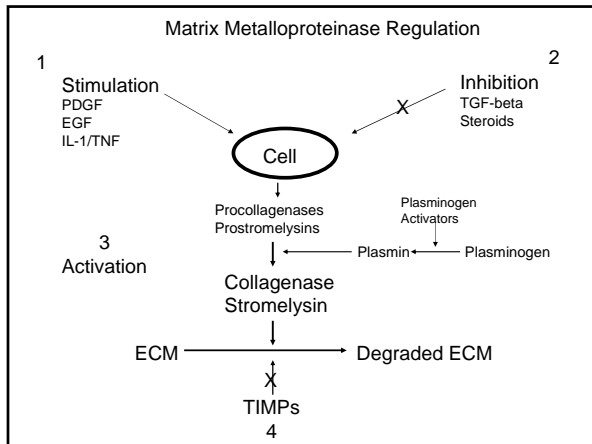
Scar Formation

- Fibroblast proliferation and migration
 - PDGF, FGF, TGF-beta mainly from macrophages
- ECM deposition
 - TGF-beta – potent agent of fibrosis



ECM and Tissue Remodeling

- Outcome of repair: **balance** between synthesis and degradation of matrix
- **MMP's** are synthesized by fibroblasts, macrophages, neutrophils, epithelial cells, etc destroy matrix (inactive form) activated by proteases and plasmin and inhibited by **TIMP's**-synthesized by mesenchymal cells

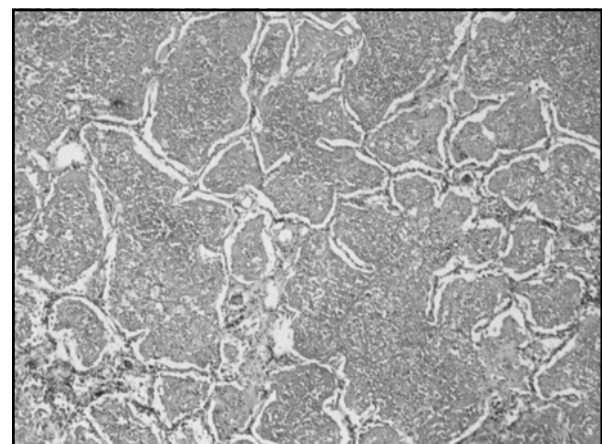


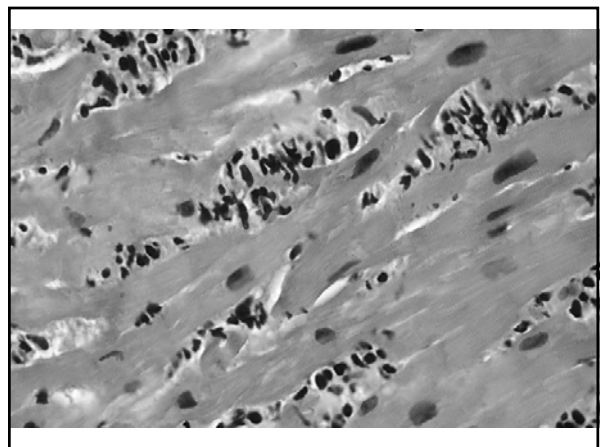
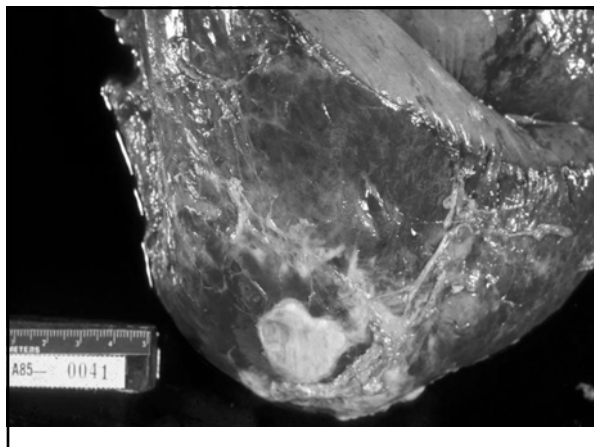
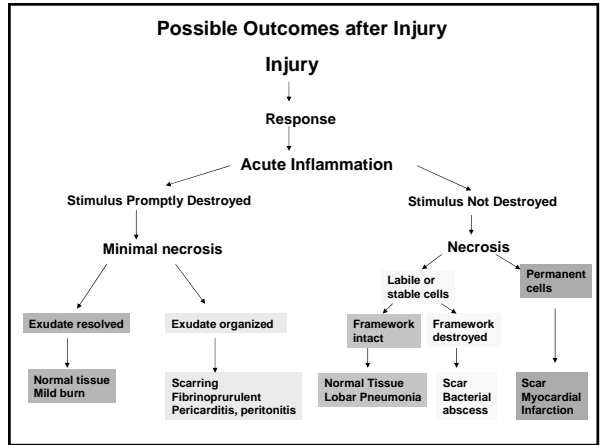
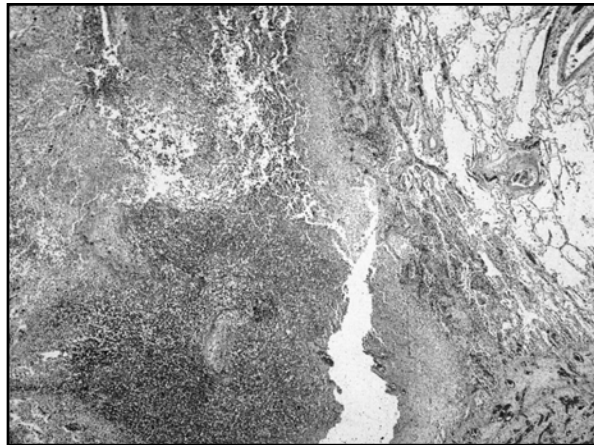
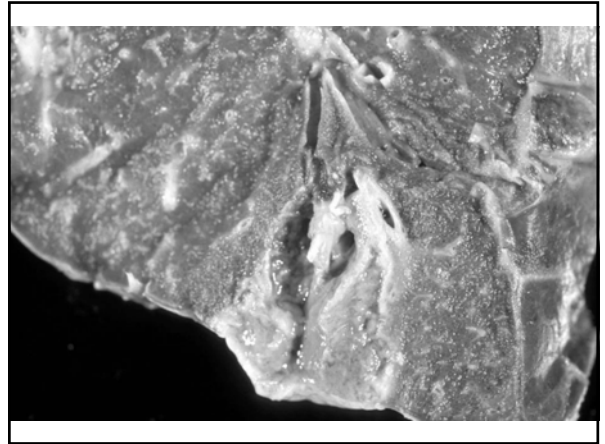
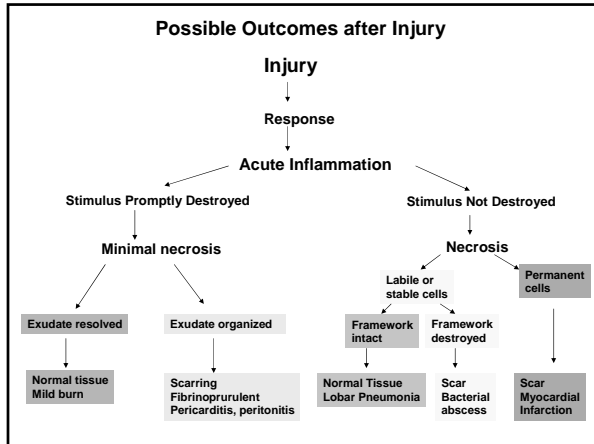
Regeneration

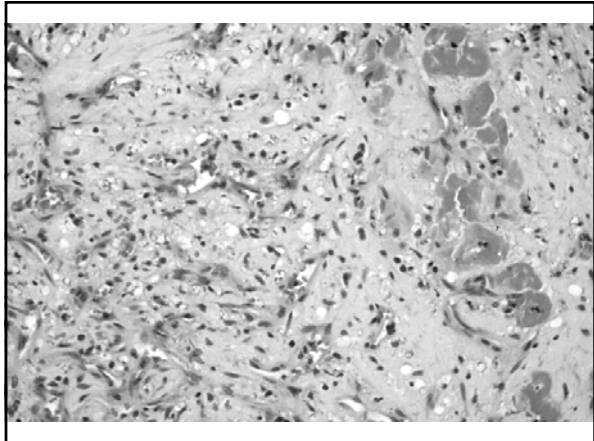
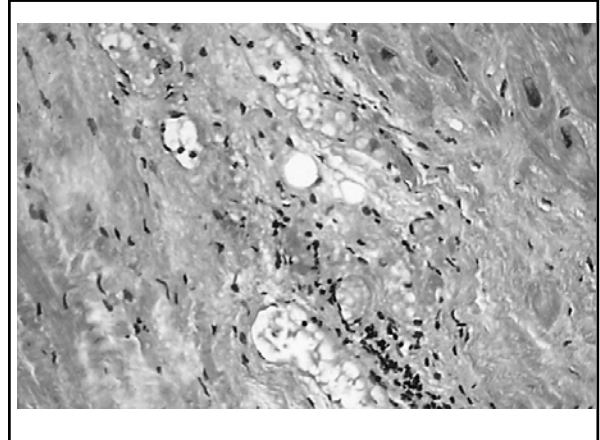
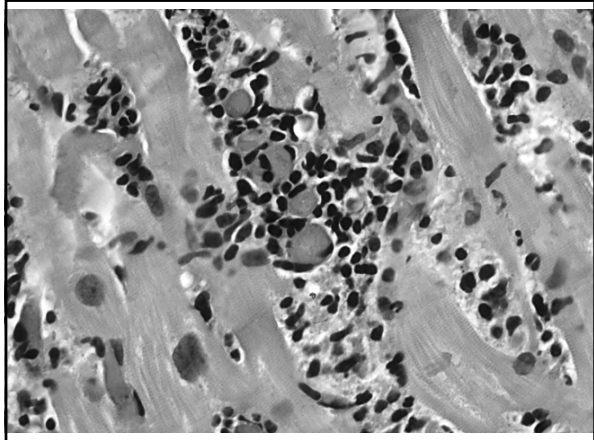
- If the connective tissue framework is intact
- If the cells are not post-mitotic
- THEN:
- Complete restoration of the structure and function of the tissue is possible

Classic Stages of Wound Repair

- Inflammation – until 48 hrs. after injury
- New tissue formation – 2-10 days after injury
- Remodeling – 1-12 months after repair

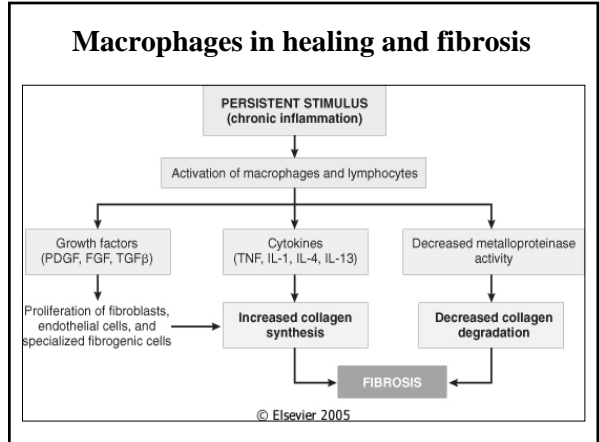
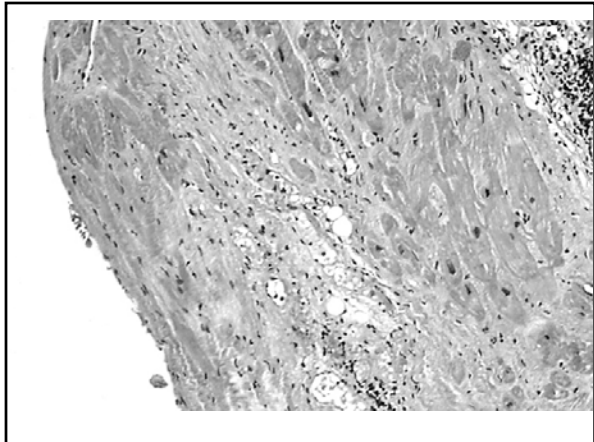






Repair by Fibrosis

- Angiogenesis
- Granulation tissue
- Migration and proliferation of fibroblasts
- Deposition of extracellular matrix
- Organization of collagen “remodeling”
- Fibrosis – scar formation


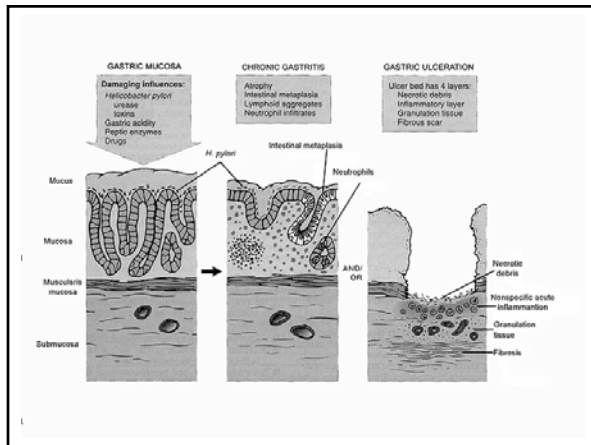


Chronic Peptic Ulcer

Fibrosis below the ulcer bed

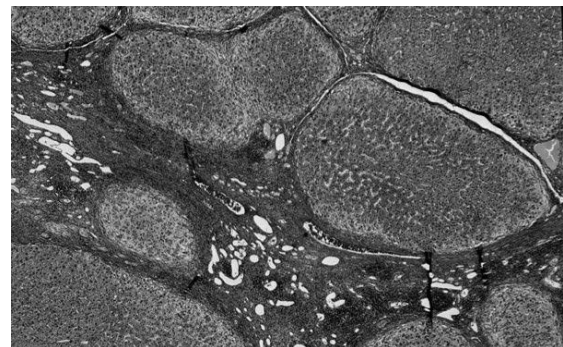
Scarring in the Liver

- Healing by fibrosis after inflammation
- TGF beta implicated in excessive collagen formation

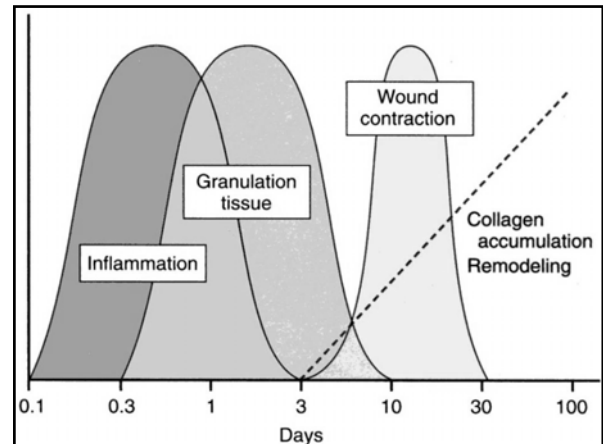
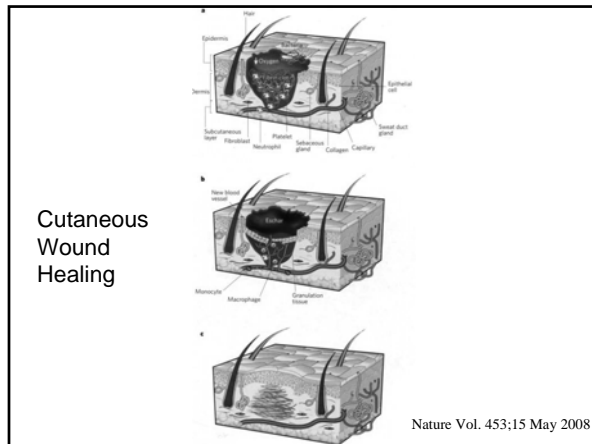


Fibrotic response to toxin-mediated injury

- Poorly understood:
 - Liver Hepatitis B,C
 - Pulmonary fibrosis



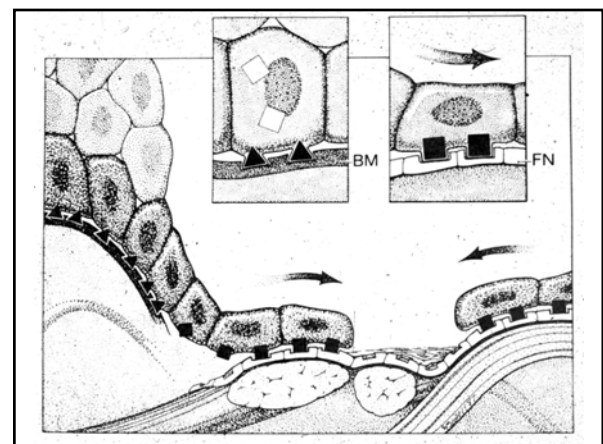
Cirrhosis

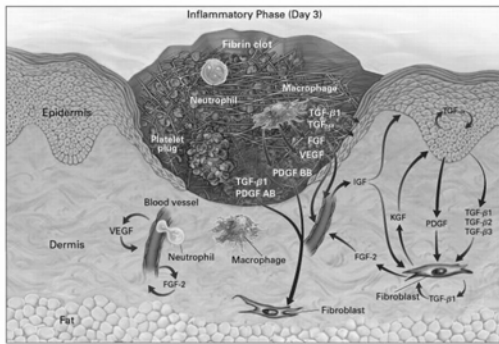


- ### Classic Stages of Wound Repair
- Inflammation – until 48 hrs. after injury
 - New tissue formation – 2-10 days after injury
 - Remodeling – 1-12 months after repair

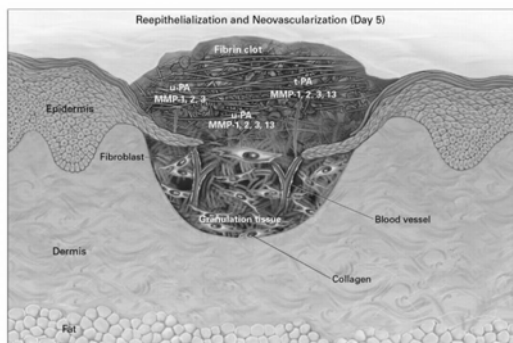
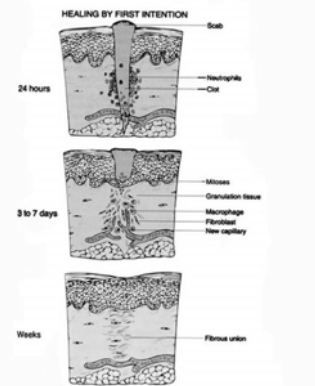
- ### Cell Migrations in Wound Healing
- **Platelets** form a blood clot and secrete fibronectin (FN), PDGF and TGF-beta
 - **Neutrophils** arrive within minutes
 - **Macrophages** move in as part of granulation tissue and secrete fibronectin
 - **Keratinocytes** or other epithelial cells detach from the basement membrane at wound edge and migrate on fibronectin rich matrix across wound to fill in defect (cells switch receptors from those for BM to FN receptors)

- ### Overview of Cutaneous Wound Healing
- A defect in the skin occurs
 - Fibrin fills in defect – scab forms
 - Epithelial regeneration beneath scab
 - Granulation tissue – angiogenesis
 - Wound contraction
 - Collagen remodeling





New England Journal of Med 341:738-746, 1999



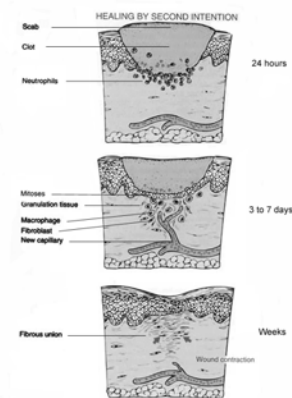
New England Journal of Med 341:738-746, 1999

Healing by Second Intention

- Large wound, may be infected
- Edges **not** brought close together
- Large amount of granulation tissue
- Scar formation and contracture

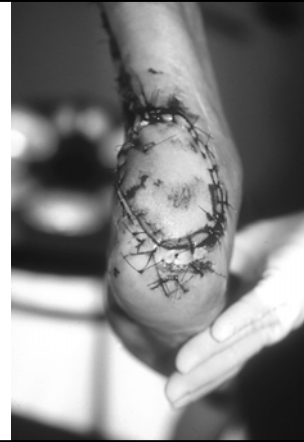Healing by Primary Intention

- Surgical incision
- Edges easily joined together
- Small amount of granulation tissue
- Little fibrosis
- Wound strength 70-80% of normal by 3 months



Inhibition of Repair

- Infection with inadequate nutrition (Vitamin C is essential for collagen)
- Glucocorticoids inhibit inflammation with decreased wound strength and less fibrosis.
- Poor perfusion due to diabetes or atherosclerosis.
- Foreign bodies left in the wound.
- Chronic inflammation leads to excess, disabling fibrosis as in rheumatoid arthritis, pulmonary fibrosis and cirrhosis.

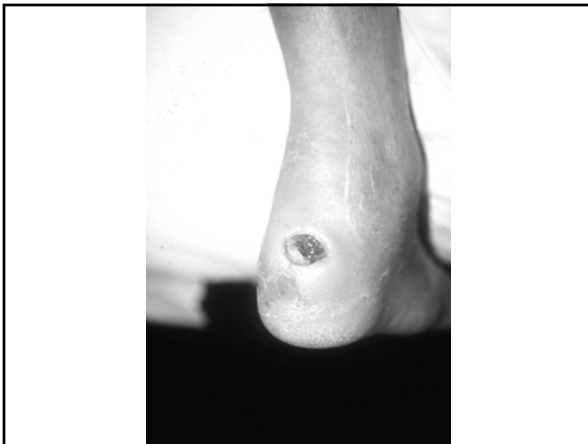

Diabetic Foot Ulcer Case #1

- A 52 year old woman has had fairly well controlled type 2 diabetes mellitus for the past 20 years.
- In the last three months, she has noticed a non-healing ulcer on her heel.
- She asks you what can be done to make it heal better.

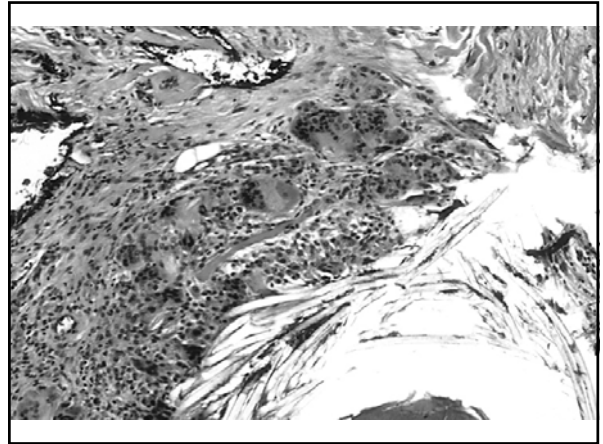
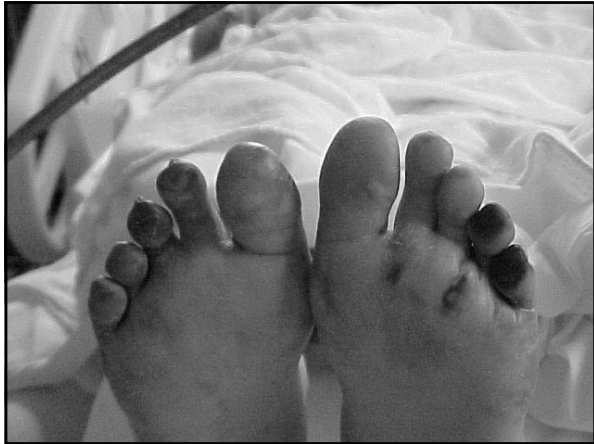Possible New Therapy

- Application of VEGF alone to wounds in an animal model of diabetes (wound repair is dysregulated in DM) can normalize healing



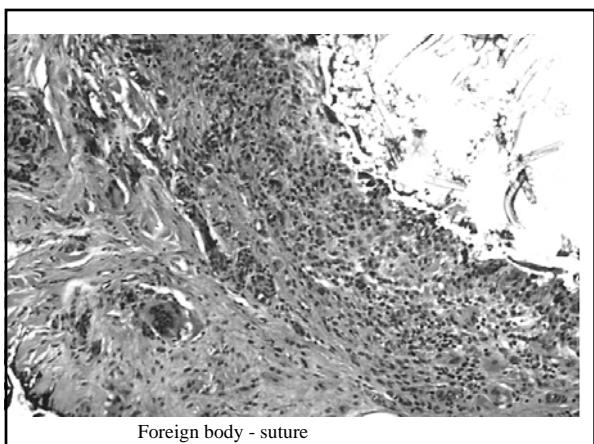
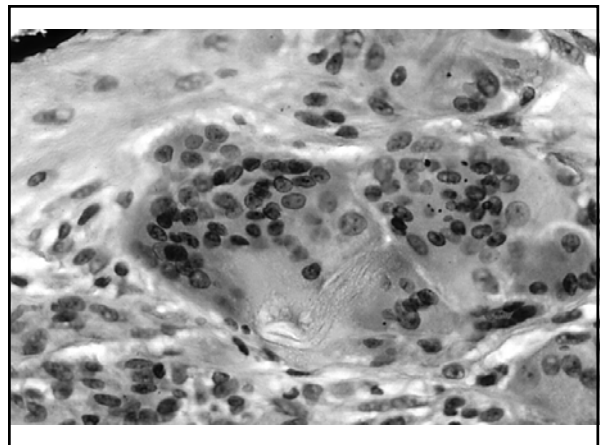
Diabetic Foot Ulcer Case #2

- A 63 year old male has had Type 2 diabetes mellitus for the past 10 years.
- He requires insulin.
- He presents to you with the complaint of a painless sore on the sole of his foot directly beneath a metatarsal head.
- He asks why his foot has difficulty healing.



Inhibition of Repair


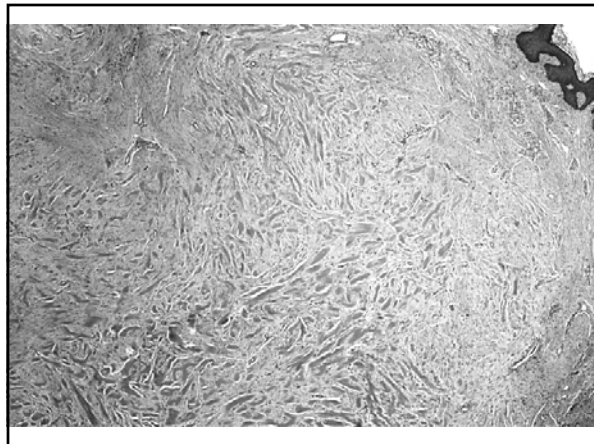
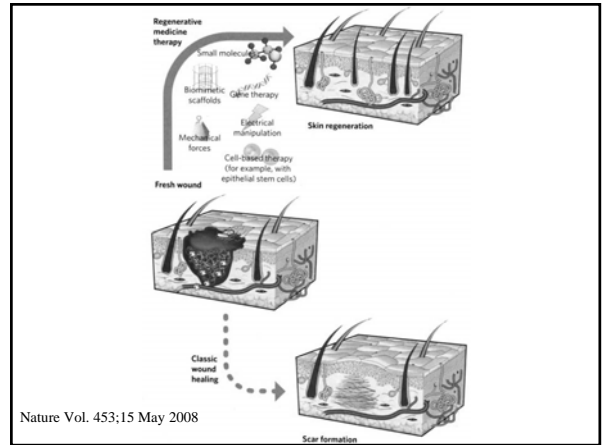
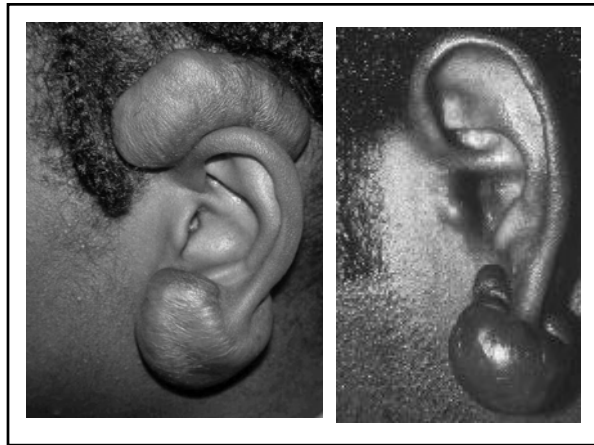
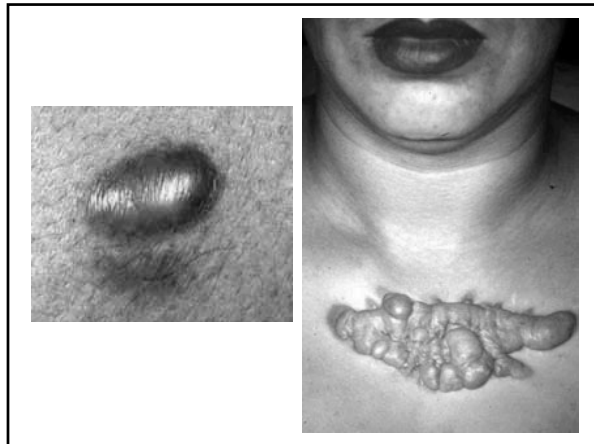
- Foreign body in wound

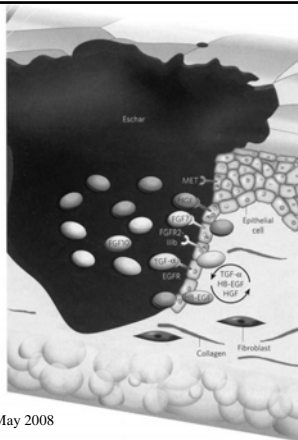


Foreign body - suture

Abnormal Repair Processes

- Inadequate scar formation - dehiscence, ulceration
- Excessive scar formation – keloids
- Contracture – exaggeration of normal process (soles, palms, thorax) especially with serious burns





Nature Vol. 453;15 May 2008